

**DATE PRESENTING CLINICAL SIGNS**

6/17/22 Referred for abdominal ultrasound. RDVM concern for mid abdominal mass; bloodwork- WNL.

PATIENT

Hazel Canoles

Date of Previous IntraPet Ultrasound: No previous.
 Sedation: Not required to complete full diagnostic ultrasound.
 Stat Report: Not requested.

SPECIES

Canine

ULTRASONOGRAPHIC EXAMINATION OF THE ABDOMEN**Urinary System**

The **urinary bladder**, trigone, and pelvic urethra presented normal thicknesses and normal tone. The ureters were not visible which is normal. No uroliths or sediment were visualized and anechoic urine was present. No evidence of inflammatory or neoplastic changes were noted. Ureteral papillae were normal.

BREED

Mix

SEX

Spayed Female

The **kidneys** revealed largely normal size and structure, corticomedullary definition and ratio (cortex 1/3 of medulla) were essentially maintained with some minor age-related loss of curvilinear patterns regarding the capsule and C/M junction. The cortices presented largely uniform texture with some increased echogenicity expected for his age patient. Medullary structure differed distinctly from that of the cortex and no evidence of pelvic dilation was present. The right kidney measured 4.34 cm. The left kidney measured 5.84 cm.

AGE

8/23/11

Adrenal Glands**WEIGHT**

49.4 Pounds

Both **adrenal glands** were visualized and recognized as having normal shape, size, position and echogenicity for this breed. The phrenic vasculature, glandular echogenicity and detail were unremarkable. Capsule, cortex, and medullary definition were normal for this age patient. The left adrenal gland measured 2.97 cm x 0.75 cm at the caudal pole and 0.63 cm at the cranial pole. The right adrenal gland measured 2.58 cm x 0.95 cm at the cranial pole and 0.68 cm at the caudal pole.

INTERPRETED BY

Eric Lindquist, DMV
 DABVP, Cert. IVUSS

Spleen

The **spleen** revealed an expansive parenchymal mass, measuring 7.2 cm, deriving from the mid cranial body. The mass was mildly vascular. The caudal pole of the spleen was unremarkable.

IMAGING PERFORMED BY

Rachel Brillhart RDMS

Liver

The **liver** images submitted revealed subjectively normal liver size, contour, and structure. Parenchymal echogenicity was naturally coarse and hypoechoic to the spleen. Vascular and biliary tracts were of normal volume with no evidence of congestion. The gallbladder presented acceptably thin walls with primarily anechoic content. The cystic and common bile ducts were normal. No pathological hepatic lymphadenopathy was evident. No overt structural evidence of inflammatory, infiltrative or regenerative pathology was evident. No evidence of metastatic disease.

HOSPITAL NAME

Animal Emergency
 Hospital

REFERRING VET

Dr. Kalwa

Gastrointestinal

Examination of the **gastrointestinal tract** revealed a stomach and intestine free of stasis, of normal wall thickness, acceptable curvilinear mural detail, and peristaltic activity. Small and large intestine demonstrated normal luminal chyme and stool consistency respectively. No obstructive or overt infiltrative disease was noted. No associated abnormal lymphatic activity was noted.

INVOICE

16170

Pancreas

The base and limbs of the **pancreas** were observed to be largely isoechoic to surrounding omental fat. Pancreatic duct and capsular contour were acceptably normal and parenchyma respected normal curvilinear patterns. No overt evidence of active inflammatory or neoplastic disease was noted.

Other

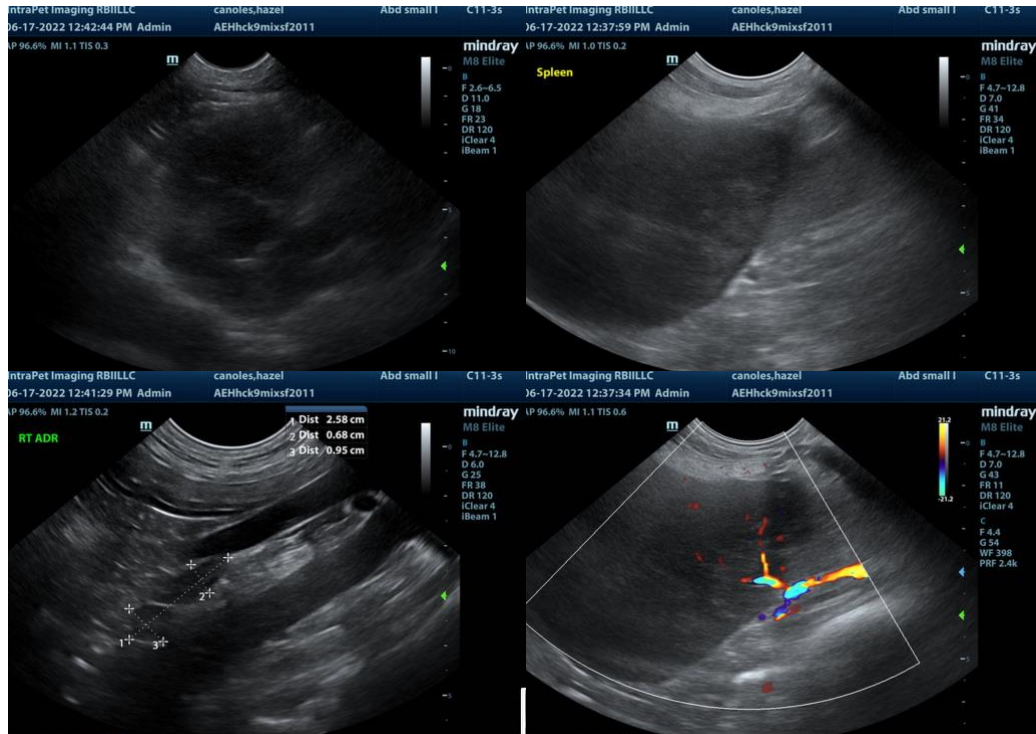
A rapid view of the **heart** revealed no evident pathology.

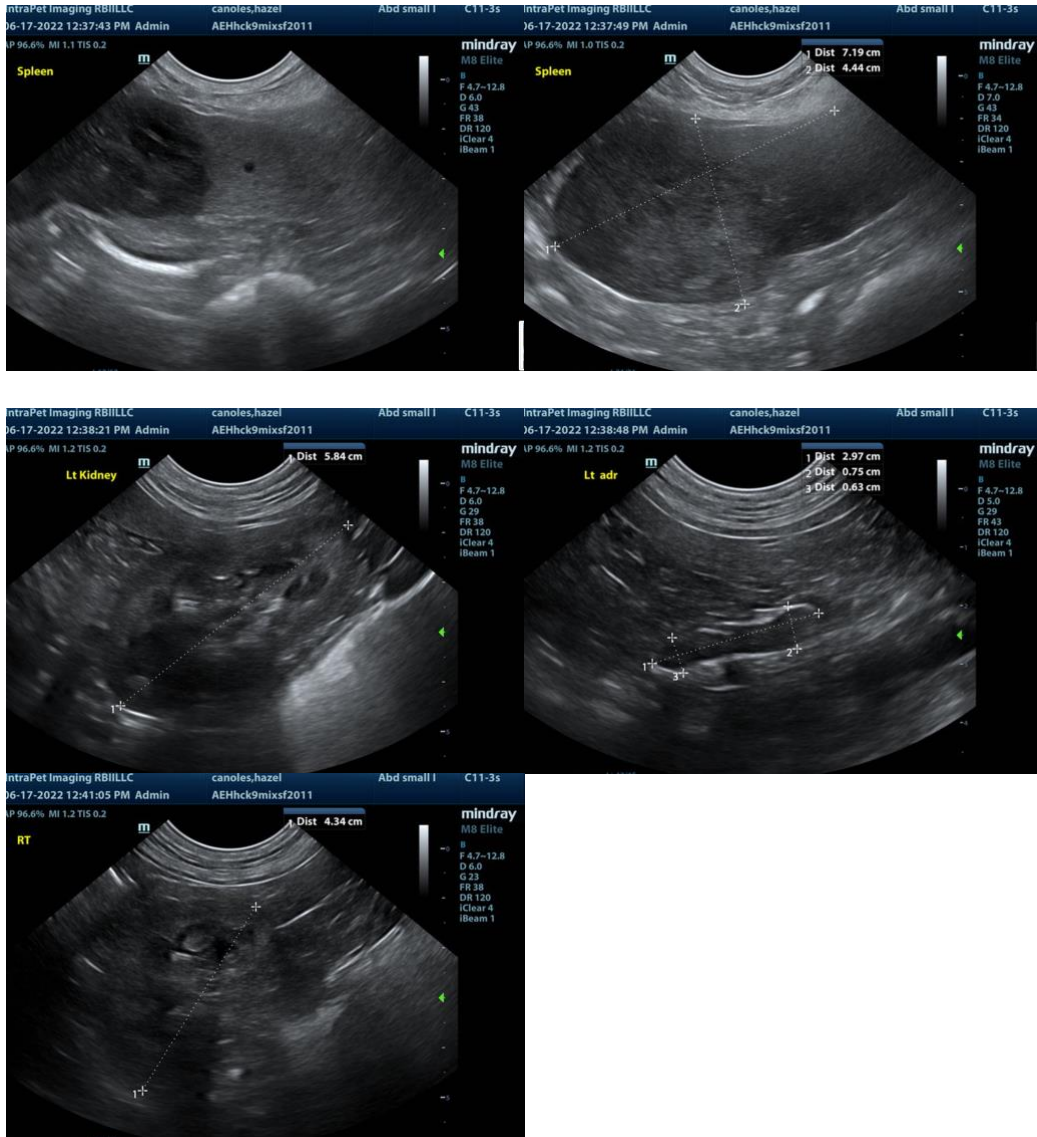
ULTRASONOGRAPHIC FINDINGS

- Splenic mass, nonneoplastic necrosis, round cell neoplasia or hemangiosarcoma are all possible. NO evidence of metastatic disease.

INTERPRETATION OF THE FINDINGS & FURTHER RECOMMENDATIONS

Immediate splenectomy, liver inspection and biopsy are recommended. No evidence of mass rupture. The mass is non-cavitated. Chest radiographs are warranted prior to surgery, if not already performed.





The information and recommendations provided are based on the images presented by the referring veterinarian/sonographer. No evaluation can be communicated regarding pathology that was not visible in the image/video clips provided.

Thank you for this referral. If the clinical or image interpretation does not parallel your findings or if I can be of any further assistance please contact me.

Eric Lindquist, DMV, DABVP, Cert. IVUSS, CEO of SonoPath.com
info@SonoPath.com