



PATIENT

Gidget Losee

PRESENTING CLINICAL SIGNS

Elevated ALKP/ALT, hypothyroid- controlled, no abnormal C/S

SPECIES

Canine

ULTRASONOGRAPHIC EXAMINATION OF THE ABDOMEN

Urinary System

The **urinary bladder**, trigone, and pelvic urethra presented normal thicknesses and normal tone. The ureters were not visible which is normal. No uroliths or sediment were visualized and anechoic urine was present. No evidence of inflammatory or neoplastic changes were noted. Ureteral papillae were normal.

BREED

Toy Terrier

SEX

Spayed Female

The **kidneys** revealed normal size and structure, corticomedullary definition and ratio for this age. The cortices presented largely uniform texture with normal echogenic relationship to liver and spleen. Medullary structure differed distinctly from the cortex and no evidence of pelvic dilation was present. The capsules were acceptably uniform without significant irregularities. The left kidney measured 3.5 cm. The right kidney measured 4.0 cm.

AGE

9 Years

Adrenal Glands

Both **adrenal glands** were visualized and recognized as having normal shape, size, position and echogenicity for this breed. The phrenic vasculature, glandular echogenicity and detail were unremarkable. Capsule, cortex, and medullary definition were normal for this age patient. The left adrenal gland measured 0.40 cm. The right adrenal gland measured 0.40 cm.

WEIGHT

11 Pounds

Spleen

The **spleen** presented a smooth homogeneous parenchyma hyperechoic to liver and renal cortical parenchyma. The capsule was smooth without noticeable expansion or deviation from within the spleen or adjacent pathology. The splenic vasculature demonstrated normal volume without signs of congestion or thrombosis. No sonographic evidence of acute or chronic inflammatory, neoplastic, or infarctual changes were noted.

INTERPRETED BY

Eric Lindquist, DMV

DABVP, Cert. IVUSS

Liver

The **liver** presented uniform minor enlargement. The gallbladder was slightly overdistended. Gallbladder calculus noted, non-obstructive, measuring 5.0 mm. Minor gallbladder debris and striating bile present in the gallbladder

IMAGING PERFORMED BY

Samantha Hudgins

HOSPITAL NAME

Petvacx AH

Gastrointestinal

A minor amount of non-shadowing, non-obstructive ingesta was noted in the **stomach**. Transit of chyme into the small intestine was normal. Curvilinear patterns were maintained throughout the GI tract. No evidence of pathology. Small and large intestine demonstrated normal luminal chyme and stool consistency respectively. No obstructive or overt infiltrative disease was noted. No associated abnormal lymphatic activity was noted.

REFERRING VET

Dr. Rachel Wiley

Pancreas

The base and limbs of the **pancreas** were observed to be largely isoechoic to surrounding omental fat. Pancreatic duct and capsular contour were acceptably normal and parenchyma respected normal curvilinear patterns. No overt evidence of active inflammatory or neoplastic disease was noted.

INVOICE

38849

DATE

6/17/22

PRIMARY FINDINGS

- Benign hepatopathy with emerging gallbladder mucocele



PATIENT

Gidget Losee

SECONDARY FINDINGS

- Gastric ingesta

SPECIES

Canine

INTERPRETATION OF THE FINDINGS & FURTHER RECOMMENDATIONS

FNA of the liver would be appropriate and Ursodiol therapy over the next 6-8 weeks, then recheck sonogram at that time.

BREED

Toy Terrier

SEX

Spayed Female

AGE

9 Years

WEIGHT

11 Pounds

INTERPRETED BY

Eric Lindquist, DMV
DABVP, Cert. IVUSS

IMAGING PERFORMED BY

Samantha Hudgins

HOSPITAL NAME

Petvacx AH

REFERRING VET

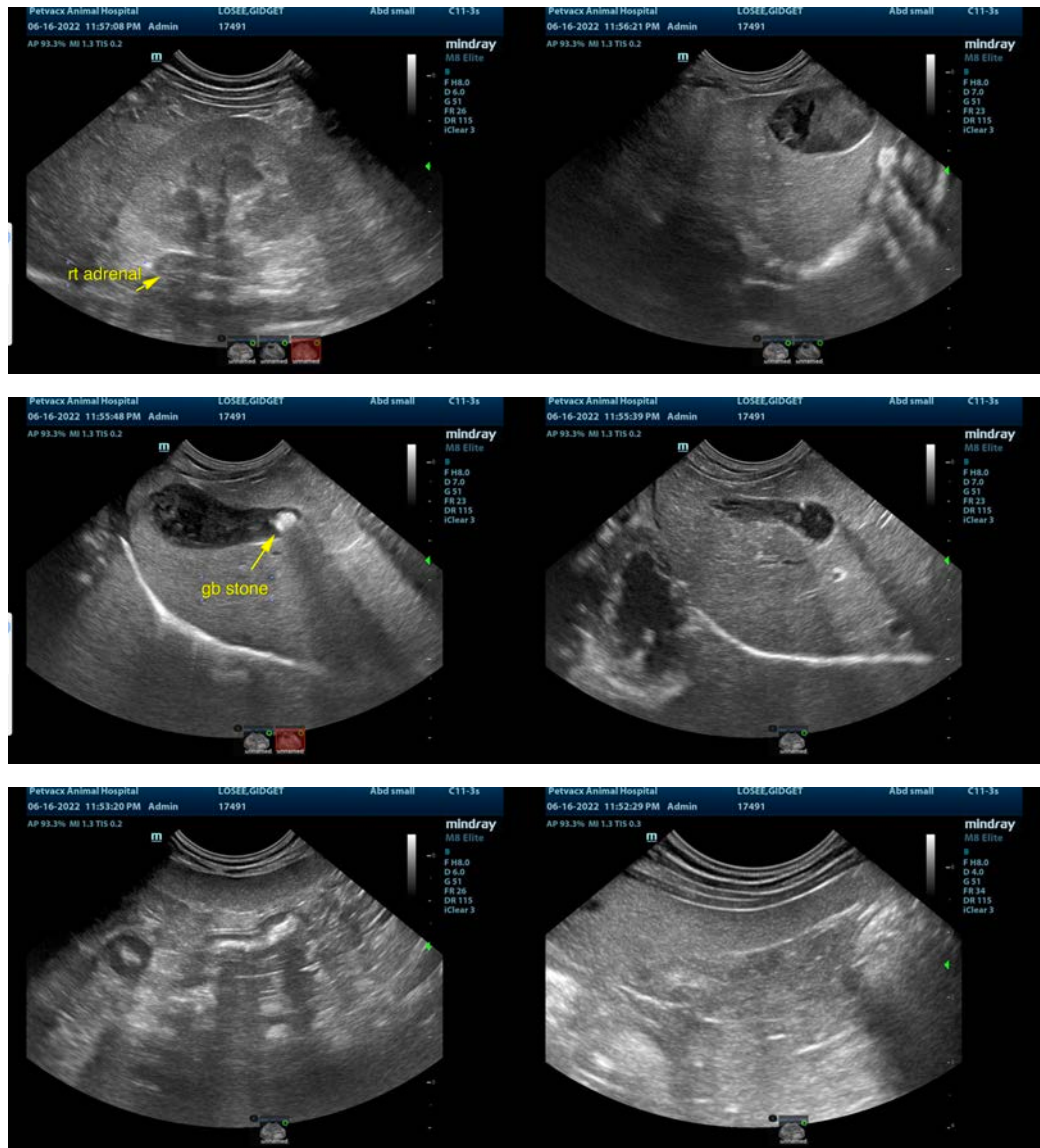
Dr. Rachel Wiley

INVOICE

38849

DATE

6/17/22





PATIENT

Gidget Losee

SPECIES

Canine

BREED

Toy Terrier

SEX

Spayed Female

AGE

9 Years

WEIGHT

11 Pounds

INTERPRETED BY

Eric Lindquist, DMV
DABVP, Cert. IVUSS

IMAGING PERFORMED BY

Samantha Hudgins

HOSPITAL NAME

Petvacx AH

REFERRING VET

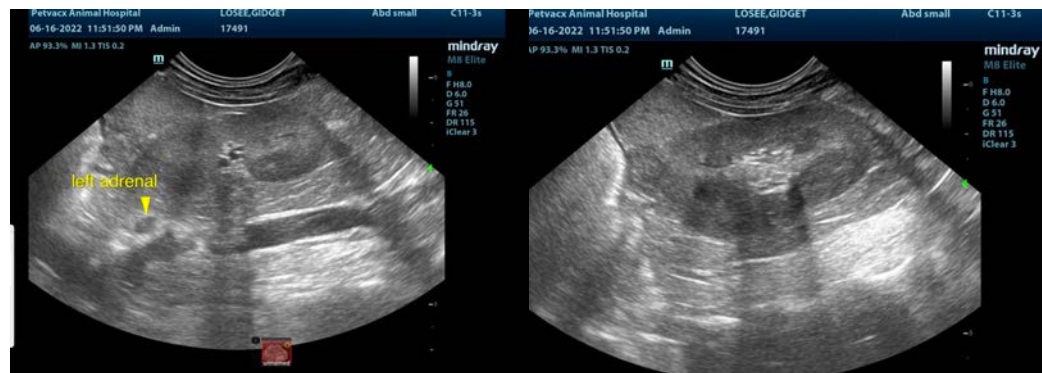Dr. Rachel Wiley

INVOICE

38849

DATE

6/17/22



The information and recommendations provided are based on the images presented by the referring veterinarian/sonographer. No evaluation can be communicated regarding pathology that was not visible in the image/video clips provided.

Thank you for this referral. If the clinical or image interpretation does not parallel your findings or if I can be of any further assistance please contact me.

Eric Lindquist, DMV, DABVP, Cert. IVUSS, CEO of SonoPath.com

info@SonoPath.com