



**DATE PRESENTING CLINICAL SIGNS**

6/17/22 Chronic UTI's.

**PATIENT**

Bailey Hoofnagle

Current Medications: Gabapentin 100mg-Give 1 capsule by mouth the night before her vet visit, and 1 capsule by mouth 2 hours before car ride.  
Date of Previous IntraPet Ultrasound: No previous.  
Sedation: Not required to complete full diagnostic ultrasound.  
Stat Report: Not requested.

**SPECIES**

Canine

**LIMITED ULTRASONOGRAPHIC EXAMINATION**

**BREED**

*Urinary System*

Jack Russell Terrier

The **urinary bladder**, trigone, and pelvic urethra presented normal thicknesses and normal tone. The ureters were not visible which is normal. No uroliths or sediment were visualized and anechoic urine was present. No evidence of inflammatory or neoplastic changes were noted. Ureteral papillae were normal.

**SEX**

Spayed Female

The **kidneys** revealed normal size and structure, corticomedullary definition and ratio for this age. The cortices presented largely uniform texture with normal echogenic relationship to liver and spleen. Medullary structure differed distinctly from the cortex and no evidence of pelvic dilation was present. The capsules were acceptably uniform without significant irregularities. Slight pinpoint mineralizations were noted. The left kidney measured 5.08 cm. The right kidney measured 5.64 cm.

**AGE**

9/3/13

**WEIGHT**

26 Pounds

**ULTRASONOGRAPHIC FINDINGS**

- Normal urinary tract with slight pinpoint renal mineralizations

**INTERPRETED BY**

Eric Lindquist, DMV  
DABVP, Cert. IVUS

**INTERPRETATION OF THE FINDINGS & FURTHER RECOMMENDATIONS**

No evidence of pathology. Given that the reported urinalysis was unremarkable, no specific therapy indicated.

**IMAGING PERFORMED BY**

Rachel Brillhart RDMS

**HOSPITAL NAME**

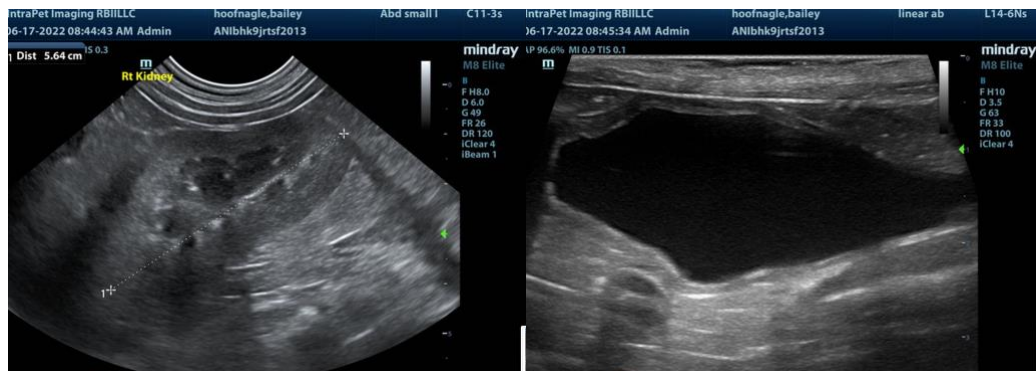Animal Medical Center

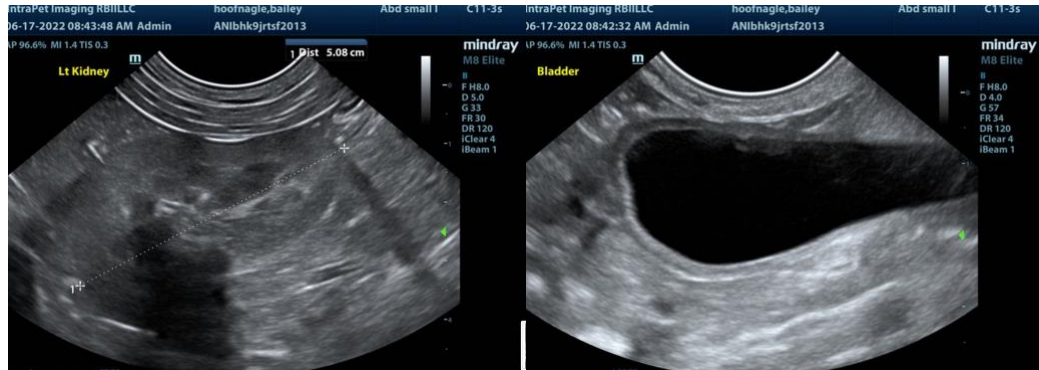
**REFERRING VET**

Dr. Chaudhry

**INVOICE**

16171





**The information and recommendations provided are based on the images presented by the referring veterinarian/sonographer. No evaluation can be communicated regarding pathology that was not visible in the image/video clips provided.**

Thank you for this referral. If the clinical or image interpretation does not parallel your findings or if I can be of any further assistance please contact me.

**Eric Lindquist**, DMV, DABVP, Cert. IVUSS, CEO of SonoPath.com  
[info@SonoPath.com](mailto:info@SonoPath.com)