



## PATIENT PRESENTING CLINICAL SIGNS

Atticus Morelock

Pt presents for difficulty swallowing/mass on neck. Pt is still eating currently. 5cm firm round subcu mass ventral neck- feels as if it would be encapsulated, slightly irregular texture on some aspects otherwise very smooth.

## SPECIES

Feline

## LIMITED ULTRASONOGRAPHIC EXAMINATION

## BREED

DSH

The right thyroid lobe was uniform at 0.50 cm x 0.80 cm. No evidence of pathology. Carotid artery, subcutaneous and muscular tissues all normal. Salivary glands normal. Trachea and esophagus normal.

## SEX

Neutered Male

The region of the left thyroid lobe revealed a large cystic structure. Normal thyroid was not evident. The entire structure measured approximately 3.0 cm and was non-vascular. Minor irregular proliferative tissue noted. However, the pathology appeared encapsulated. Tissue thickening was approximately 1.0 cm x 0.50 cm. Regional lymph nodes were unremarkable, maximum width of 4.0 mm. Length to width ratio maintained.

## AGE

15 Years

## ULTRASONOGRAPHIC FINDINGS

- Large left thyroid cyst with irregular tissue thickening – hyperplasia, adenitis, abscessation all possible, benign cystic changes most likely.

## WEIGHT

16.3 Pounds

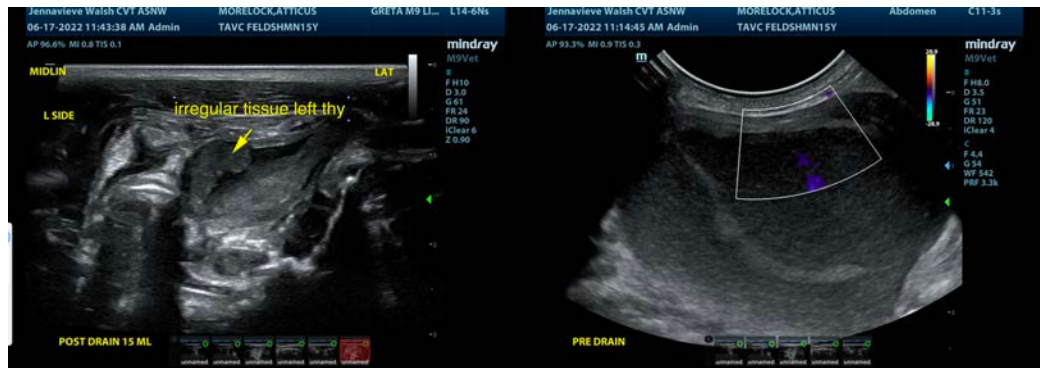
## INTERPRETATION OF THE FINDINGS & FURTHER RECOMMENDATIONS

Appears resectable if necessary. Surgical consultation recommended. No evidence of regional tissue involvement. Ultrasound guided drainage performed without complication.

## INTERPRETED BY

Eric Lindquist, DMV

DABVP, Cert. IVUSS



## IMAGING PERFORMED BY

Jenna Walsh, CVT

## HOSPITAL NAME

The Ark Vet Clinic

## REFERRING VET

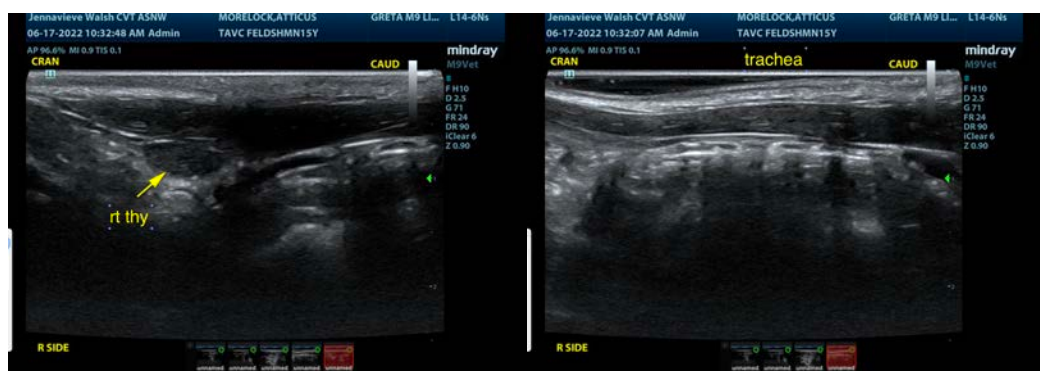
Dr. Mercer

## INVOICE

38842

## DATE

6/17/22





**PATIENT**

Atticus Morelock

**SPECIES**

Feline

**BREED**

DSH

**SEX**

Neutered Male

**AGE**

15 Years

**WEIGHT**

16.3 Pounds

**INTERPRETED BY**

Eric Lindquist, DMV  
DABVP, Cert. IVUSS

**IMAGING PERFORMED BY**

Jenna Walsh, CVT

**HOSPITAL NAME**

The Ark Vet Clinic

**REFERRING VET**

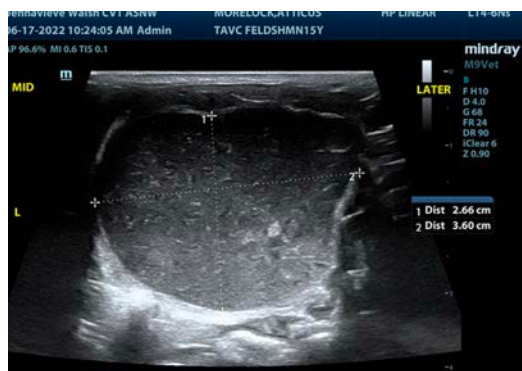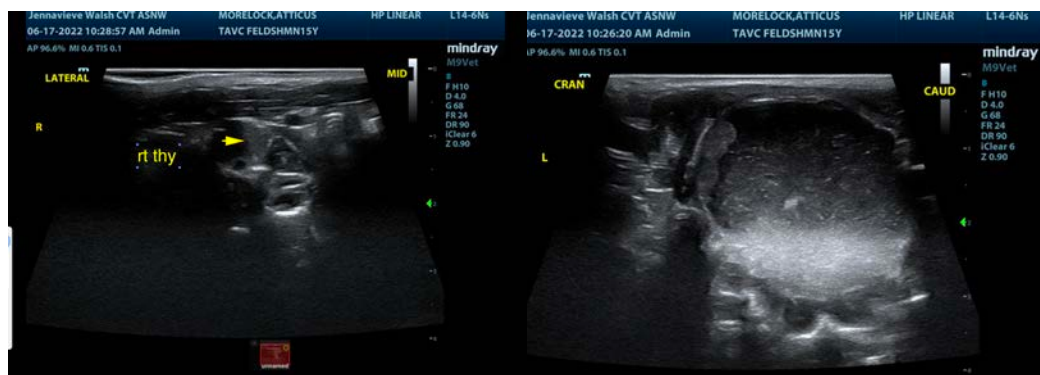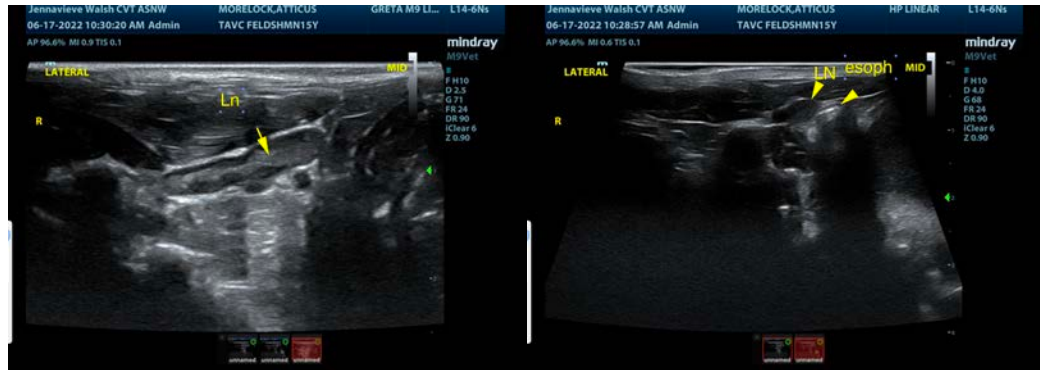Dr. Mercer

**INVOICE**

38842

**DATE**

6/17/22



The information and recommendations provided are based on the images presented by the referring veterinarian/sonographer. No evaluation can be communicated regarding pathology that was not visible in the image/video clips provided.

Thank you for this referral. If the clinical or image interpretation does not parallel your findings or if I can be of any further assistance please contact me.

**Eric Lindquist, DMV, DABVP, Cert. IVUSS, CEO of SonoPath.com**

[info@SonoPath.com](mailto:info@SonoPath.com)