



**PATIENT**

Tigger Kempf/Oswalt

**SPECIES**

Feline

**BREED**

DSH

**SEX**

Neutered Male

**AGE**

13 Years

**WEIGHT**

5.44 kg

**INTERPRETED BY**

Eric Lindquist, DMV  
DABVP, Cert. IVUSS

**IMAGING PERFORMED BY**

Dr. Schwanebeck

**HOSPITAL NAME**

Animal Emergency  
Hospital Deland

**REFERRING VET**

Dr. Schwanebeck

**INVOICE**

22942

**DATE**

6/16/23

**PRESENTING CLINICAL SIGNS**

History: Presented to clinic for anorexia and lethargy past 2 days. Patient vomited once yesterday, unsure if patient has urinated in past 2 days. Indoor/outdoor but predominantly indoors.

Abnormal PE/Chem/CBC/UA Results: Chem: Hyperglycemia (316), increased ALP (152) CBC: No significant findings EPOC: Minimal hyponatremia (146) and hypocalcemia (1.16), hyperlactatemia (7.42), hyperglycemia (330) FPLi: Normal FELV/FIV: Normal UA: One clump of transitional cells, rods/cocci, RBC, WBC

**ULTRASONOGRAPHIC EXAMINATION OF THE ABDOMEN**

**Urinary System**

The **urinary bladder**, trigone, and pelvic urethra presented normal thicknesses and normal tone. The ureters were not visible which is normal. No uroliths or sediment were visualized and anechoic urine was present. No evidence of inflammatory or neoplastic changes were noted. Ureteral papillae were normal.

The **kidneys** revealed largely normal size and structure, corticomedullary definition and ratio (cortex 1/3 of medulla) were essentially maintained with some mild age-related loss of curvilinear patterns regarding the capsule and C/M junction. The cortices presented largely uniform texture with some increased echogenicity expected for his age patient. Medullary structure differed distinctly from that of the cortex and no evidence of pelvic dilation was present. The left kidney measured 4.2 cm. The right kidney measured 4.5 cm.

**Adrenal Glands**

The regions of the **adrenal glands** revealed no evident pathology.

**Spleen**

The **spleen** presented a smooth homogeneous parenchyma hyperechoic to liver and renal cortical parenchyma. The capsule was smooth without noticeable expansion or deviation from within the spleen or adjacent pathology. The splenic vasculature demonstrated normal volume without signs of congestion or thrombosis. No sonographic evidence of acute or chronic inflammatory, neoplastic, or infarctual changes were noted.

**Liver**

The **liver** images from right and left intercostal as well as subcostal views revealed subjectively normal liver size, contour, and structure. Some mild age-related parenchymal remodeling was noted but likely not clinically significant at this time. Vascular and biliary tracts were of normal volume and no evidence of congestion was noted. The gallbladder presented some dependent debris with essentially normal contour. The cystic and common bile ducts were normal. No overt evidence of active inflammatory, infiltrative or regenerative pathology was noted but should be paired with current or past LE elevations regarding any clinical significance to this presentation. The hepatic lymph nodes were unremarkable.

**Gastrointestinal**

The **stomach** and colon were unremarkable. \*See Free Abdomen section.



**PATIENT**

Tigger Kempf/Oswalt

**SPECIES**

Feline

**BREED**

DSH

**SEX**

Neutered Male

**AGE**

13 Years

**WEIGHT**

5.44 kg

**INTERPRETED BY**

Eric Lindquist, DMV  
DABVP, Cert. IVUSS

**IMAGING PERFORMED BY**

Dr. Schwanebeck

**HOSPITAL NAME**

Animal Emergency  
Hospital Deland

**REFERRING VET**

Dr. Schwanebeck

**INVOICE**

22942

**DATE**

6/16/23

**Pancreas**

The base and limbs of the **pancreas** were observed to be largely isoechoic to surrounding omental fat. Pancreatic duct and capsular contour were acceptably normal and parenchyma respected normal curvilinear patterns. No overt evidence of active inflammatory or neoplastic disease was noted.

**Free Abdomen**

The **mesenteric lymph nodes** (up to 4.0 mm) presented normal length to width ratio with slight, swollen contour. There was no loss of parenchymal detail. This is most consistent with reactive lymphadenitis or lymphatic hyperplasia. This is a minor change.

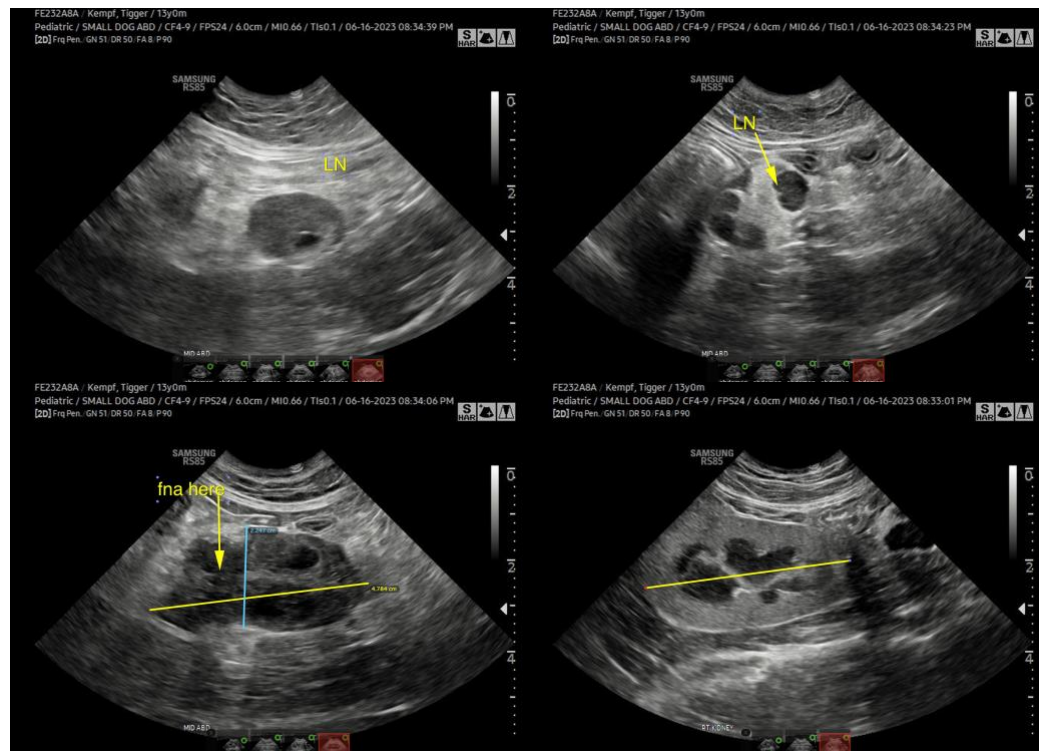
The mid abdomen revealed an undifferentiated **mass**, measuring 4.8 cm x 2.3 cm, appears to be deriving from distal small intestine or lymph node-based origin. Other smaller lymph nodes were enlarged and rounded with distorted contour, measuring up to 8.0 mm. Regional inflammation was noted.

**ULTRASONOGRAPHIC FINDINGS**

- Undifferentiated mid abdominal mass with regional lymphadenopathy- suspect lymph node or intestinal origin. This is a multicentric process, suspect round cell neoplasia. Minor potential for carcinoma.
- Age-related renal and hepatic changes

**INTERPRETATION OF THE FINDINGS & FURTHER RECOMMENDATIONS**

FNA of the pathology is indicated with chemoreduction therapy based on cytology results.





**PATIENT**

Tigger Kempf/Oswalt

**SPECIES**

Feline

**BREED**

DSH

**SEX**

Neutered Male

**AGE**

13 Years

**WEIGHT**

5.44 kg

**INTERPRETED BY**

Eric Lindquist, DMV  
DABVP, Cert. IVUSS

**IMAGING PERFORMED BY**

Dr. Schwanebeck

**HOSPITAL NAME**

Animal Emergency  
Hospital Deland

**REFERRING VET**

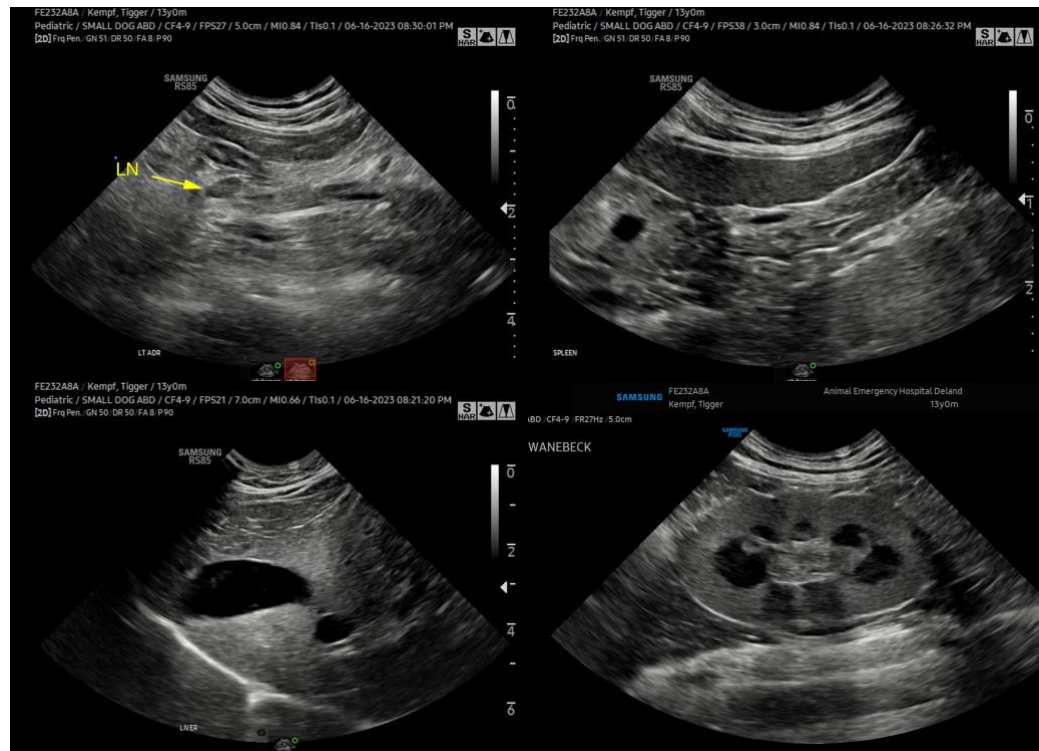
Dr. Schwanebeck

**INVOICE**

22942

**DATE**

6/16/23



The information and recommendations provided are based on the images presented by the referring veterinarian. No evaluation can be communicated regarding pathology that was not visible in the image/video clips provided.

Thank you for this referral. If the clinical or image interpretation does not parallel your findings or if I can be of any further assistance please contact me.

**Eric Lindquist**, DMV, DABVP, Cert. IVUSS, CEO of SonoPath.com  
info@SonoPath.com