



## PATIENT

Kiki Wade

## SPECIES

Feline

## BREED

DSH

## SEX

Neutered Male

## AGE

17

## WEIGHT

9.85

## INTERPRETED BY

Eric Lindquist, DMV  
DABVP, Cert. IVUSS

## IMAGING PERFORMED BY

Dr. Sheldon

## HOSPITAL NAME

Advanced PetCare of  
Oakland

## REFERRING VET

Dr. Sheldon

## INVOICE

22929

## DATE

6/16/23

## PRESENTING CLINICAL SIGNS

History: Pet has been having on and off diarrhea for a month. Also has occasional soft stool. Has lost 1 pound. Started pet on canned feline biome and metronidazole. Still having soft stool. Bloodwork pending. Screening radiographs of chest and abdomen had no significant findings. Fecal was negative. Pet had hyperthyroidism but had radioactive iodine and is not on medications. Pet is also on fortiflora/B12/cosequin/Zylkene .

## ULTRASONOGRAPHIC EXAMINATION OF THE ABDOMEN

### Urinary System

The **urinary bladder**, trigone, and pelvic urethra presented normal thicknesses and normal tone. The ureters were not visible which is normal. No uroliths or sediment were visualized and anechoic urine was present. No evidence of inflammatory or neoplastic changes were noted. Ureteral papillae were normal. The pelvic urethra was imaged 1.0 cm beyond the cystourethral junction.

The **kidneys** revealed largely normal size and structure, corticomedullary definition and ratio (cortex 1/3 of medulla) were essentially maintained with some mild age-related loss of curvilinear patterns regarding the capsule and C/M junction. The cortices presented largely uniform texture with some increased echogenicity expected for his age patient. Medullary structure differed distinctly from that of the cortex and no evidence of pelvic dilation was present. The right kidney measured 4.45 cm. The left kidney measured 4.05 cm.

### Adrenal Glands

The regions of the **adrenal glands** revealed no evident pathology.

### Spleen

The **spleen** presented a smooth homogeneous parenchyma hyperechoic to liver and renal cortical parenchyma. The capsule was smooth without noticeable expansion or deviation from within the spleen or adjacent pathology. The splenic vasculature demonstrated normal volume without signs of congestion or thrombosis. No sonographic evidence of acute or chronic inflammatory, neoplastic, or infarctual changes were noted.

### Liver

The **liver** images from right and left intercostal as well as subcostal views revealed subjectively normal liver size, contour, and structure. Some minor age-related parenchymal remodeling was noted but likely not clinically significant at this time. Vascular and biliary tracts were of normal volume and no evidence of congestion was noted. The gallbladder presented some dependent debris with essentially normal contour. The cystic and common bile ducts were normal. No overt evidence of active inflammatory, infiltrative or regenerative pathology was noted but should be paired with current or past LE elevations regarding any clinical significance to this presentation. The hepatic lymph nodes were unremarkable.

### Gastrointestinal

The **gastrointestinal tract** revealed minor variable thickening and echogenic submucosal changes most consistent with low grade end result of chronic GI disease such as IBD and may be related to



**PATIENT**

Kiki Wade

malassimilation of nutrients if any weight loss is present. No obvious neoplastic patterns were noted and luminal content as unremarkable.

**Pancreas**

**SPECIES**

Feline

The base and limbs of the **pancreas** were observed to be largely isoechoic to surrounding omental fat. Pancreatic duct and capsular contour were acceptably normal and parenchyma respected normal curvilinear patterns. No overt evidence of active inflammatory or neoplastic disease was noted.

**BREED**

DSH

**ULTRASONOGRAPHIC FINDINGS**

- Minor intestinal thickening
- Geriatric abdomen otherwise

**SEX**

Neutered Male

**INTERPRETATION OF THE FINDINGS & FURTHER RECOMMENDATIONS**

This is a nonspecific presentation. Differentials for diarrhea include occult parasitism. Dietary indiscretion, dietary intolerance, antibiotic responsive colitis, intestinal dysbiosis and occult Addison's should all be considered as causes of diarrhea in this patient. A hydrolyzed diet trial may be in this patient's best interest +/- probiotics. 24-hour NPO and reintroduction of bland diet indicated. I recommend a baseline cortisol or ACTH stimulation test, a fresh fecal smear and fecal floatation analysis if not already performed. No neoplastic criteria was noted in the GI tract.

**AGE**

17

**WEIGHT**

9.85

**INTERPRETED BY**

Eric Lindquist, DMV  
DABVP, Cert. IVUSS

**IMAGING  
PERFORMED BY**

Dr. Sheldon

**HOSPITAL NAME**

Advanced PetCare of  
Oakland

**REFERRING VET**

Dr. Sheldon

**INVOICE**

22929

**DATE**

6/16/23



**PATIENT**

Kiki Wade

**SPECIES**

Feline

**BREED**

DSH

**SEX**

Neutered Male

**AGE**

17

**WEIGHT**

9.85

**INTERPRETED BY**

Eric Lindquist, DMV  
DABVP, Cert. IVUSS

**IMAGING PERFORMED BY**

Dr. Sheldon

**HOSPITAL NAME**

Advanced PetCare of  
Oakland

**REFERRING VET**

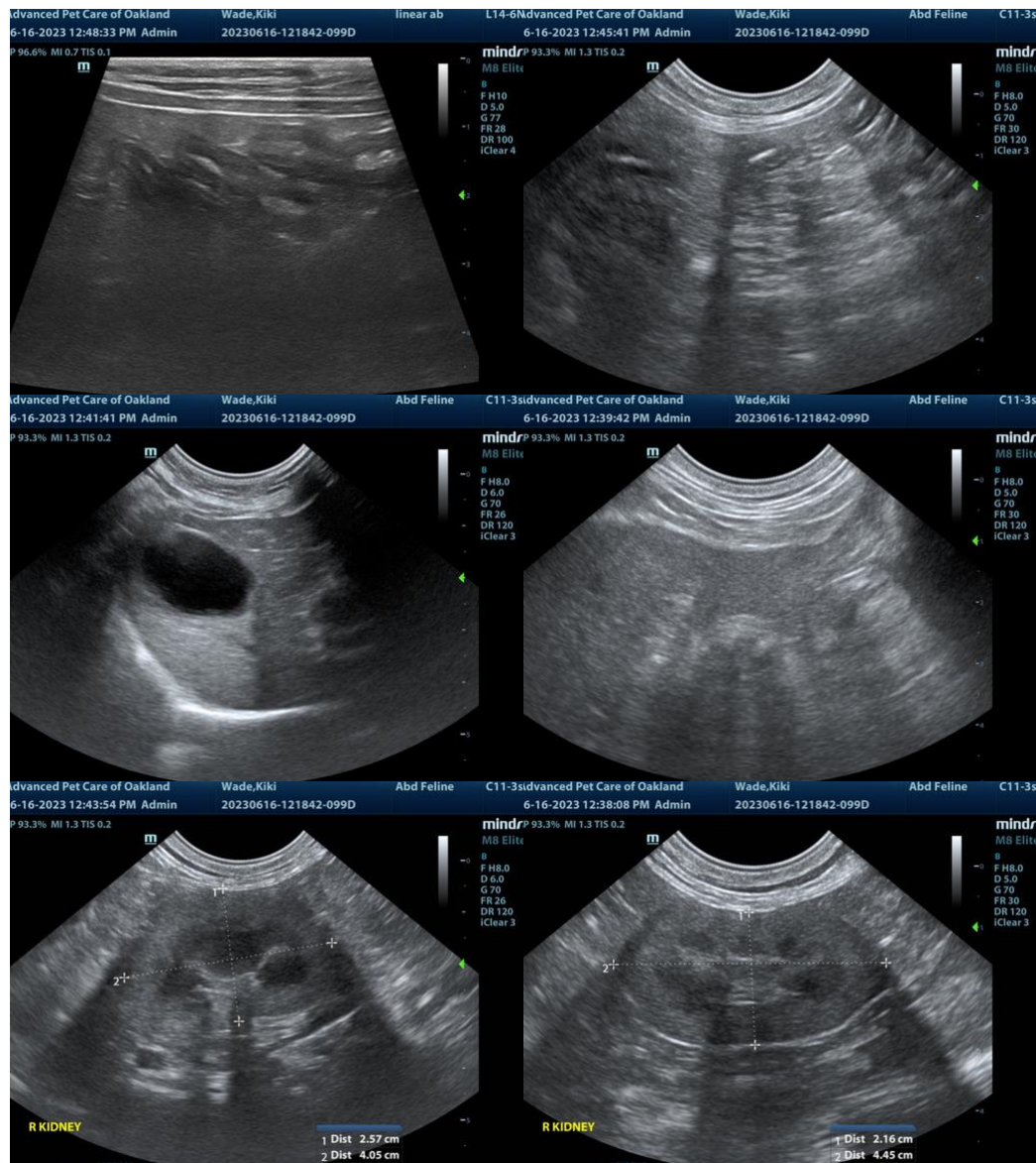
Dr. Sheldon

**INVOICE**

22929

**DATE**

6/16/23



The information and recommendations provided are based on the images presented by the referring veterinarian. No evaluation can be communicated regarding pathology that was not visible in the image/video clips provided.

Thank you for this referral. If the clinical or image interpretation does not parallel your findings or if I can be of any further assistance please contact me.

**Eric Lindquist**, DMV, DABVP, Cert. IVUSS, CEO of SonoPath.com  
info@SonoPath.com