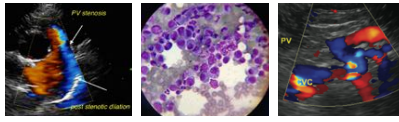


IMAGING PERFORMED BY

IntraPet.com



DATE

6/16/23

PATIENT

Jasper Longan

SPECIES

Canine

BREED

Mix

SEX

Neutered male

AGE

2/1/19

WEIGHT

65.6 lbs

INTERPRETED BY

Eric Lindquist, DMV DABVP, Cert. IVUSS

HOSPITAL NAME

Honeygo AH

REFERRING VET

Dr. Mullenex

INVOICE

47787

PRESENTING CLINICAL SIGNS

Swelling ventral neck central, nonpainful. Chokes sometimes when eating. Maybe having trouble eating.

Current Medications: Prednisone 20mg SID started 4/15.

Lab Results: T4 1.3 (0.9-3.5).

Radiographs: See attached.

Date of Previous IntraPet Ultrasound: No previous.

Sedation: Not required to complete full diagnostic ultrasound.

Stat Report: Not requested.

Imaging Performed By: Andi Parkinson, BS, RDMS.

ULTRASONOGRAPHIC EXAMINATION OF THE THYROID

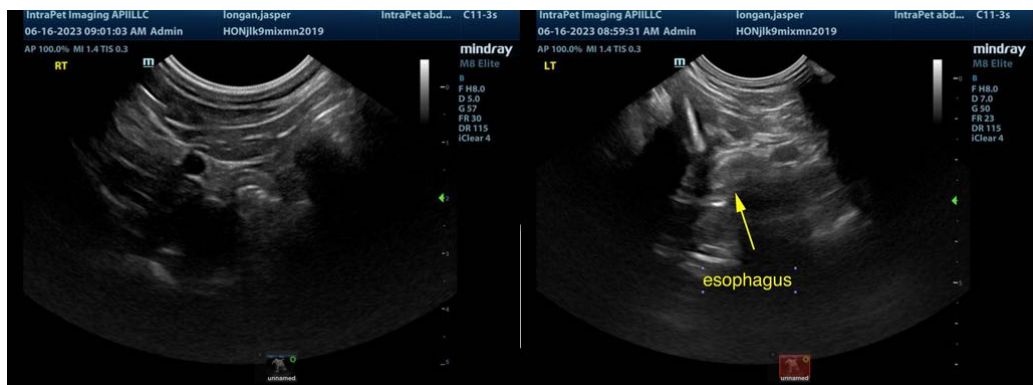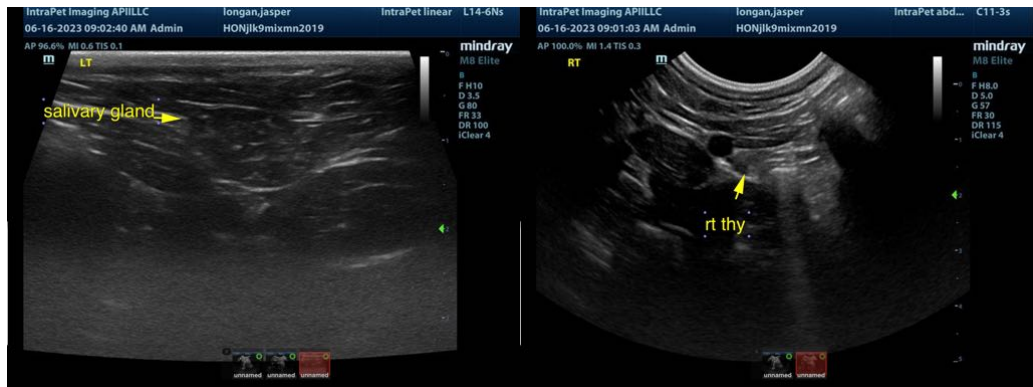
The thyroid lobes were uniform with no evidence of pathology. The left lobe measures 0.44 cm in width. The right lobe measured 0.56 cm. The salivary glands, trachea and esophagus are all unremarkable. The subcutaneous tissue and musculature all appeared normal.

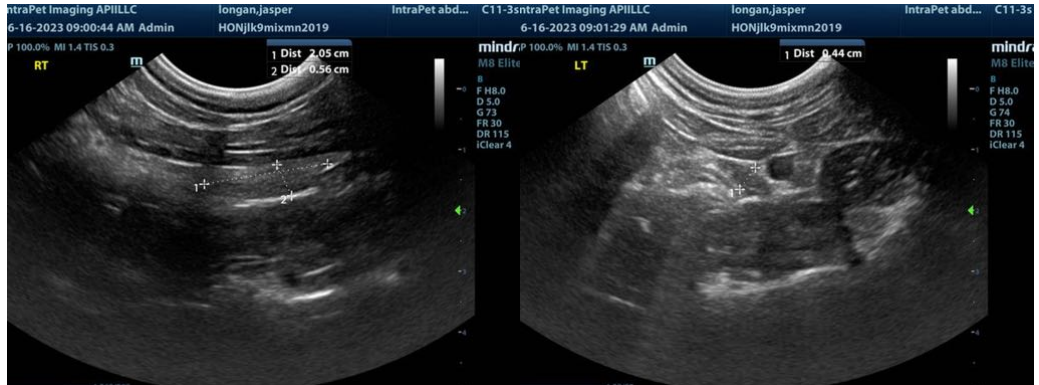
ULTRASONOGRAPHIC FINDINGS

Normal cervical region.

INTERPRETATION OF THE FINDINGS & FURTHER RECOMMENDATIONS

There was no evidence of pathology.





The information and recommendations provided are based on the images presented by the referring veterinarian. No evaluation can be communicated regarding pathology that was not visible in the image/video clips provided.

Thank you for this referral. If the clinical or image interpretation does not parallel your findings or if I can be of any further assistance please contact me.

Eric Lindquist, DMV, DABVP, Cert. IVUSS, CEO of SonoPath.com
info@SonoPath.com