



PATIENT

Rusty Wilson

SPECIES

Canine

BREED

CKCS

SEX

Neutered Male

AGE

8.5 Years

WEIGHT

14.9 Pounds

PRESENTING CLINICAL SIGNS

Follow up FAST and GI study. Detailed study interpreted on 6/15 (see report) at sonopath. Strongly suspect mural jejunal mass based on this study with proximal obstruction. Other history in prior report.

Abnormal PE/Chem/CBC/UA Results: -Initial hypercalcemia (now resolved) -Ongoing diarrhea, not eating.

LIMITED ULTRASONOGRAPHIC EXAMINATION

An obstructive mural intestinal thickening was noted in this patient, measuring approximately 2.0 cm x 1.0 cm. This appears localized and resectable. Minor reactive mesentery noted around the lesion. Small intestinal stasis followed by empty small intestine.

ULTRASONOGRAPHIC FINDINGS

- 1.0 cm x 2.0 cm mural intestinal thickening, partially obstructive, with reactive mesentery

INTERPRETATION OF THE FINDINGS & FURTHER RECOMMENDATIONS

Recommend surgical intervention with ideally intraoperative ultrasound to delineate the complete intestinal pathological pattern for adequate resection, especially given that the serosa does not appear affected, and therefore may be difficult to localize adequately from a surgical standpoint. However, the surgeon may follow the minor fluid dilation to its finality, in which a peanut sized thickening will be found. Resection of approximately 6.0 cm of intestinal recommended at that point. No evidence of metastatic disease in the image set provided. Differentials include granulomatous lesion, carcinoma, less likely focal round cell neoplasia. No evidence of foreign bodies.

INTERPRETED BY

Eric Lindquist, DMV

DABVP, Cert. IVUSS

IMAGING PERFORMED BY

Dr. Schneck

HOSPITAL NAME

Willamette VH

REFERRING VET

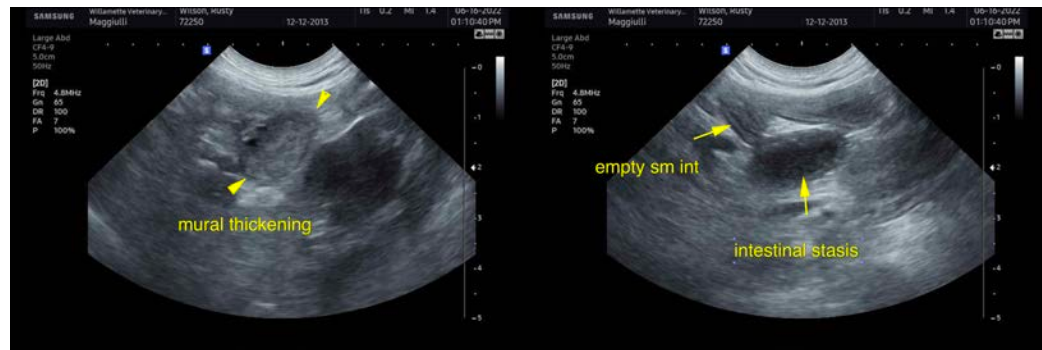
Dr. Schneck

INVOICE

38767

DATE

6/16/22



The information and recommendations provided are based on the images presented by the referring veterinarian/sonographer. No evaluation can be communicated regarding pathology that was not visible in the image/video clips provided.

Thank you for this referral. If the clinical or image interpretation does not parallel your findings or if I can be of any further assistance please contact me.

Eric Lindquist, DMV, DABVP, Cert. IVUSS, CEO of SonoPath.com

info@SonoPath.com