



PATIENT

Louie Strickling

PRESENTING CLINICAL SIGNS

History: Grade 5/6 systolic heart murmur asymptomatic
 Abnormal PE/Chem/CBC/UA Results: CBC/CHEM/UA pending

SPECIES

Canine

ULTRASONOGRAPHIC EXAMINATION OF THE HEART

BREED

Chihuahua

The echocardiogram in this patient demonstrated enlarged **left atrial** size based on 3 different LA measurement methods. Chamber volumes and echogenicity were normal. The cranial and caudal **mitral** valve leaflets presented vegetative thickening consistent with endocardiosis. Prolapse of the anterior mitral valve leaflet was noted. Doppler indicated measurable insufficiency. The **left ventricle** presented thicknesses with linear contour and was not dilated nor restricted. The **myocardium** presented normal echogenicity without subjective evidence of significant fibrotic or ischemic disease. **Contractility** of the ventricular walls was adequate and in normal range for this patient evidenced by the fractional shortening measurement and subjective evaluation of the different regions of the myocardium. The **left ventricular outflow** tract demonstrated normal laminar flow and subjective structural integrity. The **right atrium** and auricle revealed normal size, structure and content. No evidence of masses was noted or chamber overload. **Tricuspid** valvular assessment demonstrated adequate linear morphology. The **right ventricle** was of normal size (1/3 diameter of LV), chordae structure, myocardial echogenicity and thickness. **Pulmonic** tract assessment revealed normal valve structure, laminar flow, and diameter (approx. 1:1 pa/ao ratio). No visible **pericardial** or free pleura fluid was noted. No echographically detectable evidence of infiltrative disease was visible. The cranial **mediastinum** and **pericardial** regions were free of masses in the visible window.

SEX

Spayed Female

AGE

13 years

WEIGHT

12 lbs

INTERPRETED BY

Eric Lindquist, DMV
 DABVP, Cert. IVUSS

IMAGING PERFORMED BY

Dr. Gunther

HOSPITAL NAME

New Frontier AMC

REFERRING VET

Dr. Gunther

| CANINE | MR | TR | LA/AO | LA/AO | FS | EF | EPSS |
|---------------------------|----------------------|----------------------|---------------------|-------------------|------------------------------------|---------------------------------------|---------------------------------------|
| CARDIAC PARAMETERS | VMAX (m/s) | VMAX (m/s) | (Boon method) | (Heart Base; Swe) | (%) | (%) | (cm) |
| NORMAL PARAMETER | 4.5-5.5 | <2.7 | 1.3 | <1.3 | 28-40 | 40-100 | <0.6 |
| PATIENT | 5.8 | | NM | 2.0 | 45 | 90 | 0.1 |
| CANINE | HR | AV | PV | BODY WEIGHT | LA | LVIDd | LVIDs |
| CARDIAC PARAMETERS | (BPM) | VMAX (m/s) | MAX (m/s) | | 2D short axis Base view (cm) | Avg; 2D and m-mode short axis (cm) | Avg; 2D and m-mode short axis (cm) |
| NORMAL PARAMETER | 50-100 | 0.7-1.7 | 0.7-1.6 | | | | |
| PATIENT | | | | 12 lbs | 3.1 max | 3.11 | |

INVOICE

31047

DATE

6/15/22



PATIENT

Louie Strickling

SPECIES

Canine

BREED

Chihuahua

SEX

Spayed Female

AGE

13 years

WEIGHT

12 lbs

INTERPRETED BY

Eric Lindquist, DMV
DABVP, Cert. IVUSS

IMAGING PERFORMED BY

Dr. Gunther

HOSPITAL NAME

New Frontier AMC

REFERRING VET

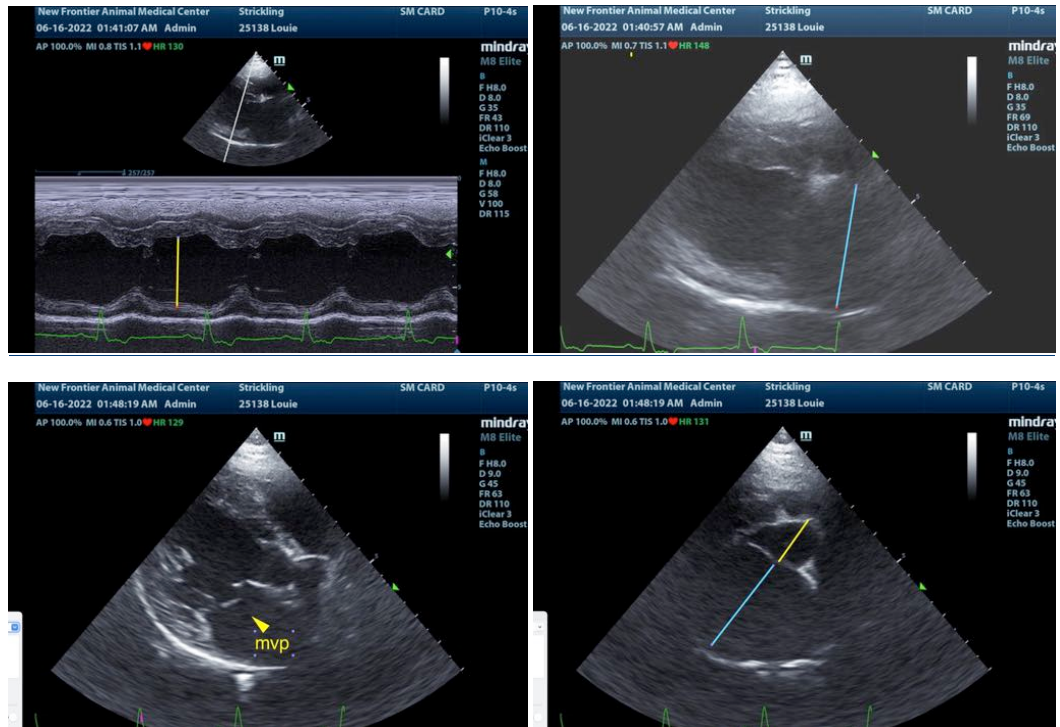
Dr. Gunther

INVOICE

31047

DATE

6/15/22



The information and recommendations provided are based on the images presented by the referring veterinarian/sonographer. No evaluation can be communicated regarding pathology that was not visible in the image/video clips provided.

Thank you for this referral. If the clinical or image interpretation does not parallel your findings or if I can be of any further assistance please contact me.

Eric Lindquist, DMV, DABVP, Cert. IVUSS, CEO of SonoPath.com
info@SonoPath.com