



**PATIENT PRESENTING CLINICAL SIGNS**

**PATIENT**  
Charlie Rankin

**SPECIES**  
Canine

**BREED**  
Husky Mix

12 year old MN Husky Mix 66.8 lbs presented for 5 year history of irritable bowel disease diagnosed by surgical biopsies by internal medicine specialist. Long term medications of prednisone 10 mg SID, metronidazole 250 mg SID, pantoprazole 20 mg SID, metoclopramide 10 mg BID. Patient is obese but does not eat well per owner. On recent screening blood work ALT 531, ALP 1176, and AST 121 were elevated with USG 1.008, GGTP 6, Bili 0.1 on June 2, 2022. Previously, 5/2021 - AST 25, ALT 86, ALP 320, GGTP 27 Bili 0.1 - DDX: reassessment of digestive tract and screen liver for pathology. ALT today 588

Abnormal PE/Chem/CBC/UA Results: ALT 531, ALP 1176, and AST 121 were elevated with USG 1.008, GGTP 6, Bili 0.1 on June 2, 2022. Previously, 5/2021 - AST 25, ALT 86, ALP 320, GGTP 27 Bili 0.1 ALT today 588

**ULTRASONOGRAPHIC EXAMINATION OF THE ABDOMEN**

**SEX**

Neutered male

**Urinary System**

The **urinary bladder** revealed a trace amount of sand accumulation measuring 0.5 cm.

**AGE**

12 years

The **kidneys** revealed normal size and structure, corticomedullary definition and ratio for this age. The cortices presented largely uniform texture with normal echogenic relationship to liver and spleen. Medullary structure differed distinctly from the cortex and no evidence of pelvic dilation was present. The capsules were acceptably uniform without significant irregularities. The left kidney measured 6.92 cm. The right kidney measured 6.0 cm.

**WEIGHT**

66.8 lbs

**INTERPRETED BY**

Eric Lindquist, DMV  
DABVP, Cert. IVUSS

**Adrenal Glands**

Both **adrenal glands** were visualized and recognized as having normal shape, size, position and echogenicity for this breed. The phrenic vasculature, glandular echogenicity and detail were unremarkable. Capsule, cortex, and medullary definition were normal for this age patient. The right adrenal gland measured 0.51 cm. The left adrenal gland measured 0.44 cm.

**IMAGING PERFORMED BY**

Dr. Schanche

**Spleen**

**HOSPITAL NAME**

TotalBond VH

The **spleen** presented a smooth homogeneous parenchyma hyperechoic to liver and renal cortical parenchyma. The capsule was smooth without noticeable expansion or deviation from within the spleen or adjacent pathology. The splenic vasculature demonstrated normal volume without signs of congestion or thrombosis. No sonographic evidence of acute or chronic inflammatory, neoplastic, or infarctual changes was noted.

**REFERRING VET**

Dr. Schanche

**Liver**

**INVOICE**

31052

The right lateral and caudal **liver** was unremarkable. However, coalescing liver masses were noted and occupied the majority of the left liver and deviated the diaphragm cranially and the stomach caudally. The gallbladder presented acceptably thin walls with primarily anechoic content. The cystic and common bile ducts were normal.

**DATE**

6/15/22



**PATIENT**

**Gastrointestinal**

Charlie Rankin

The **gastric** wall was mildly thickened and measured up to 0.6 cm. The small intestines and colon were unremarkable.

**SPECIES**

Canine

**Pancreas**

**BREED**

Husky Mix

The base and limbs of the **pancreas** were observed to be largely isoechoic to surrounding omental fat. Pancreatic duct and capsular contour were acceptably normal and parenchyma respected normal curvilinear patterns. No overt evidence of active inflammatory or neoplastic disease was noted.

**SEX**

Neutered male

**ULTRASONOGRAPHIC FINDINGS**

Parenchymal and cystic liver mass with abscess or cavitated portion.

**AGE**

12 years

**INTERPRETATION OF THE FINDINGS & FURTHER RECOMMENDATIONS**

CT evaluation is warranted to assess if surgery is an option. However, the cystic portion of the mass extended medially into the right liver and deviated the gallbladder cranially. Ultrasound-guided drainage of the cystic portion of the mass and FNA of the parenchymal of the mass is warranted. This is likely cavitated or partially cavitated carcinoma. Granulomatous lesion is possible, yet less likely. Prognosis is very guarded.

**WEIGHT**

66.8 lbs

**INTERPRETED BY**

Eric Lindquist, DMV  
DABVP, Cert. IVUSS

**IMAGING PERFORMED BY**

Dr. Schanche

**HOSPITAL NAME**

TotalBond VH

**REFERRING VET**

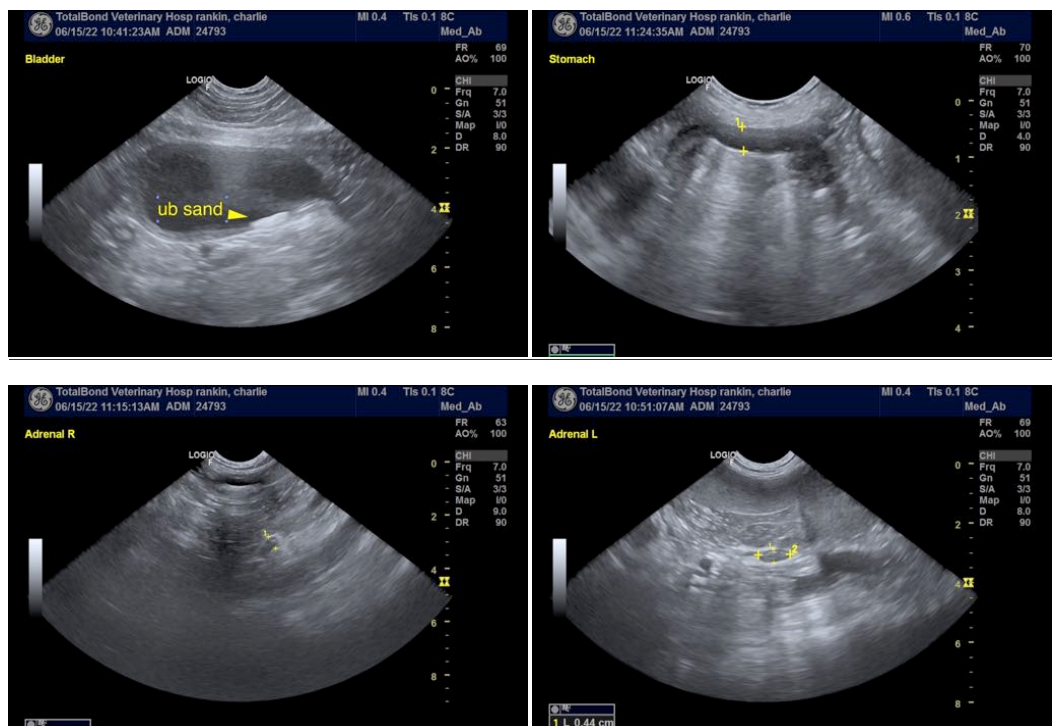
Dr. Schanche

**INVOICE**

31052

**DATE**

6/15/22





**PATIENT**

Charlie Rankin

**SPECIES**

Canine

**BREED**

Husky Mix

**SEX**

Neutered male

**AGE**

12 years

**WEIGHT**

66.8 lbs

**INTERPRETED BY**

Eric Lindquist, DMV  
DABVP, Cert. IVUSS

**IMAGING PERFORMED BY**

Dr. Schanche

**HOSPITAL NAME**

TotalBond VH

**REFERRING VET**

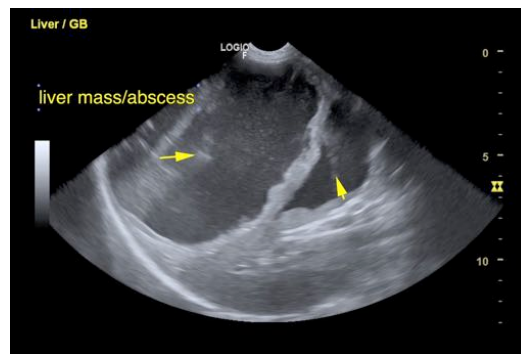
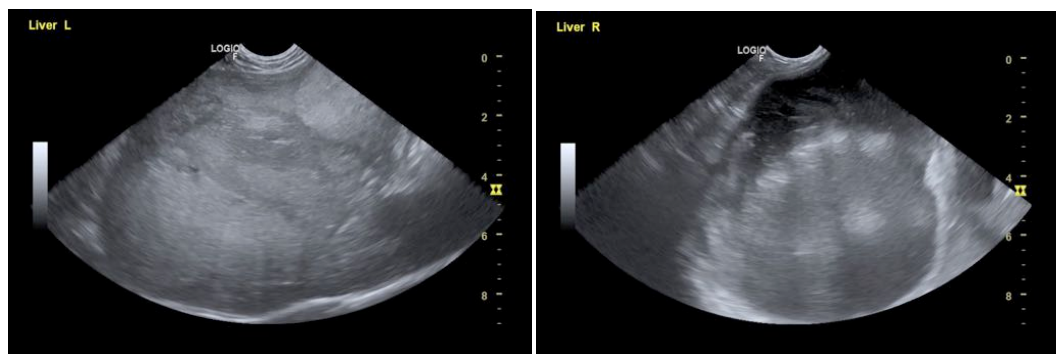
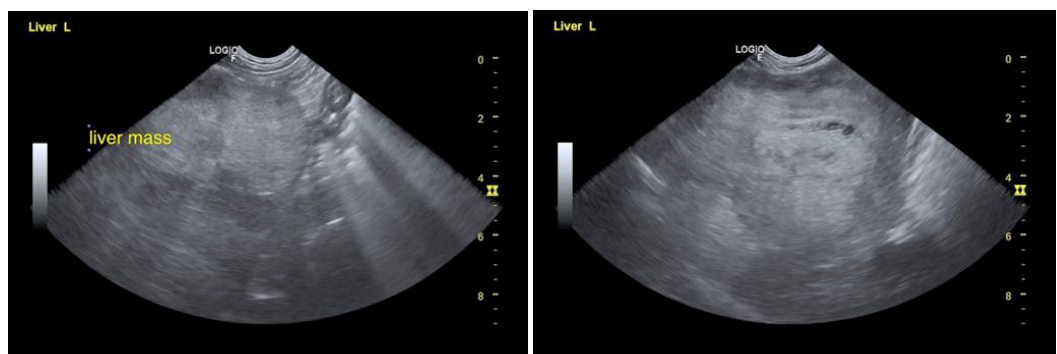
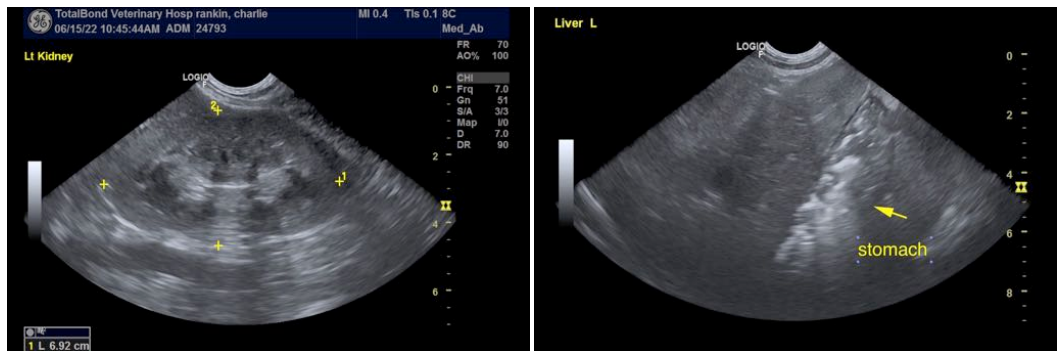
Dr. Schanche

**INVOICE**

31052

**DATE**

6/15/22



The information and recommendations provided are based on the images presented by the referring veterinarian/sonographer. No evaluation can be communicated regarding pathology that was not visible in the image/video clips provided.



**PATIENT**

Thank you for this referral. If the clinical or image interpretation does not parallel your findings or if I can be of any further assistance please contact me.


Charlie Rankin

**SPECIES**

Eric Lindquist, DMV, DABVP, Cert. IVUSS, CEO of SonoPath.com  
info@SonoPath.com

Canine

**BREED**



The following is an applicable excerpt from the *Curbside Guide to Diagnosis & Treatment of Sonographic Disease* offered by [SonoPath.com](http://sonopath.com) Lindquist, Frank, Lobetti, and Modler.

Husky Mix

An essential quick guide for every general practitioner and sonographer.

<https://sonopath.com/products/curbside-guide-editing-due-release-12012015>

**SEX**

Neutered male

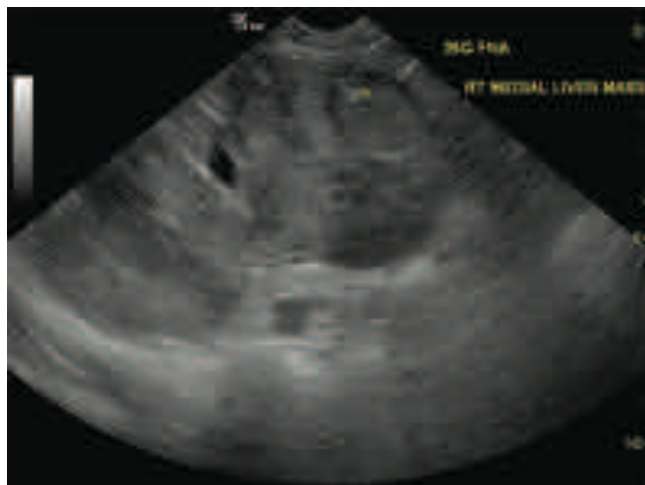
**Hepatic Masses, Biliary Adenoma, and Biliary Adenocarcinoma**

**AGE**

<http://www.sonopath.com/HepaticMasses>

12 years

**WEIGHT**



Fine needle aspiration of a right medial lobe mass of a canine liver in subxiphoidal short axis. A large heterogenous mass lesion is seen expanding upon the liver capsule. Note the hyperechoic needle tip (arrowhead) within the mass. US- guided FNA captures cells and may not be sensitive to structural pathology or carcinoma present in the midst of vacuolar hepatopathy or nodular hyperplastic changes. Hence, the sonographer should sample a variety of echogenicities within the lesion or perform a core biopsy.

66.8 lbs

**INTERPRETED BY**

Eric Lindquist, DMV  
DABVP, Cert. IVUSS

**IMAGING PERFORMED BY**

Dr. Schanche

**HOSPITAL NAME**

TotalBond VH

**REFERRING VET**

Dr. Schanche

**Description:** Hepatocellular carcinoma typically manifests in the liver's left lateral lobes, yet may cross over to the right lobes should it derive from the hilus. These masses often present cavitating, necrotic cores that are difficult to distinguish from hepatic abscesses. Vascular channels may also be involved, and bile duct obstruction is often present. Older felines often present solitary or multiple fluid-filled cysts within the hepatic parenchyma. The latter are typically benign cystadenomas and should be differentiated from: cystic adenocarcinoma; hepatic lymphoma (usually diffusely hyperechoic +/- FIV/FelV association); metastatic neoplasia (diffuse hyper- to hypoechoic nodules secondary to mammary adenocarcinoma, splenic hemangiosarcoma, or pancreatic or intestinal adenocarcinoma); benign nodular hyperplasia (accompanied by minimal to no symptoms); hepatic cirrhosis (regenerative nodules); or rare carcinoids, fibrosarcomas, leiomyosarcomas, and osteosarcomas.

**INVOICE**

31052

**DATE**

6/15/22



**PATIENT**

Charlie Rankin

**Clinical Signs:** Possible clinical signs and physical exam findings include cranial abdominal organomegaly, sudden collapse associated with mass rupture, vomiting, ascites, jaundice (severe cases), and hypoglycemia secondary to a paraneoplastic syndrome. Sepsis and fever associated with secondary abscessation of the mass may also occur. Cats usually present with anorexia and lethargy.

**SPECIES**

Canine

**Diagnostics:** Routine biochemical analysis primarily shows liver enzyme elevation (i.e., ALT for cellular necrosis; SAP for hepatic congestion; elevated bilirubin for stasis/obstruction; bile acids > 75-100uM/L for significant function impairment). Staging of the disease with 3-view thoracic radiographs is essential, as is conducting a CBC, serum biochemistry, urinalysis, as well as abdominal and possibly also thoracic ultrasounds in order to provide the owner with adequate and well-informed options. Surgical and oncological referral is recommended after a coagulation panel has been assessed and ultrasound-guided biopsies of both normal and pathological tissue have been performed such that the disease is adequately characterized. In cases where surgical resection is impossible, direct chemoembolization of the tumor blood supply could be considered; however, this procedure is only performed at specific tertiary referral locations. Placement of palliative stents into the caudal vena cava (CVC) can be considered as well if compression by an unresectable tumor causes excessive ascitic fluid accumulation. Serum alpha-fetoprotein (AFP) has been shown to reemerge in dogs with malignant hepatobiliary adenocarcinoma. Ultrasound is important to localize the mass in relation to the portal hilus and gallbladder. The portal vein, CVC, aorta, gallbladder, and bile duct should all be identified with respect to the location of the mass to determine resectability. Ultrasound also allows for an examination of possible metastatic sites in the abdomen and, to some degree, in the thorax.

**BREED**

Husky Mix

**SEX**

Neutered male

**AGE**

12 years

**Treatment:** Hepatic adenoma, hepatoma, and adenocarcinoma are usually amenable to surgical resection via hepatic lobectomy should the pathology be isolated to single-lobe progression. Multi-lobe presentation may be amenable to lobectomy and debulking; this will be determined further during surgical consultation. These tumors tend to displace unaffected parenchyma, allowing for relatively straightforward surgical resection. Up to 80% of the liver can be removed without long-term functional deficits. Blood transfusions may be necessary during surgery. The development and implementation of the LDS™ stapler has helped to streamline the procedure. Most carcinomas have metastasized by the time of diagnosis yet tend to be slow-growing; thus, it may be possible for a certain quality of life to be attained via surgical resection. Hepatic hemangiosarcoma has usually metastasized at the time of diagnosis and carries a much poorer prognosis. Surgical resection and chemotherapy are recommended, but considered by many to be an “aggressive” approach.

**WEIGHT**

66.8 lbs

**INTERPRETED BY**

Eric Lindquist, DMV  
DABVP, Cert. IVUS

Preliminary trials have shown that gemcitabine is well tolerated and yields good responses in cases of hepatic as well as pancreatic, colonic, and gastric carcinomas. Myelosuppression, however, remains the key issue. Doxorubicin, cyclophosphamide, and fluorouracil combinations have also proven fruitful.

**IMAGING PERFORMED BY**

Dr. Schanche

**HOSPITAL NAME**

TotalBond VH

Nonsteroidal anti-inflammatory drugs (NSAIDs) have been demonstrated to have an anti-neoplastic effect due to their inhibition of COX-2 in certain tumor cells. The end product of the cyclooxygenase cascade is prostaglandin E2, which, when expressed in tumor cell lines—and not expressed in normal cells of that particular cell line—results in inhibited apoptosis, immunosuppression, and increased angiogenesis, proliferation, and invasiveness. Inappropriate increases in COX-2 expression have been documented in certain neoplasias, including squamous cell carcinoma, mammary carcinomas, prostatic carcinoma, malignant melanoma, and transitional cell carcinoma.

**REFERRING VET**

Dr. Schanche

**INVOICE**

31052

Metronomic chemotherapy is currently being investigated and compared to traditional chemotherapy protocols; it is thought to be at least as effective as the latter with substantially less toxic side effects. Metronomic chemotherapy is the practice of uninterrupted administration of low-dose cytotoxic drugs at regular and frequent intervals, as opposed to high-dose, shorter-term protocols characteristic of traditional chemotherapeutic practices. The lower dose allows for long-term administration without

**DATE**

6/15/22



**PATIENT**

Charlie Rankin

**SPECIES**

Canine

**BREED**

Husky Mix

**SEX**

Neutered male

**AGE**

12 years

**WEIGHT**

66.8 lbs

**INTERPRETED BY**

Eric Lindquist, DMV  
DABVP, Cert. IVUSS

**IMAGING PERFORMED BY**

Dr. Schanche

**HOSPITAL NAME**

TotalBond VH

**REFERRING VET**

Dr. Schanche

**INVOICE**

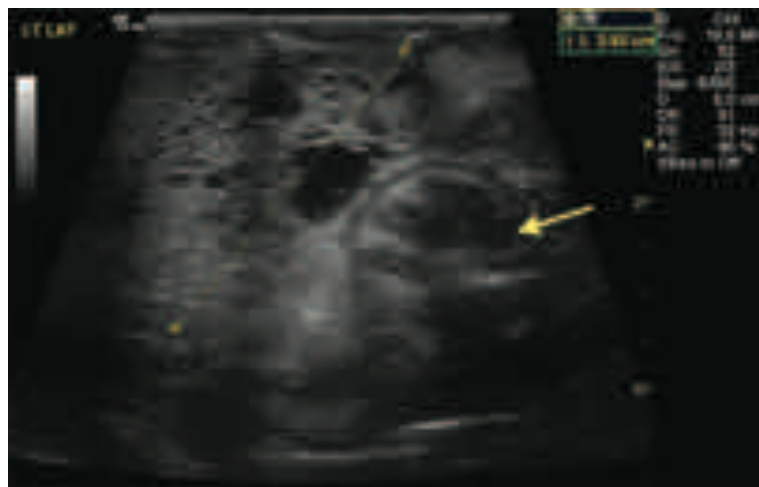
31052

**DATE**

6/15/22

toxic side effects, and has been postulated as providing longer remission intervals. Moreover, it has the benefit of minimizing the intervals between drug regimens—the period during which tumor cells may repopulate the area—as well as the chance of developing multi-drug resistant genes. Metronomic chemotherapy has been used successfully in human patients who have undergone previous chemotherapy administration. It is thought to destroy endothelial cells, thereby retarding angiogenesis and targeting regulatory T cells. To date, there have only been a few small clinical trials in veterinary patients, and these have focused on animals that have hemangiosarcoma and soft tissue sarcomas.

**Conclusion:** With respect to hepatic neoplasia, many surgical and chemotherapeutic options exist; however, it is best to consult with a local board certified oncologist who can help determine the best course of action.



Subxiphoidal long axis of the left liver in a cat with a biliary cystadenoma. Note the typical heterogenous multicystic appearance of the mass lesion displacing the regular echotexture. Acoustic enhancement is seen deep to the cystic components of the lesion. These typically benign tumors can also cause local displacement of organs such as the stomach (arrow), undergo lobar torsion, or malignant transformation that necessitate removal when this criteria is met or suspected.



**PATIENT**

Charlie Rankin

**SPECIES**

Canine

**BREED**

Husky Mix

**SEX**

Neutered male

**AGE**

12 years

**WEIGHT**

66.8 lbs

**INTERPRETED BY**

Eric Lindquist, DMV  
DABVP, Cert. IVUSS

**IMAGING PERFORMED BY**

Dr. Schanche

**HOSPITAL NAME**

TotalBond VH

**REFERRING VET**

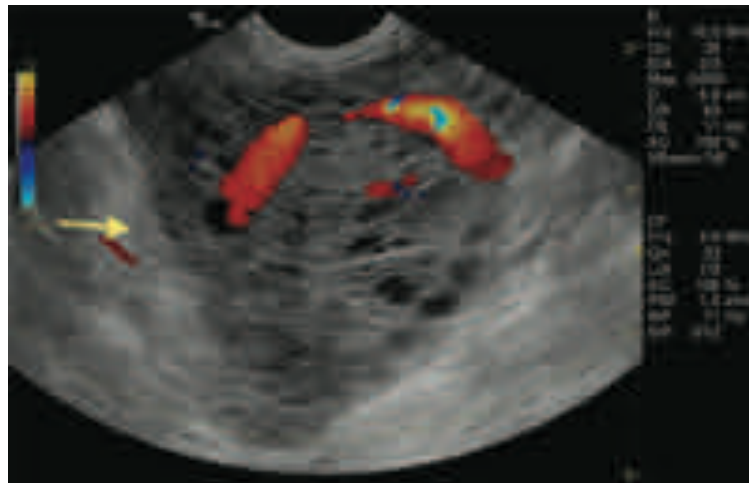
Dr. Schanche

**INVOICE**

31052

**DATE**

6/15/22



Subxiphoidal long axis of the liver in a dog with a hepatocellular carcinoma. A large irregular shaped mass lesion expanding the liver capsule is seen with echogenic fat indicative of inflammation (arrow). The lesion is highly vascularized and heterogenous. A mix of multifocal hyperechoic patches and hypoechoic nodules is seen. Anechoic areas indicate multifocal tumoral necrosis.

**References:**

Billier BJ. Teaching T cells to target tumors: towards the design of more effective cancer vaccines. Proceedings from the American College of Veterinary Internal Medicine Forum, Denver, CO, June 15-18, 2011.

Billier BJ, Guth A, Burton JH, Dow SW. Decreased ratio of CD8+ T cells to regulatory T cells associated with decreased survival in dogs with osteosarcoma. *J Vet Intern Med* 2010;24(5):1118-23.

Elmslie RE, Glawe P, Dow SW. Metronomic therapy with cyclophosphamide and piroxicam effectively delays tumor recurrence in dogs with incompletely resected soft tissue sarcomas. *J Vet Intern Med* 2008;22(6):1373-79.

Lana S, U'Ren L, Plaza S, et al. Continuous low-dose oral chemotherapy for adjuvant therapy of splenic hemangiosarcoma in dogs. *J Vet Intern Med* 2007;21(4):764-69.

Milner RJ. Do NSAIDs make a difference in cancer? Proceedings from the American College of Veterinary Internal Medicine Forum, Denver, CO, June 15-18, 2011.