



PATIENT PRESENTING CLINICAL SIGNS

Wilo Cristobal

The patient presented as a referral for a Neck and Small glands Ultrasound. Hx of a mass on the right side of the neck not fast growing. Not causing swallowing problems or respiratory distress. R/O thyroid mass or lymph nodes. Eating well, no vomiting or diarrhea.

SPECIES

Canine

Abnormal PE/Chem/CBC/UA Results: FNA of the mass was done for cytology: Pending CBC: WNL
CHEM: GLOB 4.7 (2.5-4.5) T4: WNL

BREED

Chihuahua

ULTRASONOGRAPHIC EXAMINATION OF THE THYROID

SEX

Neutered Male

The left thyroid lobe was uniform at 1.2 cm x 0.50 cm. A 4.0 cm x 2.6 cm mixed hypo- to hyperechoic expansive encapsulated mass was noted associated with the right thyroid lobe. The mass was moderately vascular and appears resectable. The esophagus, salivary glands, and regional tissues were unremarkable. The trachea was unremarkable.

AGE

12 Years

ULTRASONOGRAPHIC FINDINGS

- Right mass, likely thyroid in origin

INTERPRETATION OF THE FINDINGS & FURTHER RECOMMENDATIONS

WEIGHT

6.4 Pounds

Ultrasound guided FNA performed without complication. CT evaluation for surgical planning would be ideal. Suspect thyroid carcinoma. Full thyroid panel warranted.

INTERPRETED BY

Eric Lindquist, DMV
DABVP, Cert. IVUSS

IMAGING PERFORMED BY

Dr. Ferrer

HOSPITAL NAME

Paseos Vet Center

REFERRING VET

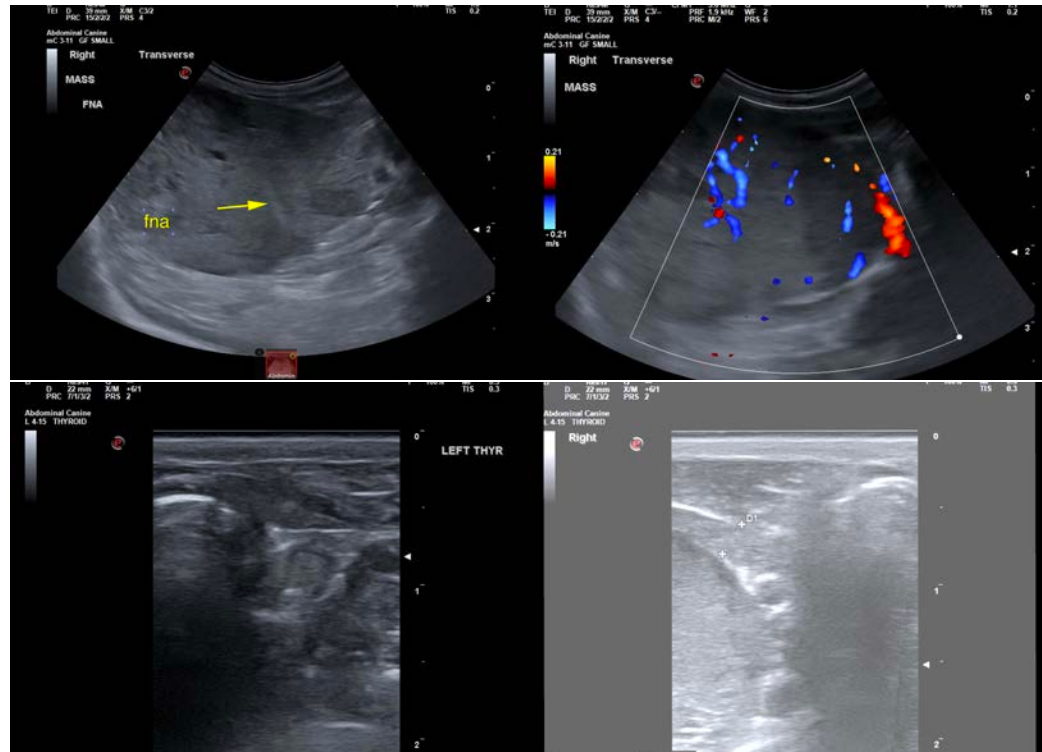
Dr. Maricarmen Vega

INVOICE

43184

DATE

6/14/23





PATIENT

Wilo Cristobal

SPECIES

Canine

BREED

Chihuahua

SEX

Neutered Male

AGE

12 Years

WEIGHT

6.4 Pounds

INTERPRETED BY

Eric Lindquist, DMV

DABVP, Cert. IVUSS

IMAGING PERFORMED BY

Dr. Ferrer

HOSPITAL NAME

Paseos Vet Center

REFERRING VET

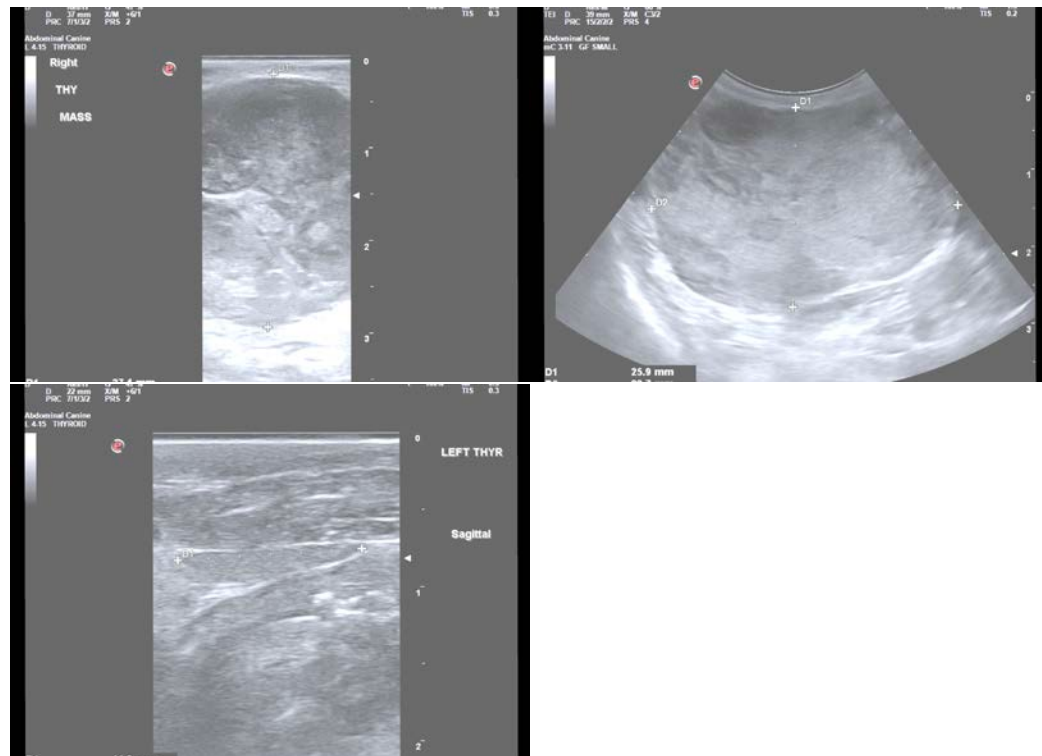
Dr. Maricarmen Vega

INVOICE

43184

DATE

6/14/23



The information and recommendations provided are based on the images presented by the referring veterinarian/sonographer. No evaluation can be communicated regarding pathology that was not visible in the image/video clips provided.

Thank you for this referral. If the clinical or image interpretation does not parallel your findings or if I can be of any further assistance please contact me.

Eric Lindquist, DMV, DABVP, Cert. IVUSS, CEO of SonoPath.com

info@SonoPath.com