



PATIENT

Marvin Walsh

SPECIES

Canine

BREED

Mix

SEX

Neutered Male

AGE

5.5

WEIGHT

69

INTERPRETED BY

Eric Lindquist, DMV
DABVP, Cert. IVUSS

IMAGING PERFORMED BY

Christensen

HOSPITAL NAME

Tranquility VC

REFERRING VET

Dr. Antonelli

INVOICE

22903

DATE

6/14/23

PRESENTING CLINICAL SIGNS

History of heart murmur and previous heartworm disease(treated). Currently has UTI and is on 100 mg Zeniquin once daily. Decreased appetite. Put on Sildenafil by specialist a long time ago but owner not sure why. Unable to locate previous record.

Abnormal PE/Chem/CBC/UA Results: See attached bloodwork and U/A. Dog very aggressive so was sedated with butorphanol and alfaxan. Has 2/6 systolic murmur and a pendulous abdomen.

ULTRASONOGRAPHIC EXAMINATION OF THE HEART & ABDOMEN

CANINE CARDIAC PARAMETERS	MR VMAX (m/s)	TR VMAX (m/s)	LA/AO (Boon method)	LA/AO (Heart Base; Swe)	FS (%)	EF (%)	EPSS (cm)
NORMAL PARAMETER	4.5-5.5	<2.7	1.3	<1.3	28-40	40-100	<0.6
PATIENT	5.0	4.5	NM	1.0	--	--	0.1
CANINE CARDIAC PARAMETERS	HR (BPM)	AV VMAX (m/s)	PV MAX (m/s)	BODY WEIGHT (kg)	LA 2D short axis Base view (cm)	LVIDd Avg; 2D and m-mode short axis (cm)	LVIDs Avg; 2D and m-mode short axis (cm)
NORMAL PARAMETER	50-100	0.7-1.7	0.7-1.6				
PATIENT	--	--	.90	--	2.57	--	--

Cardiac Presentation

The **cardiac presentation** in this patient presented significant volume overload of the right atrium and right ventricle with pulmonic (4.0 m/s) and tricuspid insufficiencies (severe) consistent with severe pulmonary hypertension. Paradoxical septal motion on the left ventricular septum with bowing into the left ventricle, indicative of Eisenmenger's physiology. The left heart was unremarkable with compensated mitral insufficiency. Aortic and pulmonic outflows were adequate. No pericardial or pleural effusion was noted.

Urinary System

The **urinary bladder**, trigone, and pelvic urethra presented normal thicknesses and normal tone. The ureters were not visible which is normal. No uroliths or sediment were visualized and anechoic urine was present. No evidence of inflammatory or neoplastic changes were noted. Ureteral papillae were normal.

The **kidneys** revealed largely normal size and structure, corticomedullary definition and ratio (cortex 1/3 of medulla) were essentially maintained with some moderate age-related loss of curvilinear patterns regarding the capsule and C/M junction. The cortices presented largely uniform texture with some increased echogenicity expected for his age patient. Medullary structure differed distinctly from



PATIENT

Marvin Walsh

that of the cortex and no evidence of pelvic dilation was present. The right kidney measured 6.4 cm. The left kidney measured 5.29 cm. Multiple infarcts were noted and areas of dystrophic mineralization.

Adrenal Glands

SPECIES

Canine

Both **adrenal glands** were visualized and recognized as having normal shape, size, position and echogenicity for this breed. The phrenic vasculature, glandular echogenicity and detail were unremarkable. Capsule, cortex, and medullary definition were normal for this age patient. The left adrenal gland measured 1.46 cm x 0.52 cm at the cranial pole and 0.52 cm at the caudal pole. The right adrenal gland measured 1.53 cm x 0.3 cm.

BREED

Mix

Spleen

SEX

Neutered Male

The **spleen** presented a smooth homogeneous parenchyma hyperechoic to liver and renal cortical parenchyma. The capsule was smooth without noticeable expansion or deviation from within the spleen or adjacent pathology. The splenic vasculature demonstrated normal volume without signs of congestion or thrombosis. No sonographic evidence of acute or chronic inflammatory, neoplastic, or infarctual changes were noted. Cranial folding of the spleen was noted.

AGE

5.5

Liver

The **liver** revealed mild coarse architecture and uniform swelling. The vena cava was dilated. The gallbladder and common bile duct were unremarkable.

WEIGHT

69

Gastrointestinal

Examination of the **gastrointestinal tract** revealed a stomach and intestine free of stasis, of normal wall thickness, acceptable curvilinear mural detail, and peristaltic activity. Small and large intestine demonstrated normal luminal chyme and stool consistency respectively. No obstructive or overt infiltrative disease was noted. No associated abnormal lymphatic activity was noted.

INTERPRETED BY

Eric Lindquist, DMV
DABVP, Cert. IVUSS

Pancreas

The base and limbs of the **pancreas** were observed to be largely isoechoic to surrounding omental fat. Pancreatic duct and capsular contour were acceptably normal and parenchyma respected normal curvilinear patterns. No overt evidence of active inflammatory or neoplastic disease was noted.

IMAGING PERFORMED BY

Christensen

Other

HOSPITAL NAME

Tranquility VC

A moderate amount of **ascites** was noted, secondary to passive congestion in this patient and right sided heart failure.

REFERRING VET

Dr. Antonelli

ULTRASONOGRAPHIC FINDINGS

- Right sided heart failure with valvular disease and volume overload of the right heart.
- Moderate degenerative renal disease
- Ascites, secondary to passive congestion
- Mild coarse architecture and uniform swelling in the liver. The vena cava was dilated.

INVOICE

22903

INTERPRETATION OF THE FINDINGS & FURTHER RECOMMENDATIONS

DATE

6/14/23

I recommend continuation of the Sildenafil, adding Ace-inhibitor 0.5 mg/kg SID (progressing to BID), as well as Spironolactone 1-2 mg/kg BID, and increasing Sildenafil dose by 0.5 mg/kg and reassessment over the next two weeks. Blood pressures, azotemia and USG should be monitored



PATIENT

carefully in this patient. Prognosis is guarded to poor.

Marvin Walsh

SPECIES

Canine

BREED

Mix

SEX

Neutered Male

AGE

5.5

WEIGHT

69

INTERPRETED BY

Eric Lindquist, DMV
DABVP, Cert. IVUSS

IMAGING PERFORMED BY

Christensen

HOSPITAL NAME

Tranquility VC

REFERRING VET

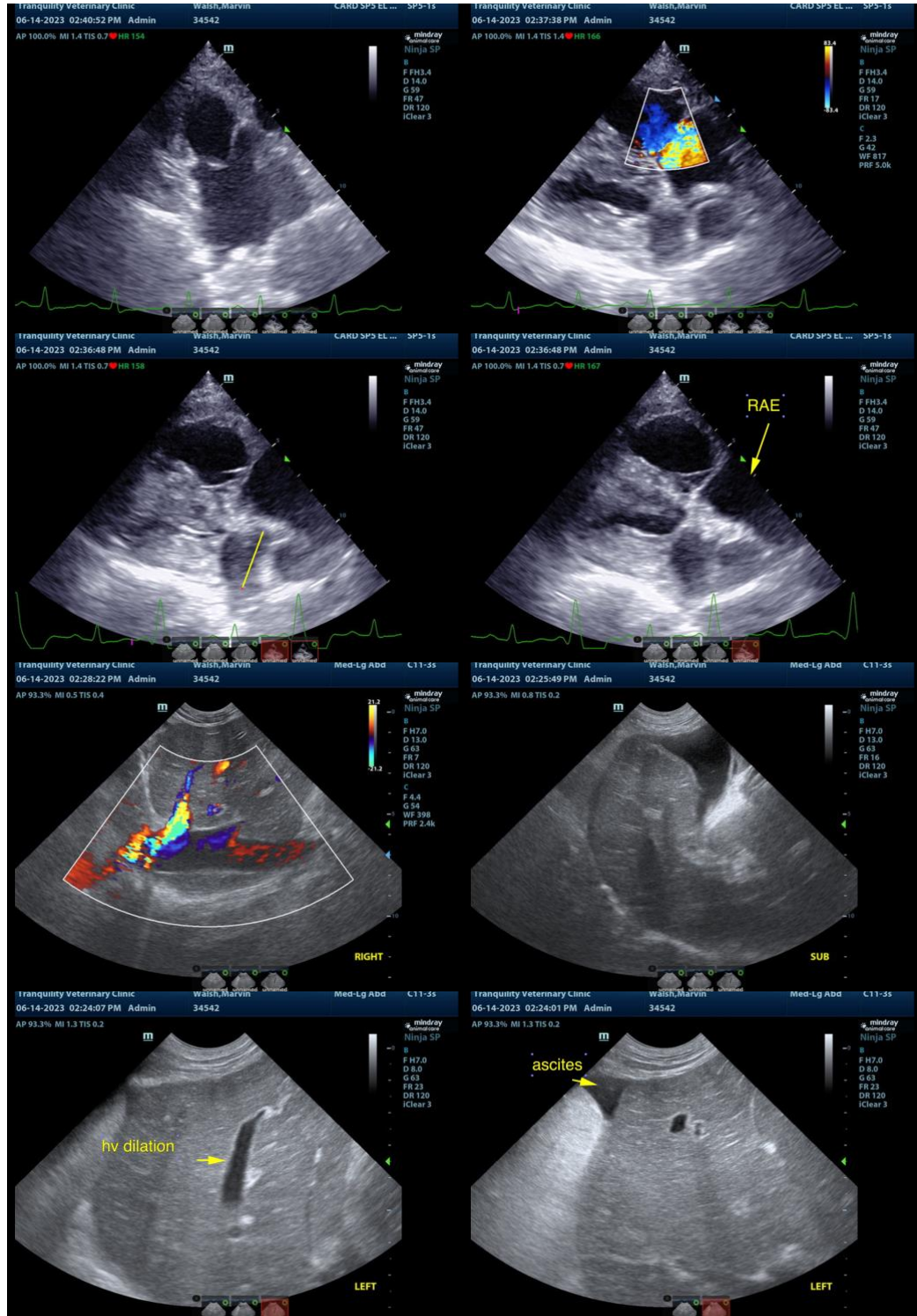
Dr. Antonelli

INVOICE

22903

DATE

6/14/23





PATIENT

Marvin Walsh

SPECIES

Canine

BREED

Mix

SEX

Neutered Male

AGE

5.5

WEIGHT

69

INTERPRETED BY

Eric Lindquist, DMV
DABVP, Cert. IVUSS

IMAGING PERFORMED BY

Christensen

HOSPITAL NAME

Tranquility VC

REFERRING VET

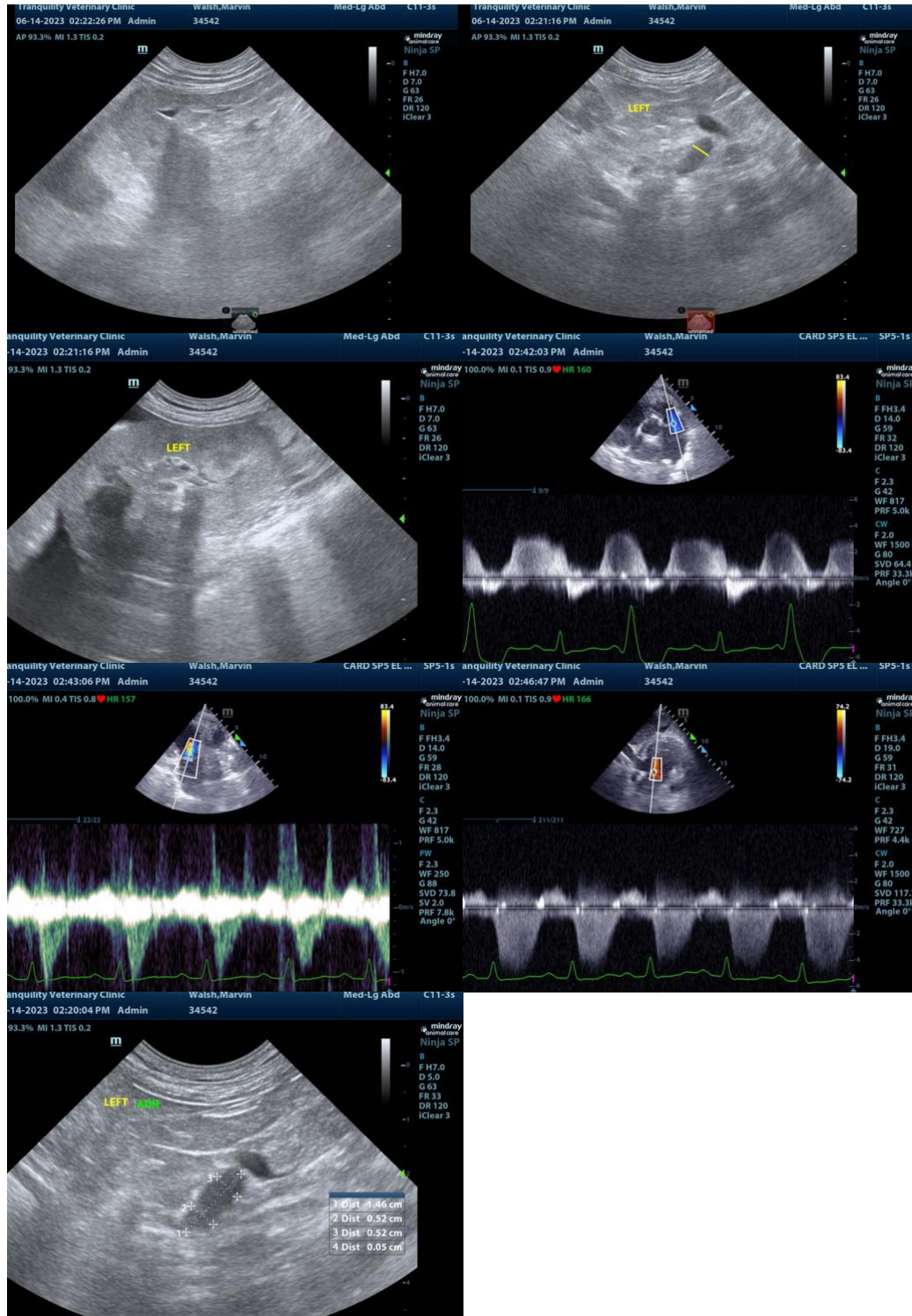
Dr. Antonelli

INVOICE

22903

DATE

6/14/23



The information and recommendations provided are based on the images presented by the referring veterinarian. No evaluation can be communicated regarding pathology that was not visible in the image/video clips provided.



PATIENT

Marvin Walsh

Thank you for this referral. If the clinical or image interpretation does not parallel your findings or if I can be of any further assistance please contact me.

Eric Lindquist, DMV, DABVP, Cert. IVUSS, CEO of SonoPath.com
info@SonoPath.com

SPECIES

Canine

Right Heart Disease-General Considerations

BREED

Mix

<http://www.sonopath.com/RightHeartDisease>

SEX

Neutered Male

Description: Right heart disease is often an incidental finding, which can be either cardiogenic or secondary to respiratory or systemic disease. The coughing patient with right heart disease may present with primary respiratory disease (i.e., bronchial collapse, collapsing trachea, pneumonitis) and suffer from secondary pulmonary hypertension (PHT). Concurrent mitral valve disease and chronic left-sided congestive heart failure (CHF) might also lead to PHT. The dyspeic patient with right heart enlargement might have pulmonary hypertension due to airway disease, chronic CHF, parenchymal lung disease (e.g. pulmonic fibrosis), or a cardiac shunt with secondary PHT and shunt reversal.

AGE

5.5

WEIGHT

69

Primary cardiac causes of right heart enlargement include: tricuspid dysplasia/degeneration; pulmonic stenosis; pulmonic insufficiency; atrial or septal defects; patent ductus arteriosus; right auricular masses; and pericardial peritoneal diaphragmatic hernias. The second most common cause of right-sided enlargement is secondary PHT, which results in high-velocity tricuspid insufficiency (TR vel.>2.8 m/sec) and pulmonic insufficiency due to diseases that cause increased pulmonary vascular resistance or increased pulmonary wedge pressures. The most common cause of secondary PHT is left-sided heart failure (LHF), which presents radiographically as a more globoid-shaped heart with marked left atrial and ventricular enlargement. There are also signs of left-sided CHF as opposed to a simple prominent cranial waist or reverse D radiographic presentation.

INTERPRETED BY

Eric Lindquist, DMV
DABVP, Cert. IVUSS

IMAGING PERFORMED BY

Christensen

HOSPITAL NAME

Tranquility VC

Secondary, non-cardiac causes of PHT include: acute or chronic respiratory disease; pulmonary thromboembolic disease; thoracic neoplasia; excessive thoracic fat deposition (e.g. Pickwickian syndrome, which leads to chronic hypoxia); brachycephalic syndrome; high altitude disease; heartworm disease; and primary vascular disease.

REFERRING VET

Dr. Antonelli

INVOICE

22903

Clinical Signs: The most common presenting symptoms of right heart disease are collapse, syncope, intermittent or constant acute respiratory distress (e.g. thromboembolic disease), and exercise intolerance.

DATE

6/14/23

Diagnostics: Physical examination may reveal a right-sided apical heart murmur and/or a cranial left heart murmur, a split S2, jugular distension, ascites, and signs consistent with respiratory disease (i.e., cough,



PATIENT

Marvin Walsh

wheeze, tracheal collapse, tachypnea). Radiographic findings may reveal an enlarged right atrium, right ventricle, and/or primary/secondary branches of the pulmonary artery. In cases of PHT, an enlarged or engorged pulmonary artery is often present. Tortuous arteries or those that suddenly terminate can indicate the presence of thromboembolic disease or heartworms. An interstitial pattern might indicate the presence of pulmonary parasitism or primary interstitial lung disease. Pulmonic stenosis is suspected if the pulmonic segment is enlarged. ECG findings include tall P and S waves with a right axis shift.

SPECIES

Canine

BREED

Mix

Treatment: Please refer to the chapter “Pulmonary Hypertension” for therapeutic recommendations.

SEX

Neutered Male

References:

Oyama MA, Rush JE, Rozanski EA, et al. Assessment of serum N-terminal pro-B-type natriuretic peptide concentration for differentiation of congestive heart failure from primary respiratory tract disease as the cause of respiratory signs in dogs. *J Am Vet Med Assoc* 2009;235:1319-25.

AGE

5.5

Rozanski E. Interstitial lung disease in small animals. Proceedings from American College of Veterinary Internal Medicine Forum, Denver, CO, June 15-18, 2011.

WEIGHT

69

Zoia A, Augusto M, Drigo M, Caldin M. Evaluation of hemostatic and fibrinolytic markers in dogs with ascites attributable to right-sided congestive heart failure. *J Am Vet Med Assoc* 2012;241:1336-43.

INTERPRETED BY

Eric Lindquist, DMV
DABVP, Cert. IVUSS

IMAGING PERFORMED BY

Christensen

HOSPITAL NAME

Tranquility VC

REFERRING VET

Dr. Antonelli

INVOICE

22903

DATE

6/14/23