

**PATIENT**

Stella Glueck

**PRESENTING CLINICAL SIGN**

History: Evaluate for possible foreign body, vomiting for 2-3 days. Radiographs attached.

**SPECIES**

Canine

**ULTRASONOGRAPHIC EXAMINATION OF THE ABDOMEN**

**Urinary System**

The **urinary bladder**, trigone, and pelvic urethra presented normal thicknesses and normal tone. The ureters were not visible which is normal. No uroliths or sediment were visualized and anechoic urine was present. No evidence of inflammatory or neoplastic changes was noted. Ureteral papillae were normal.

**BREED**

Bernadoodle

**SEX**

Female

The **kidneys** revealed normal size and structure, corticomedullary definition and ratio for this age. The cortices presented largely uniform texture with normal echogenic relationship to liver and spleen. Medullary structure differed distinctly from the cortex and no evidence of pelvic dilation was present. The capsules were acceptably uniform without significant irregularities. The right kidney measured 7.05 cm. The left kidney measured 6.64 cm.

**AGE**

6 months

**Adrenal Glands**

Both **adrenal glands** were visualized and recognized as having normal shape, size, position and echogenicity for this breed. The phrenic vasculature, glandular echogenicity and detail were unremarkable. Capsule, cortex, and medullary definition were normal for this age patient. The right adrenal gland measured 2.81 x 0.49 cm at the caudal pole and 0.43 cm at the cranial pole. The left adrenal gland measured 2.17 x 0.4 cm at the caudal pole and 0.44 cm at the cranial pole.

**WEIGHT**

40.8 lbs

**INTERPRETED BY**

Eric Lindquist, DMV  
DABVP, Cert. IVUSS

**Spleen**

The **spleen** presented a smooth homogeneous parenchyma hyperechoic to liver and renal cortical parenchyma. The capsule was smooth without noticeable expansion or deviation from within the spleen or adjacent pathology. The splenic vasculature demonstrated normal volume without signs of congestion or thrombosis. No sonographic evidence of acute or chronic inflammatory, neoplastic, or infarctual changes was noted.

**IMAGING PERFORMED BY**

Denise Bruno, LVT,  
RDMS

**HOSPITAL NAME**

Kenilworth AH

**Liver**

The **liver** images submitted revealed subjectively normal liver size, contour, and structure. Parenchymal echogenicity was naturally coarse and hypoechoic to the spleen. Vascular and biliary tracts were of normal volume with no evidence of congestion. The gallbladder presented acceptably thin walls with primarily anechoic content. The cystic and common bile ducts were normal. No pathological hepatic lymphadenopathy was evident. No overt structural evidence of inflammatory, infiltrative or regenerative pathology was evident.

**REFERRING VET**

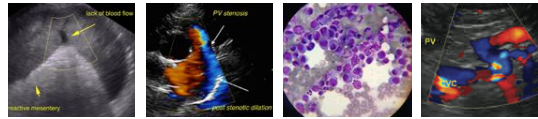
Dr. Mansour

**INVOICE**

31006

**DATE**

6/14/22



**PATIENT**

**Gastrointestinal**

Stella Glueck

The **gastrointestinal tract** revealed dilated upper gastrointestinal tract followed by empty small intestine. Shadowing foreign matter was noted and measured 3.0 cm. This is most consistent with a fabric type foreign body with a separate foreign body that measured 2.0 cm.

**SPECIES**

Canine

**Pancreas**

**BREED**

Bernadoodle

The base and limbs of the **pancreas** were observed to be largely isoechoic to surrounding omental fat. Pancreatic duct and capsular contour were acceptably normal and parenchyma respected normal curvilinear patterns. No overt evidence of active inflammatory or neoplastic disease was noted.

**SEX**

Female

**ULTRASONOGRAPHIC FINDINGS**

Intestinal foreign bodies, obstructive patterns.

**AGE**

6 months

**INTERPRETATION OF THE FINDINGS & FURTHER RECOMMENDATIONS**

Immediate exploratory surgery is warranted with GI biopsies to rule out underlying disease.

**WEIGHT**

40.8 lbs

**INTERPRETED BY**

Eric Lindquist, DMV  
 DABVP, Cert. IVUSS

**IMAGING PERFORMED BY**

Denise Bruno, LVT,  
 RDMS

**HOSPITAL NAME**

Kenilworth AH

**REFERRING VET**

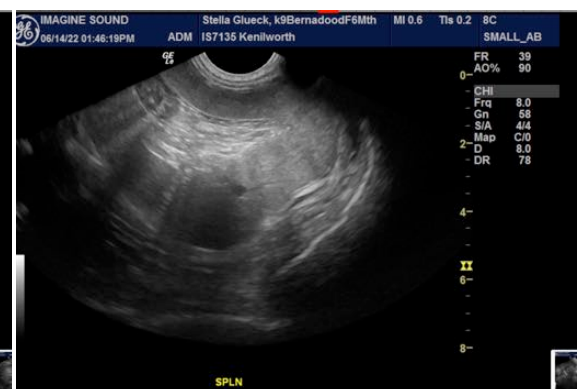
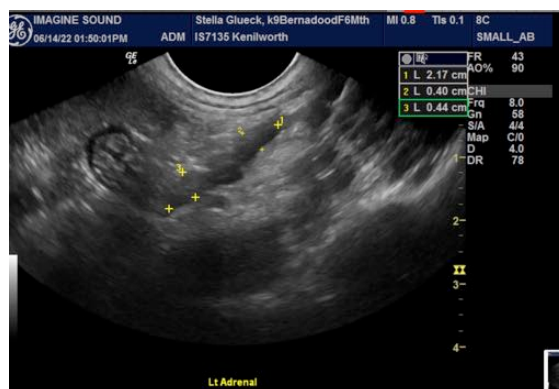
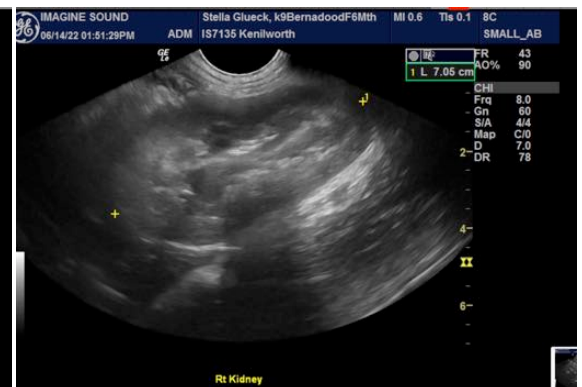
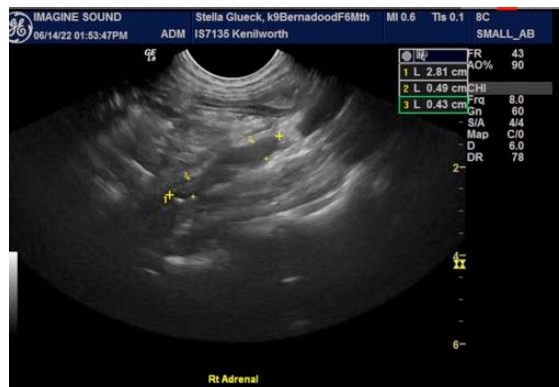
Dr. Mansour

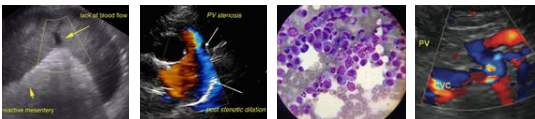
**INVOICE**

31006

**DATE**

6/14/22





**PATIENT**

Stella Glueck

**SPECIES**

Canine

**BREED**

Bernadoodle

**SEX**

Female

**AGE**

6 months

**WEIGHT**

40.8 lbs

**INTERPRETED BY**

Eric Lindquist, DMV  
DABVP, Cert. IVUSS

**IMAGING  
PERFORMED BY**

Denise Bruno, LVT,  
RDMS

**HOSPITAL NAME**

Kenilworth AH

**REFERRING VET**

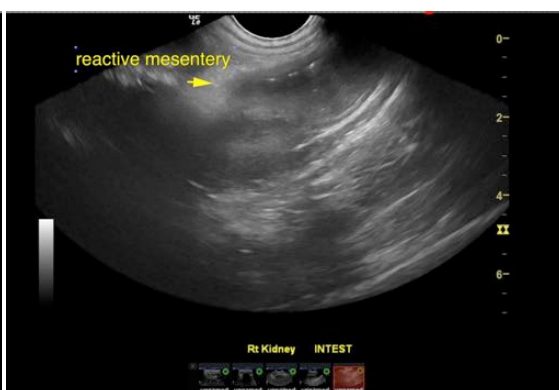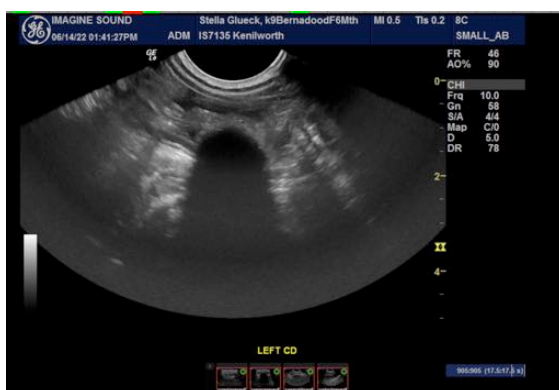
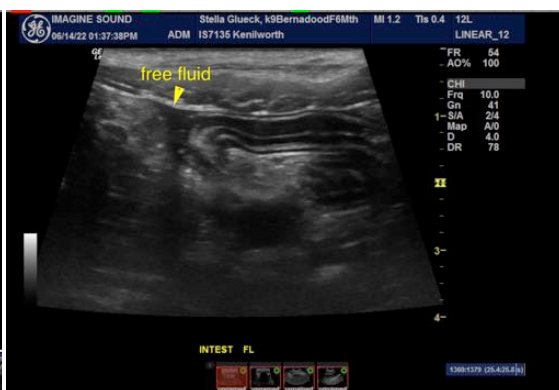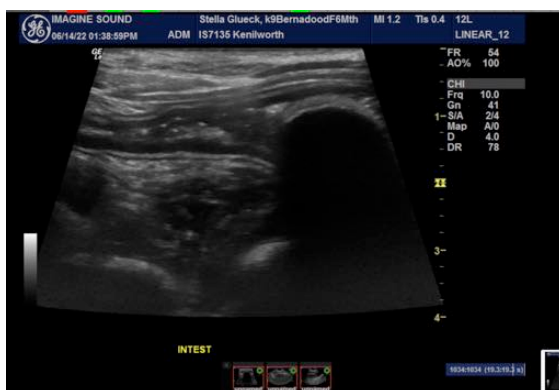
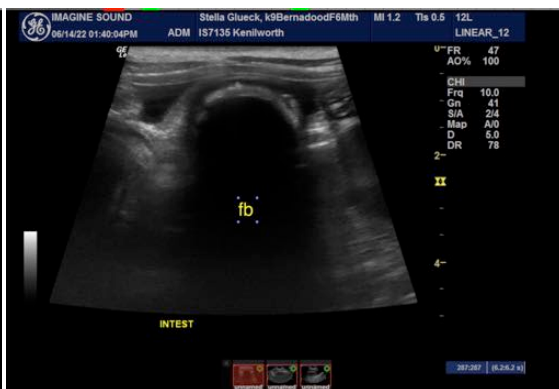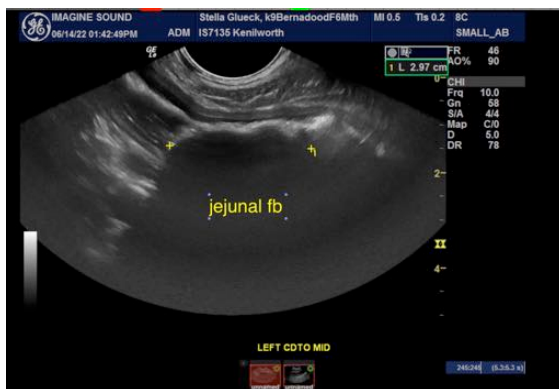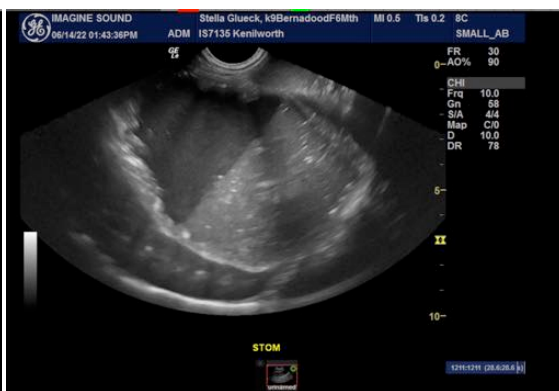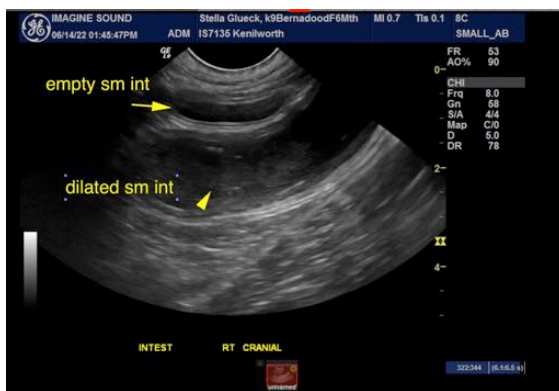Dr. Mansour

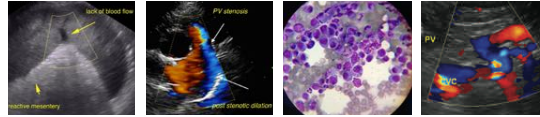
**INVOICE**

31006

**DATE**

6/14/22





**PATIENT**

Stella Glueck

The information and recommendations provided are based on the images presented by the referring veterinarian/sonographer. No evaluation can be communicated regarding pathology that was not visible in the image/video clips provided.

**SPECIES**

Canine

Thank you for this referral. If the clinical or image interpretation does not parallel your findings or if I can be of any further assistance please contact me.

**BREED**

Bernadoodle

**Eric Lindquist**, DMV, DABVP, Cert. IVUSS, CEO of SonoPath.com  
Eric.Lindquist@SonoPath.com

**SEX**

Female

**AGE**

6 months

**WEIGHT**

40.8 lbs

**INTERPRETED BY**

Eric Lindquist, DMV  
DABVP, Cert. IVUSS

**IMAGING  
PERFORMED BY**

Denise Bruno, LVT,  
RDMS

**HOSPITAL NAME**

Kenilworth AH

**REFERRING VET**

Dr. Mansour

**INVOICE**

31006

**DATE**

6/14/22