
PATIENT

Eden Duong

PRESENTING CLINICAL SIGNS

History: Follow up Echo- Pet needs anesthesia. Grade 4/6 left systolic murmur. Stage B1 MV. Blood pressure 155 mmHg. Recent vestibular event and behavior change- needs possible MRI.

SPECIES

Canine

ULTRASONOGRAPHIC EXAMINATION OF THE HEART
BREED

Chihuahua

SEX

MN

AGE

14 years

WEIGHT

13 pounds

| CANINE CARDIAC PARAMETERS | MR VMAX (m/s) | TR VMAX (m/s) | LA/AO (Boon method) | LA/AO (Heart Base; Swe) | FS (%) | EF (%) | EPSS (cm) |
|---------------------------|---------------|---------------|---------------------|-------------------------|---------------------------------|--|--|
| NORMAL PARAMETER | 4.5-5.5 | <2.7 | 1.3 | <1.3 | 28-40 | 40-100 | <0.6 |
| PATIENT | >5 | | 1.2 | 1.5 | 28 | 57 | 0.1 |
| CANINE CARDIAC PARAMETERS | HR (BPM) | AV VMAX (m/s) | PV MAX (m/s) | BODY WEIGHT (kg) | LA 2D short axis Base view (cm) | LVIDd Avg; 2D and m-mode short axis (cm) | LVIDs Avg; 2D and m-mode short axis (cm) |
| NORMAL PARAMETER | 50-100 | 0.7-1.7 | 0.7-1.6 | | | | |
| PATIENT | | 1.00 | 0.70 | | | 2.23 | |

INTERPRETED BY

 Eric Lindquist, DMV
 DABVP, Cert. IVUSS

IMAGING PERFORMED BY

Dr. Louise Mandeville

HOSPITAL NAME

BetterVet

REFERRING VET

Dr. Louise Mandeville

INVOICE

10799ag

DATE

06/14/2022

Cardiac Presentation

The echocardiogram in this patient demonstrated normal left atrial size based on 3 different LA measurement methods. Chamber volumes and echogenicity were normal. The cranial and caudal mitral valve leaflets presented vegetative thickening consistent with endocardiosis. Doppler indicated measurable insufficiency velocity measuring >5 m/s. The left ventricle presented thicknesses with linear contour and was not dilated nor restricted. The myocardium presented normal echogenicity without subjective evidence of significant fibrotic or ischemic disease. Contractility of the ventricular walls was adequate and in normal range for this patient evidenced by the fractional shortening measurement and subjective evaluation of the different regions of the myocardium. The left ventricular outflow tract demonstrated normal laminar flow and subjective structural integrity. The right atrium and auricle revealed normal size, structure and content. No evidence of masses was noted or chamber overload. Tricuspid valvular assessment demonstrated adequate linear morphology. The right ventricle was of normal size (1/3 diameter of LV), chordae structure, myocardial echogenicity and thickness. Pulmonic tract assessment revealed normal valve structure, laminar flow, and diameter (approx. 1:1 pa/ao ratio). No visible pericardial or free pleura fluid was noted. No echographically detectable evidence of infiltrative disease was visible. The cranial mediastinum and pericardial regions were free of masses in the visible window.

ULTRASONOGRAPHIC FINDINGS

- Stable Stage B1 valvular disease-no evidence of volume overload



PATIENT

Eden Duong

SPECIES

Canine

BREED

Chihuahua

SEX

MN

AGE

14 years

WEIGHT

13 pounds

INTERPRETED BY

Eric Lindquist, DMV
DABVP, Cert. IVUS

IMAGING PERFORMED BY

Dr. Louise Mandeville

HOSPITAL NAME

BetterVet

REFERRING VET

Dr. Louise Mandeville

INVOICE

10799ag

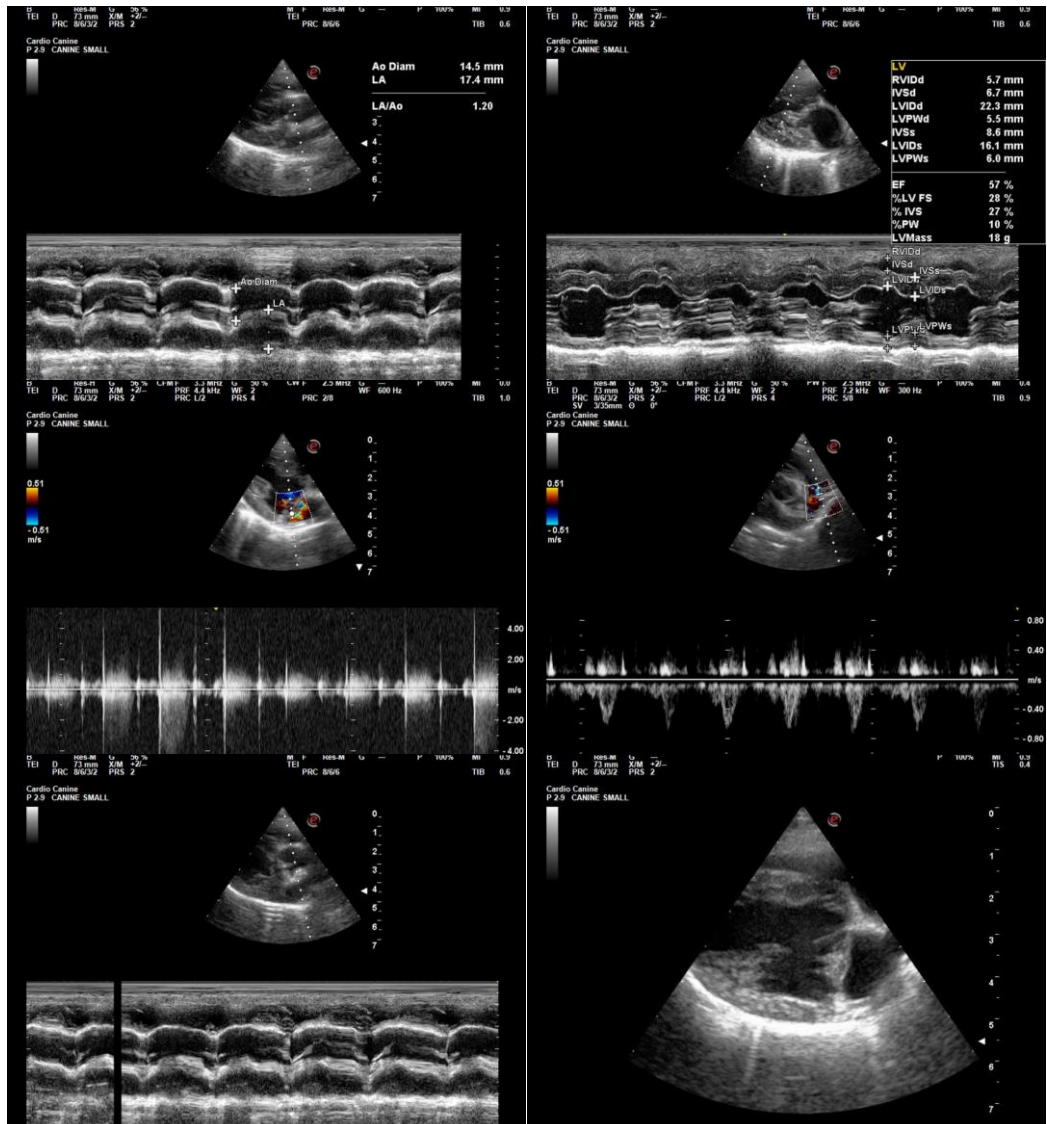
DATE

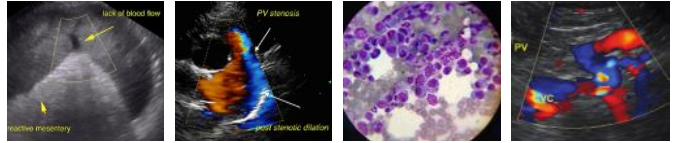
06/14/2022

INTERPRETATION OF THE FINDINGS & FURTHER RECOMMENDATIONS

No overt contraindications to anesthetic procedures for this patient.

The heart is stable without clinical disease. No overt contraindication for anesthesia of brief to moderate duration. I suggest Torbutrol premed, Propofol induction, Isoflurane maintenance or similar protocol if anesthesia is desired. Blood pressure recommended if not already performed and target white coat negative systolic pressure of < 160 mmHg. If higher than this ACE-inhibitor is suggested to reach this level. Recheck echocardiogram is recommended in 6 months, earlier if murmur grade increases or clinical signs initiate.





PATIENT

Eden Duong

SPECIES

Canine

BREED

Chihuahua

SEX

MN

AGE

14 years

WEIGHT

13 pounds

INTERPRETED BY

Eric Lindquist, DMV
DABVP, Cert. IVUSS

**IMAGING
PERFORMED BY**

Dr. Louise Mandeville

HOSPITAL NAME

BetterVet

REFERRING VET

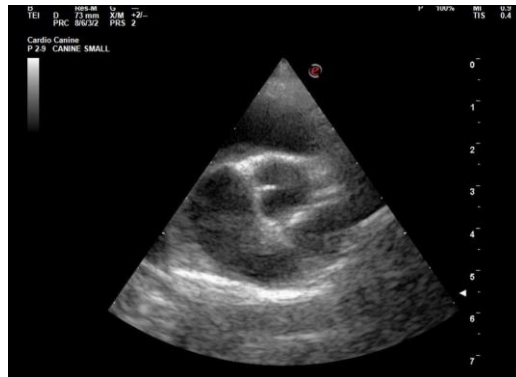Dr. Louise Mandeville

INVOICE

10799ag

DATE

06/14/2022



The information and recommendations provided are based on the images presented by the referring veterinarian. No evaluation can be communicated regarding pathology that was not visible in the image/video clips provided.

Thank you for this referral. If the clinical or image interpretation does not parallel your findings or if I can be of any further assistance please contact me.

Eric Lindquist, DMV, DABVP, Cert. IVUSS, CEO of SonoPath.com
Eric.Lindquist@SonoPath.com