



**PATIENT**

Chewie Goldman

**PRESENTING CLINICAL SIGNS**

History: lethargy fever chewed one toy up few days ago concern for fb

**SPECIES**

Canine

**ULTRASONOGRAPHIC EXAMINATION OF THE ABDOMEN**

**Urinary System**

**BREED**

Golden Mix

The **urinary bladder**, trigone, and pelvic urethra presented normal thicknesses and normal tone. The ureters were not visible which is normal. No uroliths or sediment were visualized and anechoic urine was present. No evidence of inflammatory or neoplastic changes was noted. Ureteral papillae were normal.

**SEX**

Spayed Female

The **kidneys** revealed normal size and structure, corticomedullary definition and ratio for this age. The cortices presented largely uniform texture with normal echogenic relationship to liver and spleen. Medullary structure differed distinctly from the cortex and no evidence of pelvic dilation was present. The capsules were acceptably uniform without significant irregularities. The left kidney measured 4.64 cm. The right kidney measured 5.47 cm.

**AGE**

3 years

**Adrenal Glands**

**WEIGHT**

55.5 lbs

Both **adrenal glands** were visualized and recognized as having normal shape, size, position and echogenicity for this breed. The phrenic vasculature, glandular echogenicity and detail were unremarkable. Capsule, cortex, and medullary definition were normal for this age patient. The right adrenal gland measured 2.06 x 0.65 cm at the caudal pole and 0.96 cm at the cranial pole. The left adrenal gland measured 1.4 x 0.33 cm at the caudal pole and 0.35 cm at the cranial pole.

**INTERPRETED BY**

Eric Lindquist, DMV  
DABVP, Cert. IVUSS

**Spleen**

**IMAGING PERFORMED BY**

Jenn

The **spleen** presented a smooth homogeneous parenchyma hyperechoic to liver and renal cortical parenchyma. The capsule was smooth without noticeable expansion or deviation from within the spleen or adjacent pathology. The splenic vasculature demonstrated normal volume without signs of congestion or thrombosis. No sonographic evidence of acute or chronic inflammatory, neoplastic, or infarctual changes was noted.

**HOSPITAL NAME**

Rockaway AH

**Liver**

**REFERRING VET**

Dr. Kahn

The **liver** images submitted revealed subjectively normal liver size, contour, and structure. Parenchymal echogenicity was naturally coarse and hypoechoic to the spleen. Vascular and biliary tracts were of normal volume with no evidence of congestion. The gallbladder presented acceptably thin walls with primarily anechoic content. The cystic and common bile ducts were normal. No pathological hepatic lymphadenopathy was evident. No overt structural evidence of inflammatory, infiltrative or regenerative pathology was evident.

**INVOICE**

30994

**DATE**

6/14/22



**PATIENT** *Gastrointestinal*

Chewie Goldman Examination of the **gastrointestinal tract** revealed a stomach and intestine free of stasis, of normal wall thickness, acceptable curvilinear mural detail, and peristaltic activity. Small and large intestine demonstrated normal luminal chyme and stool consistency respectively. No obstructive or overt infiltrative disease was noted. No associated abnormal lymphatic activity was noted.

**SPECIES**

Canine

**BREED**

Golden Mix

*Pancreas*

The base and limbs of the **pancreas** were observed to be largely isoechoic to surrounding omental fat. Pancreatic duct and capsular contour were acceptably normal and parenchyma respected normal curvilinear patterns. No overt evidence of active inflammatory or neoplastic disease was noted.

**SEX**

Spayed Female

**ULTRASONOGRAPHIC EXAMINATION OF THE HEART**

**AGE**

3 years

The echocardiogram in this patient demonstrated normal **left atrial** size based on 3 separate methods of LA evaluation. The cranial and caudal **mitral valve** leaflets presented normal linear structure, extension in systole, and union in diastole with normal kinesis. The **left ventricle** presented thicknesses with linear contour and was not dilated nor restricted. The **myocardium** presented normal echogenicity without subjective evidence of significant fibrotic or ischemic disease. **Contractility** of the ventricular walls was adequate and in normal range for this patient evidenced by the fractional shortening measurement and subjective evaluation of the different regions of the myocardium. The **left ventricular outflow** tract demonstrated normal laminar flow and subjective structural integrity. The **right atrium** and auricle revealed normal size, structure and content. No evidence of masses was noted. **Tricuspid** valvular assessment demonstrated adequate linear morphology and kinesis. The **right ventricle** was of normal size (1/3 diameter of LV), chordae structure, myocardial echogenicity and thickness. **Pulmonary outflow** tract assessment revealed normal valve structure, laminar flow, and diameter (approx. 1:1 pa/ao ratio). No visible **pericardial** or free pleura fluid was noted. The cranial **mediastinum and pericardial and extra-cardiac regions** were free of masses in the visible window.

**WEIGHT**

55.5 lbs

**INTERPRETED BY**

Eric Lindquist, DMV  
DABVP, Cert. IVUSS

**IMAGING PERFORMED BY**

Jenn

**HOSPITAL NAME**

Rockaway AH

**REFERRING VET**

Dr. Kahn

**INVOICE**

30994

**DATE**

6/14/22

CANINE	MR	TR	LA/AO	LA/AO	FS	EF	EPSS
<b>CARDIAC PARAMETERS</b>	<b>VMAX</b> (m/s)	<b>VMAX</b> (m/s)	(Boon method)	(Heart Base; Swe)	(%)	(%)	(cm)
<b>NORMAL PARAMETER</b>	4.5-5.5	<2.7	1.3	<1.3	28-40	40-100	<0.6
<b>PATIENT</b>			1.3	1.38			0.3
CANINE	HR	AV	PV	BODY WEIGHT	LA	LVIDd	LVIDs
<b>CARDIAC PARAMETERS</b>	(BPM)	<b>VMAX</b> (m/s)	<b>MAX</b> (m/s)		2D short axis Base view (cm)	Avg; 2D and m-mode short axis (cm)	Avg; 2D and m-mode short axis (cm)
<b>NORMAL PARAMETER</b>	50-100	0.7-1.7	0.7-1.6				
<b>PATIENT</b>		1.3	1.06	55.5 lbs	3.62	3.16	



**PATIENT**

Chewie Goldman

**SPECIES**

Canine

**BREED**

Golden Mix

**SEX**

Spayed Female

**AGE**

3 years

**WEIGHT**

55.5 lbs

**INTERPRETED BY**

Eric Lindquist, DMV  
DABVP, Cert. IVUSS

**IMAGING PERFORMED BY**

Jenn

**HOSPITAL NAME**

Rockaway AH

**REFERRING VET**

Dr. Kahn

**INVOICE**

30994

**DATE**

6/14/22

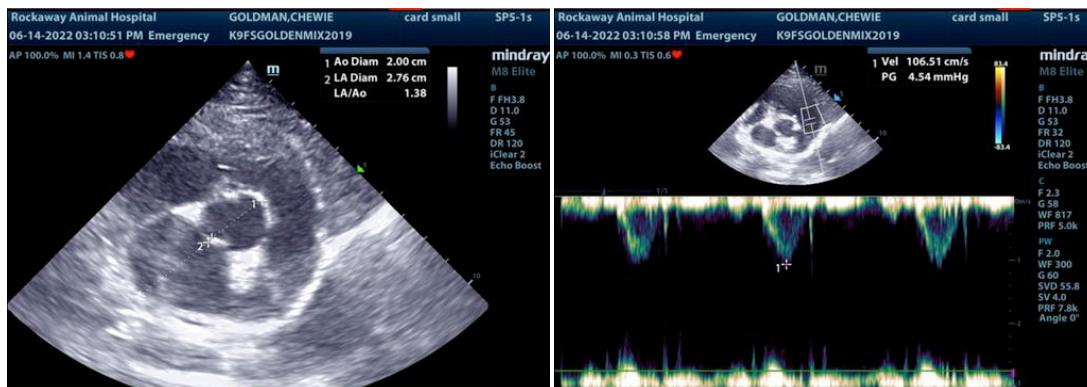
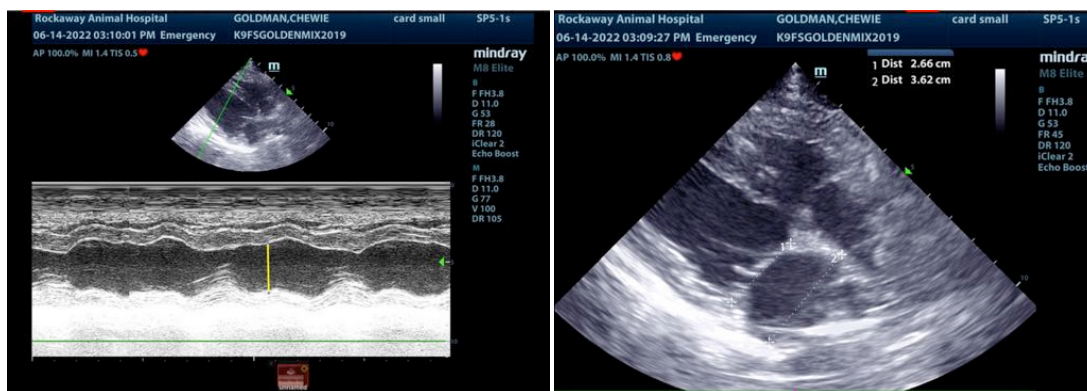
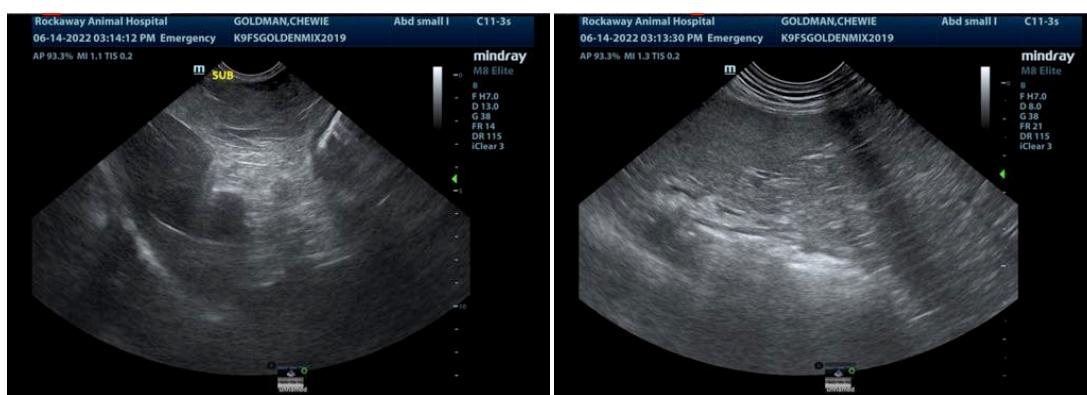
**ULTRASONOGRAPHIC FINDINGS**

Normal abdomen.

Normal echocardiogram.

**INTERPRETATION OF THE FINDINGS & FURTHER RECOMMENDATIONS**

There is no evidence of pathology.





**PATIENT**

Chewie Goldman

**SPECIES**

Canine

**BREED**

Golden Mix

**SEX**

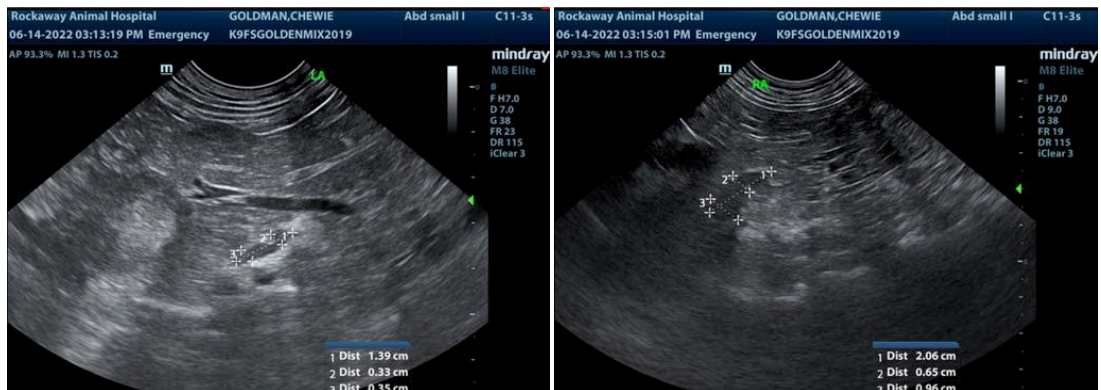
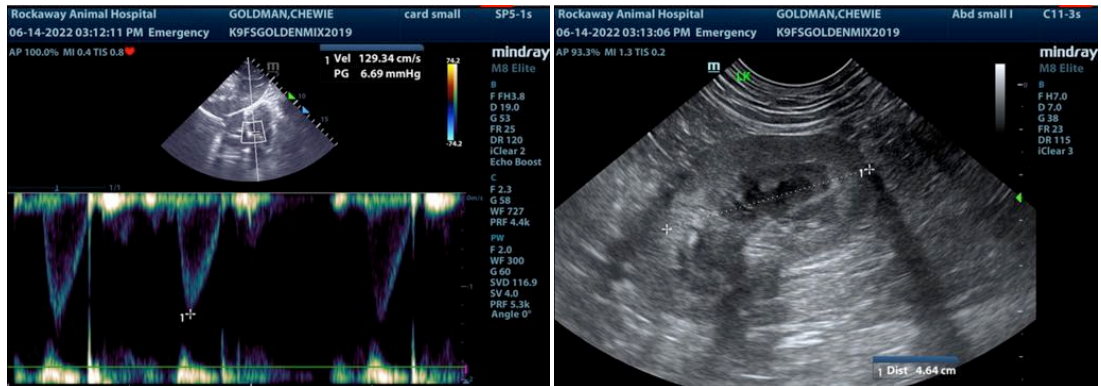
Spayed Female

**AGE**

3 years

**WEIGHT**

55.5 lbs



**INTERPRETED BY**

Eric Lindquist, DMV  
DABVP, Cert. IVUSS

**IMAGING PERFORMED BY**

Jenn

**HOSPITAL NAME**

Rockaway AH

**REFERRING VET**

Dr. Kahn

**INVOICE**

30994

**DATE**

6/14/22

The information and recommendations provided are based on the images presented by the referring veterinarian/sonographer. No evaluation can be communicated regarding pathology that was not visible in the image/video clips provided.

Thank you for this referral. If the clinical or image interpretation does not parallel your findings or if I can be of any further assistance please contact me.

Eric Lindquist, DMV, DABVP, Cert. IVUSS, CEO of SonoPath.com  
info@SonoPath.com