

**DATE**

6/14/22

PRESENTING CLINICAL SIGNS

Intermittent vomiting and diarrhea for about 6 months. Last several months picky with eating. Responds well to symptomatic treatment for short term.

Current Medications: None currently.

PATIENT

Bailey Stem

Lab Results: 6/11/2020 CBC, Chem WNL.

Date of Previous IntraPet Ultrasound: No previous.

Sedation: Not required to complete full diagnostic ultrasound.

Stat Report: Not requested.

Imaging Performed By: Rachel Brillhart, RDMS.

SPECIES

Caanine

ULTRASONOGRAPHIC EXAMINATION OF THE ABDOMEN**BREED**

Labrador

Urinary System

The **urinary bladder**, trigone, and pelvic urethra presented normal thicknesses and normal tone. The pelvic urethra was imaged 3.0 cm beyond the cystourethral junction. The ureters were not visible which is normal. No uroliths or sediment were visualized and anechoic urine was present. No evidence of inflammatory or neoplastic changes was noted. Ureteral papillae were normal.

SEX

Spayed Female

The **kidneys** revealed normal size and structure, corticomedullary definition and ratio for this age. The cortices presented largely uniform texture with normal echogenic relationship to liver and spleen. Medullary structure differed distinctly from the cortex and no evidence of pelvic dilation was present. The capsules were acceptably uniform without significant irregularities. The right kidney measured 5.75 cm. The left kidney measured 5.44 cm.

AGE

7/23/20

WEIGHT

60 lbs

Adrenal Glands

Both **adrenal glands** were visualized and recognized as having normal shape, size, position and echogenicity for this breed. The phrenic vasculature, glandular echogenicity and detail were unremarkable. Capsule, cortex, and medullary definition were normal for this age patient. The left adrenal gland measured 2.13 x 0.65 cm at the caudal pole and 0.72 cm at the cranial pole. The right adrenal gland measured 0.5 cm.

INTERPRETED BY

Eric Lindquist, DMV
DABVP, Cert. IVUSS

Spleen

The **spleen** presented a smooth homogeneous parenchyma hyperechoic to liver and renal cortical parenchyma. The capsule was smooth without noticeable expansion or deviation from within the spleen or adjacent pathology. The splenic vasculature demonstrated normal volume without signs of congestion or thrombosis. No sonographic evidence of acute or chronic inflammatory, neoplastic, or infarctual changes was noted.

HOSPITAL NAME

Hickory VH

REFERRING VET

Dr. Lyle

Liver

The **liver** images submitted revealed subjectively normal liver size, contour, and structure. Parenchymal echogenicity was naturally coarse and hypoechoic to the spleen. Vascular and biliary tracts were of normal volume with no evidence of congestion. The gallbladder presented acceptably thin walls with primarily anechoic content. The cystic and common bile ducts were normal. No pathological hepatic lymphadenopathy was evident. No overt structural evidence of inflammatory, infiltrative or regenerative pathology was evident.

INVOICE

31018

Gastrointestinal

Examination of the **gastrointestinal tract** revealed a stomach and intestine free of stasis, of normal wall thickness, acceptable curvilinear mural detail, and peristaltic activity. Intestinal wall thickness measured up

to 0.31 cm. Small and large intestine demonstrated normal luminal chyme and stool consistency respectively. The mesenteric lymph nodes were mildly enlarged and reactive measuring up to 1.12 cm.

Pancreas

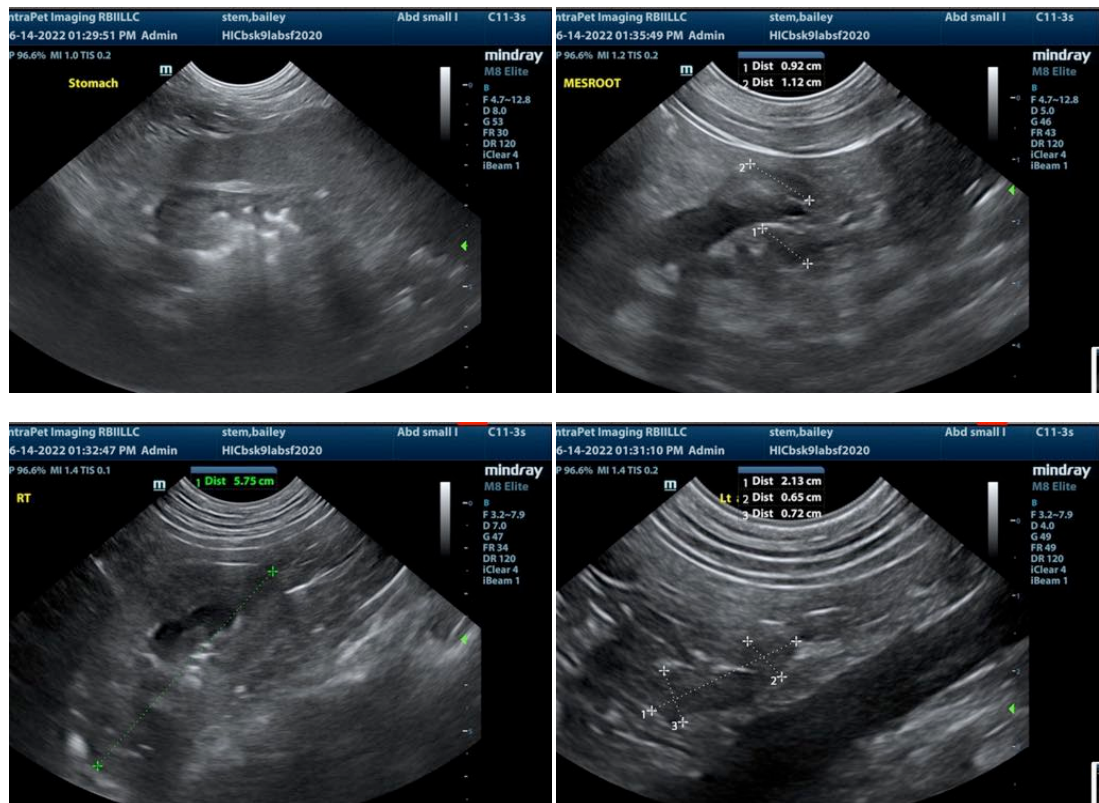
The base and limbs of the **pancreas** were observed to be largely isoechoic to surrounding omental fat. Pancreatic duct and capsular contour were acceptably normal and parenchyma respected normal curvilinear patterns. No overt evidence of active inflammatory or neoplastic disease was noted.

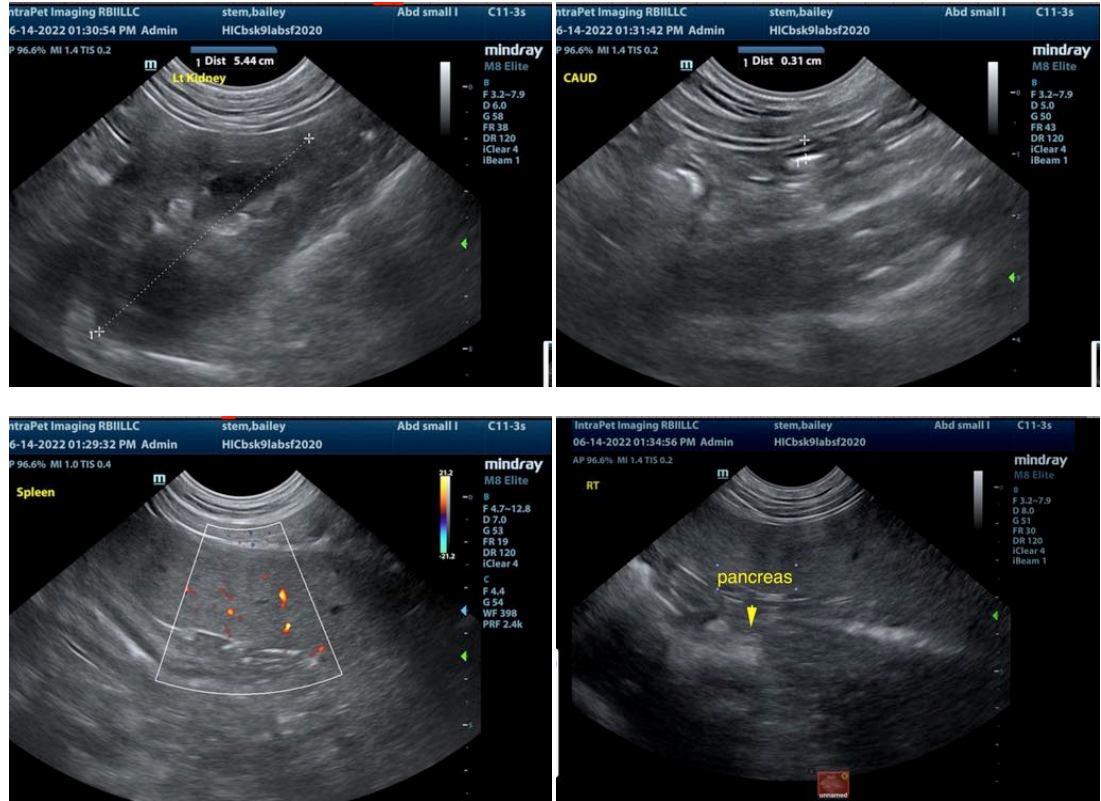
ULTRASONOGRAPHIC FINDINGS

Structurally unremarkable abdomen with minor mesenteric lymphadenopathy, likely reactive.

INTERPRETATION OF THE FINDINGS & FURTHER RECOMMENDATIONS

Occult parasitism, dietary intolerance, Helicobacter and occult Addison's are all potentials in this patient. Screening for Addison's is recommended. Broad spectrum anti-parasitic protocol and diet change to a hydrolyzed diet is all indicated +/- ultrasound-guided FNA, cytology and culture of the mesenteric lymph nodes could also be considered. There was no evidence of significant structural pathology. A hydrolyzed diet may be in this patient's best interest.





The information and recommendations provided are based on the images presented by the referring veterinarian. No evaluation can be communicated regarding pathology that was not visible in the image/video clips provided.

Thank you for this referral. If the clinical or image interpretation does not parallel your findings or if I can be of any further assistance please contact me.

Eric Lindquist, DMV, DABVP, Cert. IVUSS, CEO of SonoPath.com
Eric.Lindquist@SonoPath.com