



PATIENT

Bear Howe

SPECIES

Canine

BREED

Giant Schnauzer

SEX

Neutered Male

AGE

9 Years

WEIGHT

38 kg

INTERPRETED BY

Eric Lindquist, DMV

DABVP, Cert. IVUSS

IMAGING PERFORMED BY

Dr. Hayley Biederbeck

HOSPITAL NAME

Lomsnes Vet Hospital

REFERRING VET

Dr. Hayley Biederbeck

INVOICE

43133

DATE

6/13/23

PRESENTING CLINICAL SIGNS

Weight loss- 6kg in 1 year, unintentionally found at recent wellness exam. Has lost 0.5kg since last week. No previous bloodwork before 6/2023 when found severely elevated ALT Has been on clomicalm 40mg BID since feb 2020.

Abnormal PE/Chem/CBC/UA Results: Significant findings: Chem-AlkP 283, Chol 426 , ALT- 1456
CBC-nsf U/A- 100mg/dl proteinuria, UPC 0.82

LIMITED ULTRASONOGRAPHIC EXAMINATION

Spleen

The **spleen** was mildly enlarged, irregular and heterogeneous. Likely hyperplasia.

Liver

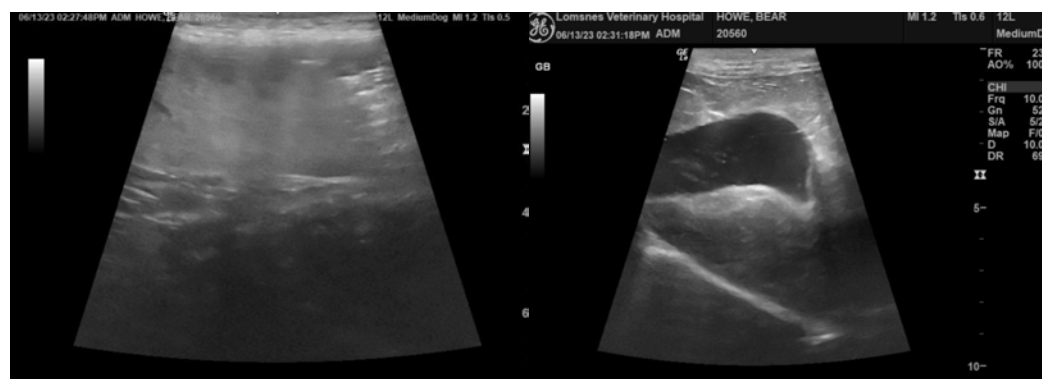
The **liver** presented diffuse coalescing hypoechoic nodular changes and irregular contour. The gallbladder and common bile duct were unremarkable. This is most consistent with hepatic cirrhosis. However, if the patient has crusting skin lesions, underlying hepatocutaneous syndrome is a potential.

ULTRASONOGRAPHIC FINDINGS

- Hepatic cirrhosis pattern with potential emerging hepatocutaneous syndrome, hypersplenism with hyperplastic pattern.
- Hypoechoic, nodular liver

INTERPRETATION OF THE FINDINGS & FURTHER RECOMMENDATIONS

Core liver biopsy and FNA of the spleen indicated. Prognosis long-term is guarded.





PATIENT

Bear Howe

SPECIES

Canine

BREED

Giant Schnauzer

SEX

Neutered Male

AGE

9 Years

WEIGHT

38 kg

INTERPRETED BY

Eric Lindquist, DMV
DABVP, Cert. IVUSS

IMAGING PERFORMED BY

Dr. Hayley Biederbeck

HOSPITAL NAME

Lomsnes Vet Hospital

REFERRING VET

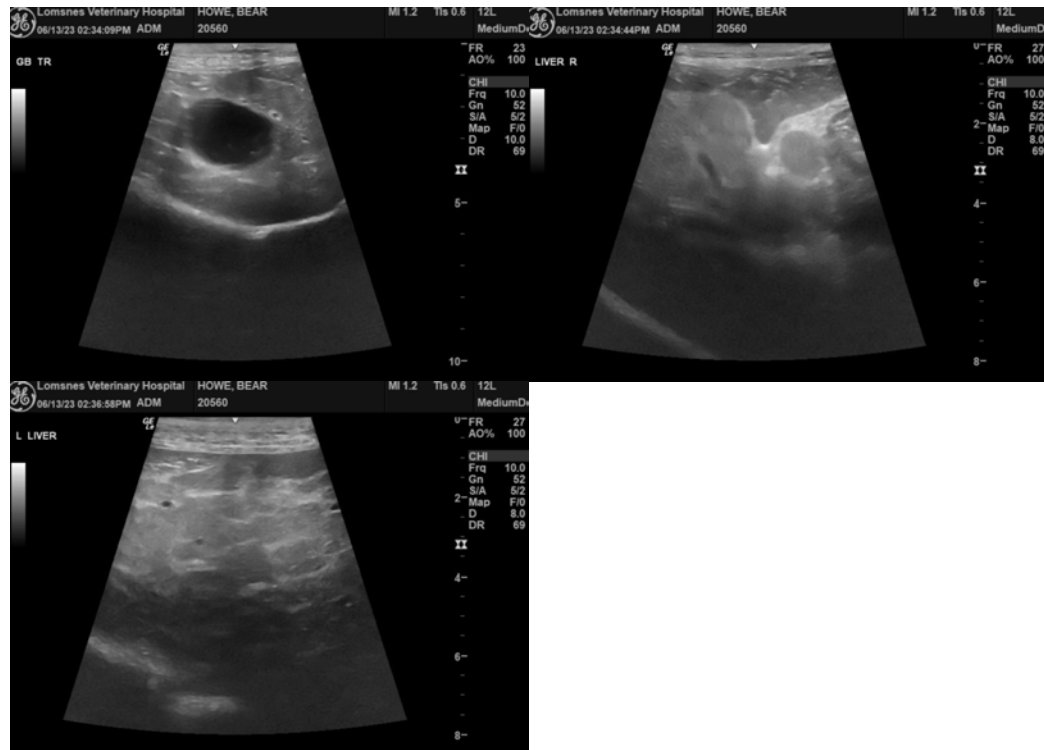
Dr. Hayley Biederbeck

INVOICE

43133

DATE

6/13/23



The information and recommendations provided are based on the images presented by the referring veterinarian/sonographer. No evaluation can be communicated regarding pathology that was not visible in the image/video clips provided.

Thank you for this referral. If the clinical or image interpretation does not parallel your findings or if I can be of any further assistance please contact me.

Eric Lindquist, DMV, DABVP, Cert. IVUSS, CEO of SonoPath.com

info@SonoPath.com