


**PATIENT**

Taffy Fyfe

**SPECIES**

Canine

**BREED**

Shih Tzu

**SEX**

FS

**AGE**

14 years

**WEIGHT**

7.7 kg

**PRESENTING CLINICAL SIGNS**

History: 3/5 murmur and chronic weight loss 2 cavity study echo 68 images Ab 65 images 133 images total Patient pants a lot and PUPD suspect Cushings Pre dental anesthetic assessment Abnormal PE/Chem/CBC/UA Results: Blood work from March non diagnostic

**ULTRASONOGRAPHIC EXAMINATION OF THE HEART AND ABDOMEN**

CANINE CARDIAC PARAMETERS	MR VMAX (m/s)	TR VMAX (m/s)	LA/AO (Boon method)	LA/AO (Heart Base; Swe)	FS (%)	EF (%)	EPSS (cm)
NORMAL PARAMETER	4.5-5.5	<2.7	1.3	<1.3	28-40	40-100	<0.6
PATIENT			1.24	1.28	55	87	0.1
CANINE CARDIAC PARAMETERS	HR (BPM)	AV VMAX (m/s)	PV MAX (m/s)	BODY WEIGHT (kg)	LA 2D short axis Base view (cm)	LVIDd Avg; 2D and m-mode short axis (cm)	LVIDs Avg; 2D and m-mode short axis (cm)
NORMAL PARAMETER	50-100	0.7-1.7	0.7-1.6				
PATIENT		1.00	1.70		2.4	2.31	

**INTERPRETED BY**

 Eric Lindquist, DMV  
 DABVP, Cert. IVUSS

**IMAGING PERFORMED BY**

Dr. Belan

**HOSPITAL NAME**

 Glamorgan Animal  
 Hospital

**REFERRING VET**

Dr. Murphy

**INVOICE**

10798ag

**DATE**

06/13/2022

**Cardiac Presentation**

The echocardiogram in this patient demonstrated normal left atrial size based on 3 different LA measurement methods. Chamber volumes and echogenicity were normal. The cranial and caudal mitral valve leaflets presented vegetative thickening consistent with endocardiosis. Doppler indicated measurable insufficiency velocity measuring 573. The left ventricle presented thicknesses with linear contour and was not dilated nor restricted. The myocardium presented normal echogenicity without subjective evidence of significant fibrotic or ischemic disease. Contractility of the ventricular walls was adequate and in normal range for this patient evidenced by the fractional shortening measurement and subjective evaluation of the different regions of the myocardium. The left ventricular outflow tract demonstrated normal laminar flow and subjective structural integrity. The right atrium and auricle revealed normal size, structure and content. No evidence of masses was noted or chamber overload. Tricuspid valvular assessment demonstrated adequate linear morphology. The right ventricle was of normal size (1/3 diameter of LV), chordae structure, myocardial echogenicity and thickness. Pulmonic tract assessment revealed normal valve structure, laminar flow, and diameter (approx.1:1 pa/ao ratio). No visible pericardial or free pleura fluid was noted. No echographically detectable evidence of infiltrative disease was visible. The cranial mediastinum and pericardial regions were free of masses in the visible window.

**Urinary System**

The urinary bladder presented a relatively uniform moderate thickening of the cranioventral and craniodorsal mucosae with micropolypoid mucosal changes without involvement of the submucosae. A minimal amount of urine was present at the time of the study. The urine presented some



**PATIENT**

Taffy Fyfe

echogenicity consistent with suspended debris. No evidence of urethral pathology was present. This presentation is most consistent with moderate chronic cystitis. Technically transitional cell carcinoma cannot be ruled out without histopathological review but is not overtly suspected based on this pattern. Cystocentesis and urine culture +/- pathological review of urine cytology would be warranted. No overt calculi were present at this time.

**SPECIES**

Canine

The kidneys revealed largely normal size and structure, corticomedullary definition and ratio (cortex 1/3 of medulla) were essentially maintained with some moderate age-related loss of curvilinear patterns regarding the capsule and C/M junction. The cortices presented largely uniform texture with some increased echogenicity expected for his age patient. Medullary structure differed distinctly from that of the cortex and no evidence of pelvic dilation was present.

**BREED**

Shih Tzu

The left kidney measured 4.67 cm in length. The right kidney measured 3.56 cm in length.

**SEX**

**Adrenal Glands**

FS

The right adrenal gland presented enlarged, irregular and rounded. The right adrenal gland measured 1.89 cm with loss of structural detail and capsular expansion without capsular escape.

**AGE**

14 years

The left adrenal gland presented enlarged, nodular and irregular. The left adrenal gland measured 1.85 cm caudal pole width by 1.08 cm cranial pole width.

**Spleen**

**WEIGHT**

7.7 kg

The spleen was largely smooth with moderate heterogeneous parenchymal changes while maintaining normal echogenic relationship to the liver and kidney. These changes are consistent with normal age-related alteration. The capsule was smooth without noticeable impingement from within the spleen or from pathology in the adjacent abdomen. The splenic vasculature demonstrated normal volume without signs of congestion or significant contraction. No evidence of active acute or chronic inflammatory, neoplastic, or infarctual changes were noted.

**INTERPRETED BY**

Eric Lindquist, DMV  
DABVP, Cert. IVUSS

**Liver**

**IMAGING PERFORMED BY**

Dr. Belan

The liver images from right and left intercostal as well as subcostal views revealed subjectively normal liver size, contour, and structure. Moderate age-related parenchymal remodeling was noted but likely not clinically significant at this time. Occasional hypoechoic nodules were present measuring up to 0.67 cm. Vascular and biliary tracts were of normal volume and no evidence of congestion was noted. The gallbladder presented some dependent debris with essentially normal contour. Minor gallbladder polyps were noted. The cystic and common bile ducts were normal. No overt evidence of active inflammatory, infiltrative or regenerative pathology was noted but should be paired with current or past LE elevations regarding any clinical significance to this presentation. The hepatic lymph nodes were unremarkable.

**HOSPITAL NAME**

Glamorgan Animal  
Hospital

**REFERRING VET**

Dr. Murphy

**Gastrointestinal**

Examination of the gastrointestinal tract revealed a stomach and intestine free of stasis, of normal wall thickness, acceptable curvilinear mural detail, and peristaltic activity. Small and large intestine demonstrated normal luminal chyme and stool consistency respectively. No obstructive or overt infiltrative disease was noted. No associated abnormal lymphatic activity was noted.

**INVOICE**

10798ag

**Pancreas**

**DATE**

06/13/2022

The base and limbs of the pancreas were observed to be largely isoechoic to surrounding omental fat. Mild parenchymal remodeling, however, with mild deviation from curvilinear normalcy was observed.



**PATIENT**

Taffy Fyfe

Heterogeneous ill defined changes were noted at the left and right base of the pancreas. Pancreatic duct and capsular irregularities were present consistent with age related changes. If pain upon imaging (+ Murphy sign) was present or if the patient is focally painful in subxiphoid palpation then low-grade smoldering chronic pancreatitis should be suspected.

**SPECIES**

Canine

**ULTRASONOGRAPHIC FINDINGS**

**BREED**

Shih Tzu

- Stage B1 valvular disease
- Bilateral adrenal enlargement/mass effect-benign myelolipoma, adenoma, adenocarcinoma or pheochromocytoma possible
- Moderate degenerative renal changes
- Chronic cystitis bladder pattern
- Mild pancreatic and hepatic remodeling

**SEX**

FS

**INTERPRETATION OF THE FINDINGS & FURTHER RECOMMENDATIONS**

**AGE**

14 years

Blood pressure measurements are recommended to rule out systemic hypertension. Structurally the heart does not have any overt contraindications for anesthetic procedures, however systemic hypertension should be ruled out. A full CNS examination is warranted. If the sonographer is comfortable with it, an ultrasound guided FNA of both adrenal glands could be considered assuming normal clotting status and using a 25g needle.

**WEIGHT**

7.7 kg

BP measurements and full adrenal workup warranted for this patient.

**Efficient & Accurate Cushing's Work up-Lindquist**

**INTERPRETED BY**

Eric Lindquist, DMV  
DABVP, Cert. IVUSS

**Notes regarding Cushing's Clinical Presentations:**

*Nearly all Cushing's dogs have SAP elevations and true PU/PD (USG < 1.025) and most are polyphagic. Cushing's dogs are > 6 years and usually > 9 years old, usually have poor skin coats, body scores > 3/5, and are usually sedentary animals.*

*Its important to remember that Cushing's dogs usually look and play the part and other diseases cause false + stress related cortisol spikes. On rare occasion a Cushing's dog will not follow the rules but this is truly an exception.*

*Potential Cushing's patient workups can be costly and frustrating if not definitive and, in my experience, the non-definitive patient usually has something else going on that may be contributing to some of the clinical signs a Cushing's dog will have, especially SAP elevations or PU/PD. Based on this prelude of information I came up with the following algorithm in the spirit of diagnostic efficiency.*

*The following suggested protocol is based on current available literature on Cushing's disease and extensive clinical-sonographic experience evaluation + Cushing's and False + LDDST & ACTH stim. cases in order to maximize the efficiency of a Cushing's workup in practice.*

**IMAGING PERFORMED BY**

Dr. Belan

**HOSPITAL NAME**

Glamorgan Animal  
Hospital

**REFERRING VET**

Dr. Murphy

**Screen first, workup second**

1) **UA:** Repeatable (2-3 urine samples) Urine specific gravity & urine cortisol/creatinine ratio (UCCR): If **repeatable USG < 10.20 and + UCCR** move to next step 2.

**INVOICE**

10798ag

*Note: UA is inexpensive and easy to obtain and if UA criteria is not met for Cushing's then resources can be spent into other more pertinent diagnostics or left on hold until the UA criteria is met in emerging Cushing's cases.*

**DATE**

06/13/2022



**PATIENT**

Taffy Fyfe

**SPECIES**

Canine

**BREED**

Shih Tzu

**SEX**

FS

**AGE**

14 years

**WEIGHT**

7.7 kg

**INTERPRETED BY**

Eric Lindquist, DMV  
DABVP, Cert. IVUSS

**IMAGING PERFORMED BY**

Dr. Belan

**HOSPITAL NAME**

Glamorgam Animal  
Hospital

**REFERRING VET**

Dr. Murphy

**INVOICE**

10798ag

**DATE**

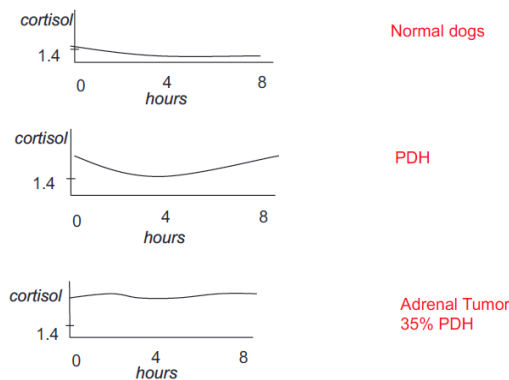
06/13/2022

2) **Sonogram:** Does the patient **have concurrent disease** clinically or sonographically as non-Cushing's illness will influence the potential false + LDDST or even ACTH stim. The sonogram gives a global perspective of the internal health of the patient to be considered in the Cushing's workup as an assessment of concurrent disease. Is there a concurrent neoplastic process, UTI pancreatitis, mucocele....? Are the adrenals enlarged (Cushing's-PDH, stress, age related or breed variant), or atrophied (iatrogenic Cushing's or adrenal burnout), have asymmetric enlargement (Adrenal tumor, hyperplasia, adenoma, age related variant), or is there vascular invasion (Invasive pheo with false + UA criteria or adenocarcinoma or phrenic thrombosis)? The sonogram answers these questions proactively.

**Address & treat concurrent disease first before performing Cushing's testing or testing will be artificially altered increasing false negatives and positives.**

3) **LDDST** (0.01 D-Sodium phosphate mg/kg IV **with precise dosing\*\*\*\***) (Better screening test but plagued with false + but considered more specific than ACTH stim) Use if there is potential early Cushing's or if adrenal asymmetry present on sonogram suspecting tumor. Use LDDST in cats at a higher dose (0.1 mg/kg IV). **Interpretation LDDST:** Look at 8-hour post first: If > 1.4 = Cushing's. Then look at 4-hour: if > 1.4 or > 50% baseline = Cushing's. 4-hour do then 8-hour spike most consistent with PDH. Flat line high constant curve without dip more consistent with tumor but can be PDH. See attached graph.

**LDDS**

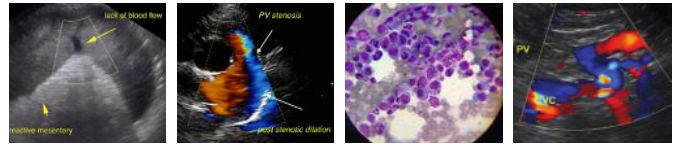


Courtesy: Rebecca Berg DACVIM, DECVIM

4) **ACTH stim.** (Better confirming test but can have false +) Use if the patient "looks" Cushingoid or if bilateral adrenal enlargement is present, or high normal width on sonogram, or if iatrogenic Cushing's suspected (Cortisone Tx in past). ACTH stim is better for diagnosis of Addison's, iatrogenic Cushing's, and Cushing's therapy monitoring but problematic with initial Cushing's diagnosis. First dx LDDST is suggested.

5) If **diabetic** then run both LDDST & ACTH stim but stabilize as much as possible first.

5) Run a **serial blood pressure** in a BP friendly non "white coat effect" atmosphere. Run at least 3 at different times over a few hours or when eating as the patient tends to be calm when eating or give Torbutrol when entering the facility. Cushing's hypertension is usually 150-180 systolic range while pheochromocytoma range is more often > 180 systolic.



**PATIENT**

Taffy Fyfe

6) **Perform CT** of the pituitary to identify macro adenoma expansion if any lethargy or dullness or other central clinical CNS signs are minimally present. CT for adrenal may be more thorough for adrenalectomy surgical planning if ultrasound views of the CVC were problematic.

**SPECIES**

Canine

7) **Adrenectomy** for adrenal mass is prescribed then it is essential to stabilize the patient first regarding secondary disease such as organ dysfunction, hypertension, diabetes mellitus, hypernatremia, thromboembolic risk urinary and other infection in order to minimize potential for operative and postoperative complications as they are common in adrenalectomy. Trilostane stabilization therapy for Cushing's would be the first approach then address surgery and hypertension should be managed ideally < 160 systolic with ace inhibitors, phenoxybenzamine, or amlodipine.

**BREED**

Shih Tzu

Suggested reading:

**SEX**

FS

Behrend EN, Kooistra HS, Nelson R, et al. Diagnosis of Spontaneous Canine Hyperadrenocorticism: 2012 ACVIM Consensus Statement (Small Animal). J Vet Intern Med 2013;27:1292-1304 .

**AGE**

14 years

Moderate degenerative renal changes and concern for renal failure in this patients near future depending upon recent bloodwork and UA findings. Subjectively the kidneys appear approximately 50-60% compromised.

**WEIGHT**

7.7 kg

Maldigestion panel, three view chest radiographs and full CNS examination is recommended to examine for occult disease that could be responsible for the weight loss. Evaluation for competitive eating environments should also be considered.

**INTERPRETED BY**

Eric Lindquist, DMV  
DABVP, Cert. IVUSS

**IMAGING PERFORMED BY**  
Dr. Belan

**HOSPITAL NAME**

Glamorgan Animal  
Hospital

**REFERRING VET**

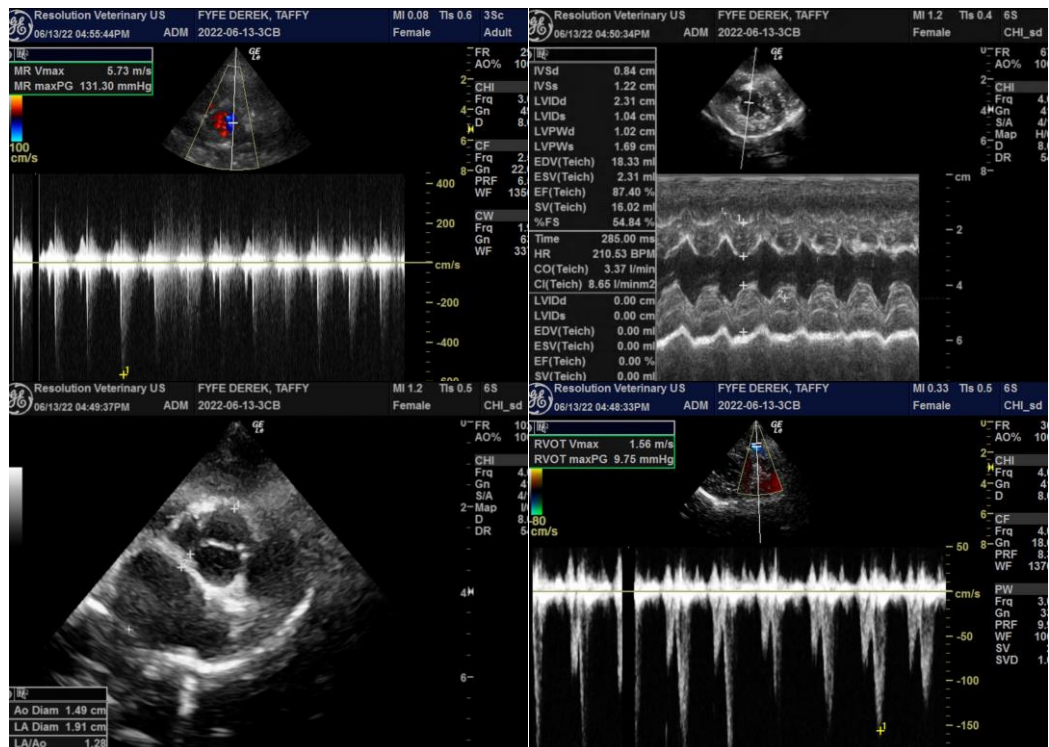
Dr. Murphy

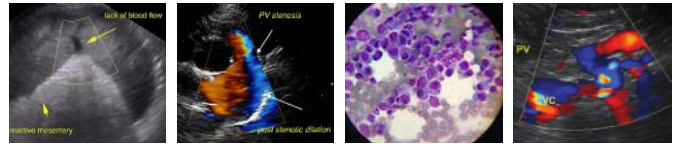
**INVOICE**

10798ag

**DATE**

06/13/2022





**PATIENT**

Taffy Fyfe

**SPECIES**

Canine

**BREED**

Shih Tzu

**SEX**

FS

**AGE**

14 years

**WEIGHT**

7.7 kg

**INTERPRETED BY**

Eric Lindquist, DMV  
DABVP, Cert. IVUSS

**IMAGING PERFORMED BY**

Dr. Belan

**HOSPITAL NAME**

Glamorgam Animal  
Hospital

**REFERRING VET**

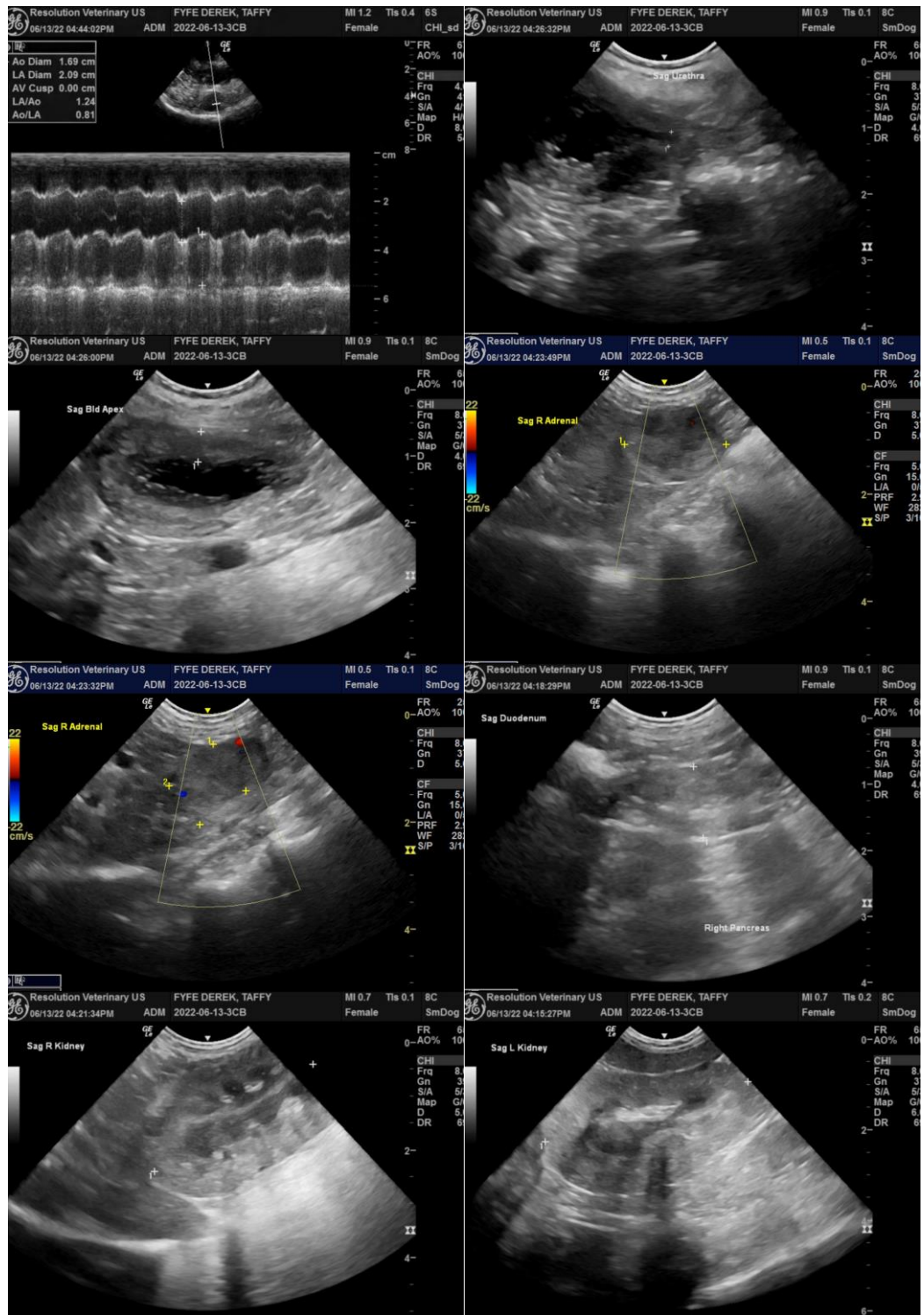
Dr. Murphy

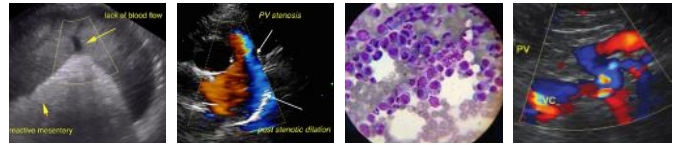
**INVOICE**

10798ag

**DATE**

06/13/2022





**PATIENT**

Taffy Fyfe

**SPECIES**

Canine

**BREED**

Shih Tzu

**SEX**

FS

**AGE**

14 years

**WEIGHT**

7.7 kg

**INTERPRETED BY**

Eric Lindquist, DMV  
DABVP, Cert. IVUSS

**IMAGING PERFORMED BY**

Dr. Belan

**HOSPITAL NAME**

Glamorgan Animal  
Hospital

**REFERRING VET**

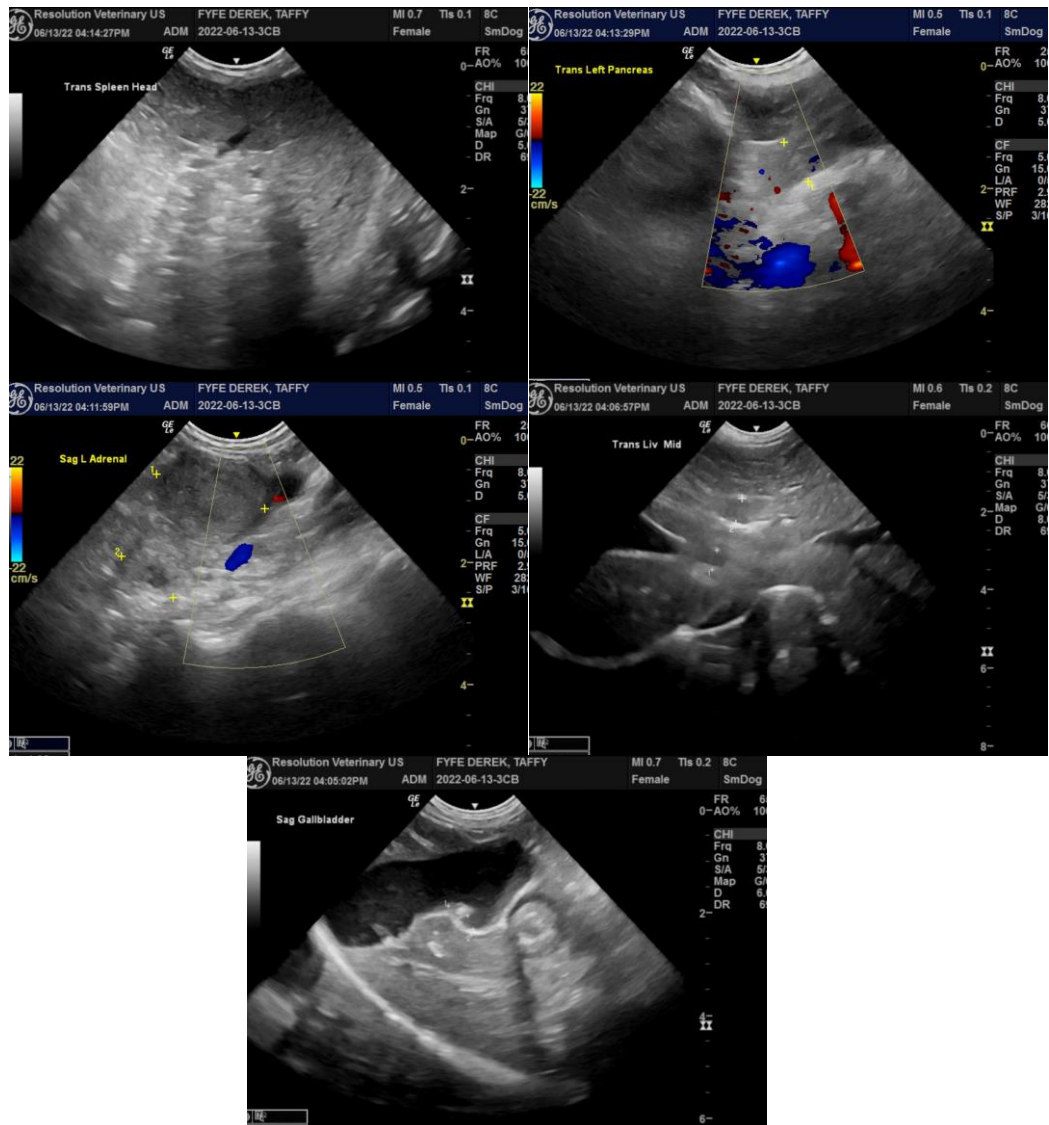
Dr. Murphy

**INVOICE**

10798ag

**DATE**

06/13/2022



The information and recommendations provided are based on the images presented by the referring veterinarian. No evaluation can be communicated regarding pathology that was not visible in the image/video clips provided.

Thank you for this referral. If the clinical or image interpretation does not parallel your findings or if I can be of any further assistance please contact me.

**Eric Lindquist, DMV, DABVP, Cert. IVUSS, CEO of SonoPath.com**  
Eric.Lindquist@SonoPath.com