



PATIENT

Tilly Humphries

SPECIES

Canine

BREED

Shih Tzu

SEX

Spayed Female

AGE

17 Years

WEIGHT

9 Pounds

INTERPRETED BY

Eric Lindquist, DMV
DABVP, Cert. IVUSS

IMAGING PERFORMED BY

Lynette Reyes

HOSPITAL NAME

Mobile Vet Ultrasound

REFERRING VET

Dr. Steven D' Ambrose

INVOICE

16030

DATE

6/11/22

PRESENTING CLINICAL SIGNS

History: Screening ultrasound prior to oncologist consult due to Fibrosarcoma vs nerve sheath tumor on lower R lip area.

Abnormal PE/Chem/CBC/UA Results: Nsf

ULTRASONOGRAPHIC EXAMINATION OF THE ABDOMEN

Urinary System

The **urinary bladder**, trigone, and pelvic urethra presented normal thicknesses and normal tone. The ureters were not visible which is normal. No uroliths or sediment were visualized, and anechoic urine was present. No evidence of inflammatory or neoplastic changes were noted. Ureteral papillae were normal.

The **kidneys** revealed largely normal size and structure, corticomedullary definition and ratio (cortex 1/3 of medulla) were essentially maintained with some moderate age-related loss of curvilinear patterns regarding the capsule and C/M junction. The cortices presented largely uniform texture with some increased echogenicity expected for his age patient. Medullary structure differed distinctly from that of the cortex. Trace pyelectasia was noted in the right kidney. Slight mineralization was noted, nonobstructive. Both kidneys measured 3.7 cm.

Adrenal Glands

Both **adrenal glands** were visualized and recognized as having normal shape, size, position and echogenicity for this breed. The phrenic vasculature, glandular echogenicity and detail were unremarkable. Capsule, cortex, and medullary definition were normal for this age patient. The left adrenal gland measured 0.4 cm. The right adrenal gland measured 0.6 cm at the cranial pole and 0.4 cm at the caudal pole.

Spleen

The **spleen** presented a smooth homogeneous parenchyma hyperechoic to liver and renal cortical parenchyma. The capsule was smooth without noticeable expansion or deviation from within the spleen or adjacent pathology. The splenic vasculature demonstrated normal volume without signs of congestion or thrombosis. No sonographic evidence of acute or chronic inflammatory, neoplastic, or infarctual changes were noted.

Liver

The **liver** images from right and left intercostal as well as subcostal views revealed subjectively normal liver size, contour, and structure. Some moderate age-related parenchymal remodeling was noted but likely not clinically significant at this time. Vascular and biliary tracts were of normal volume and no evidence of congestion was noted. The gallbladder presented some dependent debris with essentially normal contour. The cystic and common bile ducts were normal. No overt evidence of active inflammatory, infiltrative or regenerative pathology was noted but should be paired with current or past LE elevations regarding any clinical significance to this presentation. The hepatic lymph nodes were unremarkable.

Gastrointestinal



PATIENT

Tilly Humphries

Examination of the **gastrointestinal tract** revealed a stomach and intestine free of stasis, of normal wall thickness, acceptable curvilinear mural detail, and peristaltic activity. Small and large intestine demonstrated normal luminal chyme and stool consistency respectively. No obstructive or overt infiltrative disease was noted. No associated abnormal lymphatic activity was noted.

SPECIES

Canine

Pancreas

The base and limbs of the **pancreas** were observed to be largely isoechoic to surrounding omental fat. Pancreatic duct and capsular contour were acceptably normal and parenchyma respected normal curvilinear patterns. No overt evidence of active inflammatory or neoplastic disease was noted.

BREED

Shih Tzu

ULTRASONOGRAPHIC FINDINGS

SEX

- Geriatric abdomen
- Moderate degenerative renal and hepatic changes

Spayed Female

INTERPRETATION OF THE FINDINGS & FURTHER RECOMMENDATIONS

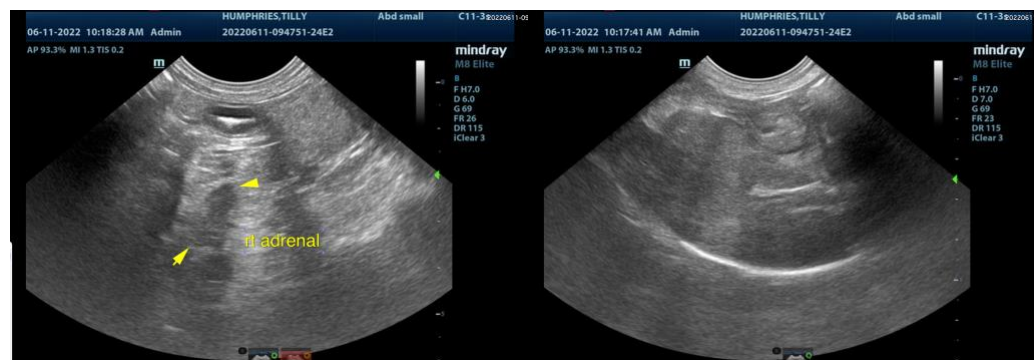
AGE

No evidence of metastatic disease.

17 Years

WEIGHT

9 Pounds

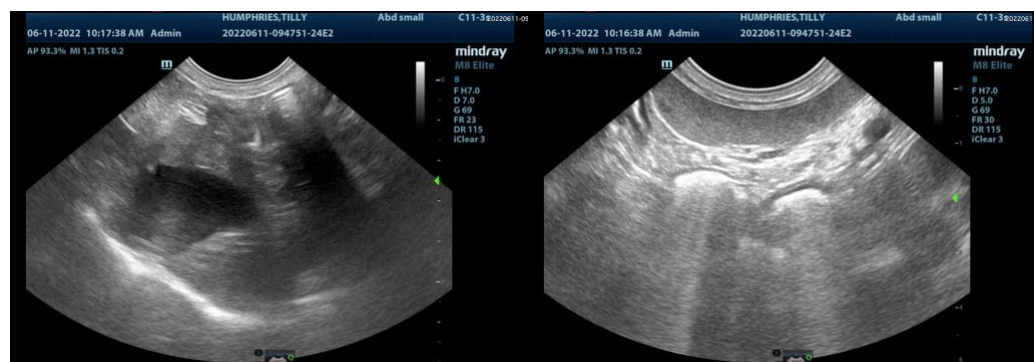


INTERPRETED BY

Eric Lindquist, DMV
DABVP, Cert. IVUSS

IMAGING PERFORMED BY

Lynette Reyes



HOSPITAL NAME

Mobile Vet Ultrasound

REFERRING VET

Dr. Steven D' Ambrose

INVOICE

16030

DATE

6/11/22



PATIENT

Tilly Humphries

SPECIES

Canine

BREED

Shih Tzu

SEX

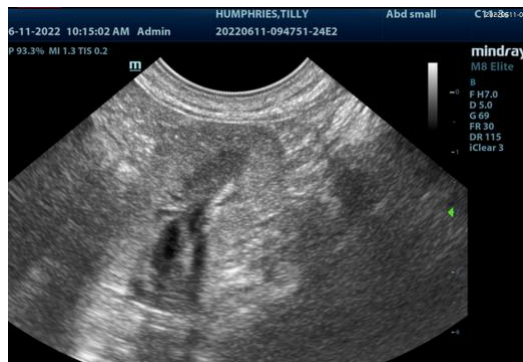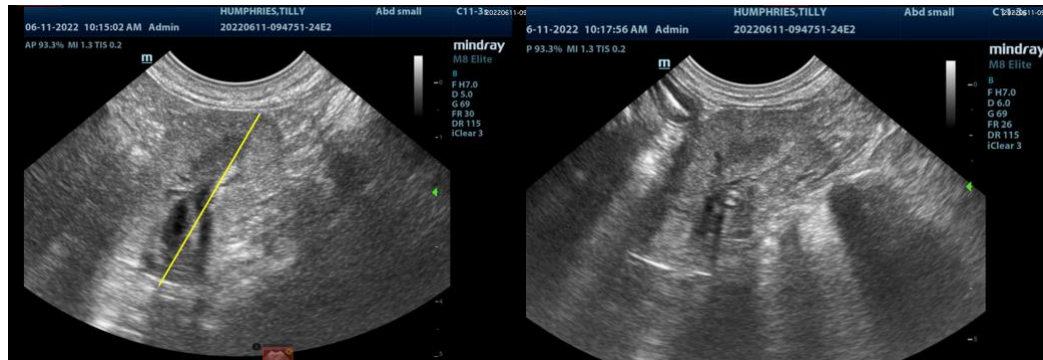Spayed Female

AGE

17 Years

WEIGHT

9 Pounds



INTERPRETED BY

Eric Lindquist, DMV
DABVP, Cert. IVUSS

IMAGING PERFORMED BY

Lynette Reyes

HOSPITAL NAME

Mobile Vet Ultrasound

REFERRING VET

Dr. Steven D' Ambrose

INVOICE

16030

DATE

6/11/22

The information and recommendations provided are based on the images presented by the referring veterinarian. No evaluation can be communicated regarding pathology that was not visible in the image/video clips provided.

Thank you for this referral. If the clinical or image interpretation does not parallel your findings or if I can be of any further assistance please contact me.

Eric Lindquist, DMV, DABVP, Cert. IVUSS, CEO of SonoPath.com
info@SonoPath.com