



**PATIENT**

Sparta B Kitty  
Greenawalt

**SPECIES**

Feline

**BREED**

DMH

**SEX**

Neutered Male

**AGE**

14 Years

**WEIGHT**

8.9 Pounds

**INTERPRETED BY**

Eric Lindquist, DMV  
DABVP, Cert. IVUSS

**IMAGING  
PERFORMED BY**

Jack Reese

**HOSPITAL NAME**

Willow Run VC

**REFERRING VET**

Molly Arnold, DVM

**INVOICE**

16033

**DATE**

6/11/22

**PRESENTING CLINICAL SIGNS**

History: Hyperthyroid - treated with radioactive iodine therapy and did well following treatment (~18 months ago). Owner reports on/off gastrointestinal symptoms and weight loss at home. Seems restless at night, decreased interest in dry food.

Abnormal PE/Chem/CBC/UA Results: SDMA 15 (0-14) BUN 24 (16-37) Creatinine 2.2 (0.9-2.3) All other values within normal limits

**ULTRASONOGRAPHIC EXAMINATION OF THE ABDOMEN**

**Urinary System**

The **urinary bladder**, trigone, and pelvic urethra presented normal thicknesses and normal tone. The ureters were not visible which is normal. No uroliths or sediment were visualized, and anechoic urine was present. No evidence of inflammatory or neoplastic changes were noted. Ureteral papillae were normal.

The **kidneys** presented a relatively uniform cortical hyperechogenicity when compared to the renal medulla, spleen and liver. No overt masses were noted. Corticomedullary definition was nebulous, and the ratio favored the cortex slightly. The ureters were not visible and assumed to be normal. These changes are most consistent with chronic interstitial nephritis yet infiltrative disease could not be entirely ruled out without biopsy though neoplasia is not suspected. This is a moderate change. The right kidney measured 3.7 cm. The left kidney measured 3.6 cm.

**Adrenal Glands**

Both **adrenal glands** were visualized and recognized as having normal shape, size, position and echogenicity for this breed. The phrenic vasculature, glandular echogenicity and detail were unremarkable. Capsule, cortex, and medullary definition were normal for this age patient. The left adrenal gland measured 0.3 cm. The right adrenal gland measured 0.3 cm.

**Spleen**

The **spleen** presented a smooth homogeneous parenchyma hyperechoic to liver and renal cortical parenchyma. The capsule was smooth without noticeable expansion or deviation from within the spleen or adjacent pathology. The splenic vasculature demonstrated normal volume without signs of congestion or thrombosis. No sonographic evidence of acute or chronic inflammatory, neoplastic, or infarctual changes were noted.

**Liver**

The **liver** images from right and left intercostal as well as subcostal views revealed subjectively normal liver size, contour, and structure. Some minor age-related parenchymal remodeling was noted but likely not clinically significant at this time. Vascular and biliary tracts were of normal volume and no evidence of congestion was noted. The gallbladder presented some dependent debris with essentially normal contour. The cystic and common bile ducts were normal. No overt evidence of active inflammatory, infiltrative or regenerative pathology was noted but should be paired with current or past LE elevations regarding any clinical significance to this presentation. The hepatic lymph nodes were unremarkable.

**Gastrointestinal**



## PATIENT

Sparta B Kitty  
Greenawalt

## SPECIES

Feline

## BREED

DMH

## SEX

Neutered Male

## AGE

14 Years

## WEIGHT

8.9 Pounds

## INTERPRETED BY

Eric Lindquist, DMV  
DABVP, Cert. IVUSS

## IMAGING PERFORMED BY

Jack Reese

## HOSPITAL NAME

Willow Run VC

## REFERRING VET

Molly Arnold, DVM

## INVOICE

16033

## DATE

6/11/22

Examination of the **gastrointestinal tract** revealed a stomach and intestine free of stasis, of normal wall thickness, acceptable curvilinear mural detail, and peristaltic activity. Small and large intestine demonstrated normal luminal chyme and stool consistency respectively. No obstructive or overt infiltrative disease was noted. No associated abnormal lymphatic activity was noted.

## Pancreas

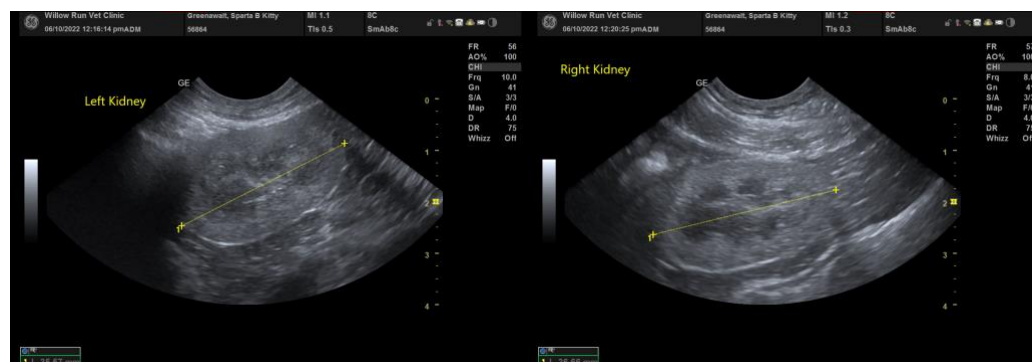
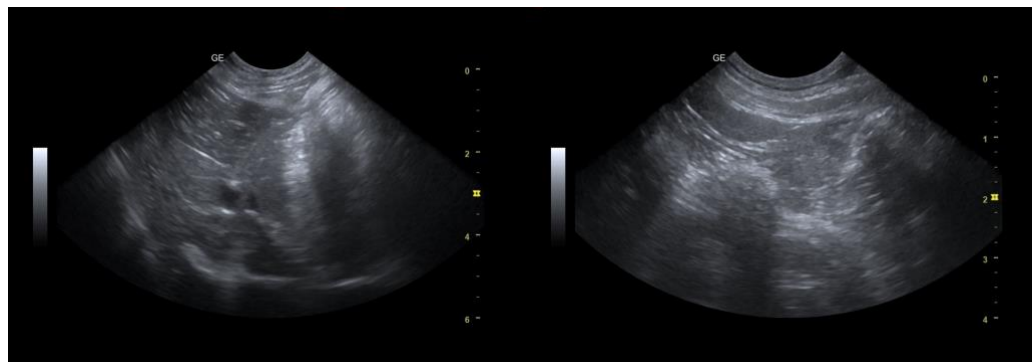
The base and limbs of the **pancreas** were observed to be largely isoechoic to surrounding omental fat. Pancreatic duct and capsular contour were acceptably normal and parenchyma respected normal curvilinear patterns. No overt evidence of active inflammatory or neoplastic disease was noted.

## ULTRASONOGRAPHIC FINDINGS

- Structurally unremarkable abdomen
- Moderate chronic interstitial nephrosis pattern, largely expected changes for this age patient

## INTERPRETATION OF THE FINDINGS & FURTHER RECOMMENDATIONS

The cause of weight loss is unclear and not directly related to any visceral disease. Subjectively, I do not believe that the kidneys are end-stage. Prerenal azotemia should be considered as a primary issue in this patient. Maldigestion panel, three view chest radiographs and full CNS examination is recommended to examine for occult disease that could be responsible for the weight loss. Evaluation for competitive eating environments should also be considered.





**PATIENT**

Sparta B Kitty  
Greenawalt

**SPECIES**

Feline

**BREED**

DMH

**SEX**

Neutered Male

**AGE**

14 Years

**WEIGHT**

8.9 Pounds

**INTERPRETED BY**

Eric Lindquist, DMV  
DABVP, Cert. IVUSS

**IMAGING  
PERFORMED BY**

Jack Reese

**HOSPITAL NAME**

Willow Run VC

**REFERRING VET**

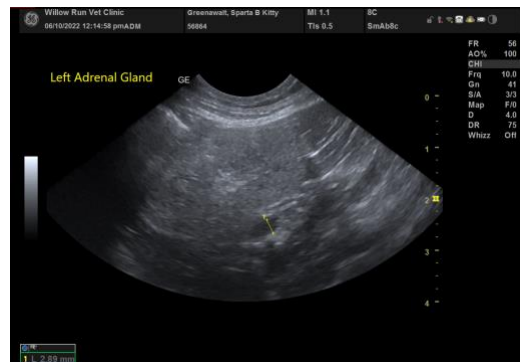
Molly Arnold, DVM

**INVOICE**

16033

**DATE**

6/11/22



The information and recommendations provided are based on the images presented by the referring veterinarian. No evaluation can be communicated regarding pathology that was not visible in the image/video clips provided.

Thank you for this referral. If the clinical or image interpretation does not parallel your findings or if I can be of any further assistance please contact me.

**Eric Lindquist**, DMV, DABVP, Cert. IVUSS, CEO of SonoPath.com  
info@SonoPath.com