



PATIENT

Tigger Tadros

SPECIES

Canine

BREED

Mixed

SEX

Neutered Male

AGE

7 Years

WEIGHT

18.34 Pounds

INTERPRETED BY

Eric Lindquist, DMV

DABVP, Cert. IVUSS

IMAGING PERFORMED BY

Eric Lindquist, DMV

DABVP, Cert. IVUSS

HOSPITAL NAME

Rockaway AH

REFERRING VET

Dr. Maniar

INVOICE

38616

DATE

6/10/22

PRESENTING CLINICAL SIGNS

Urinary incontinence, hx of diabetes.

ULTRASONOGRAPHIC EXAMINATION OF THE ABDOMEN

Urinary System

The **urinary bladder**, trigone, and pelvic urethra presented normal thicknesses and normal tone. The ureters were not visible which is normal. No uroliths or sediment were visualized and anechoic urine was present. No evidence of inflammatory or neoplastic changes were noted. Ureteral papillae were normal.

The **kidneys** were normal in size and contour; however, a minor hyperechoic ring was noted at the corticomedullary junction. This is consistent with diabetic nephropathy. This is likely from glucosuria. However, assessment for proteinuria is also warranted. This is an idiopathic finding, but an expected finding in diabetic patients. The left kidney measured 4.5 cm. The right kidney measured 4.39 cm.

Adrenal Glands

The **left adrenal gland** was visualized and recognized as having normal shape, size, position and echogenicity for this breed. The phrenic vasculature, glandular echogenicity and detail were unremarkable. Capsule, cortex, and medullary definition were normal for this age patient. The left adrenal gland measured 1.93 cm x 0.42 cm.

The **right adrenal gland** was mildly enlarged and slightly irregular, measuring 2.52 cm x 1.3 cm at the cranial pole and 1.03 cm at the caudal pole.

Spleen

The **spleen** presented a smooth homogeneous parenchyma hyperechoic to liver and renal cortical parenchyma. The capsule was smooth without noticeable expansion or deviation from within the spleen or adjacent pathology. The splenic vasculature demonstrated normal volume without signs of congestion or thrombosis. No sonographic evidence of acute or chronic inflammatory, neoplastic, or infarctual changes were noted.

Liver

Exam of the cranial abdomen demonstrated excessive **liver** size, swollen contour, with conserved uniform architecture. Parenchymal echogenicity was diffusely isoechoic to the spleen and falciform fat. Minor excessive GB debris was noted with the presence gall bladder dilation and precipitate without the overt formation of mucocele but this may be an issue in the future. This type of liver presentation typically is associated with slow and gradual SAP elevations with low-grade ALT rise. USG-FNA sampling is encouraged if more aggressive LE profiles are present such as ALT > 200 or rapid rise in SAP. These presentations are usually reactive hepatopathies owing to other disease processes either endocrine (Diabetes, Hypothyroidism, Cushing's disease), "antigen surveillance" from the gut/pancreas, or idiopathic breed predisposed progressions.

Gastrointestinal

A minor amount of non-shadowing, non-obstructive ingesta was noted in the **stomach**. Transit of chyme into the small intestine was normal. Curvilinear patterns were maintained throughout the GI tract. No evidence of pathology. Small and large intestine demonstrated normal luminal chyme and stool consistency respectively. No obstructive or overt infiltrative disease was noted. No associated abnormal lymphatic activity was noted.



PATIENT

Pancreas

Tigger Tadros

The base and limbs of the **pancreas** were observed to be largely isoechoic to surrounding omental fat. Pancreatic duct and capsular contour were acceptably normal and parenchyma respected normal curvilinear patterns. No overt evidence of active inflammatory or neoplastic disease was noted.

SPECIES

Canine

PRIMARY FINDINGS

- Minor right adrenal enlargement

BREED

Mixed

SECONDARY FINDINGS

- Diabetic nephropathy
- Gastric ingesta
- Vacuolar hepatopathy

SEX

Neutered Male

INTERPRETATION OF THE FINDINGS & FURTHER RECOMMENDATIONS

If USG is <1.020 and the patient appears Cushingoid, then workup for Cushing's warranted. An argument could be made for potential right adrenal dependent Cushing's versus PDH, or normal variant.

AGE

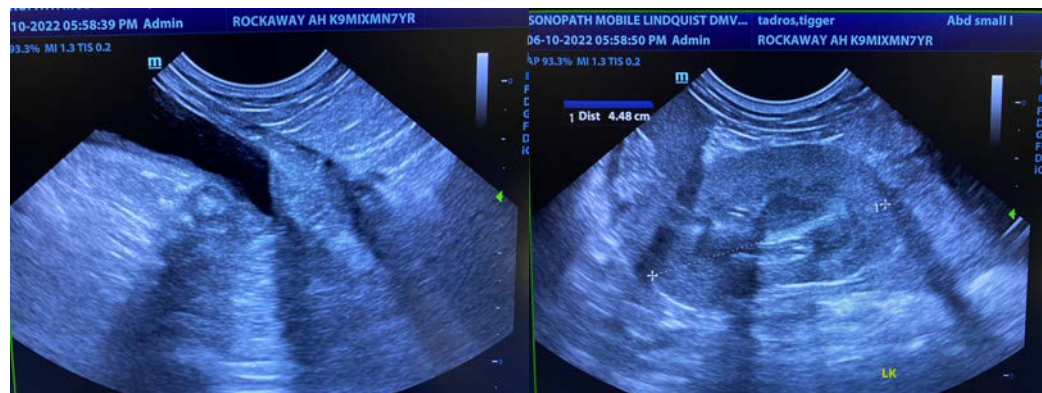
7 Years

WEIGHT

18.34 Pounds

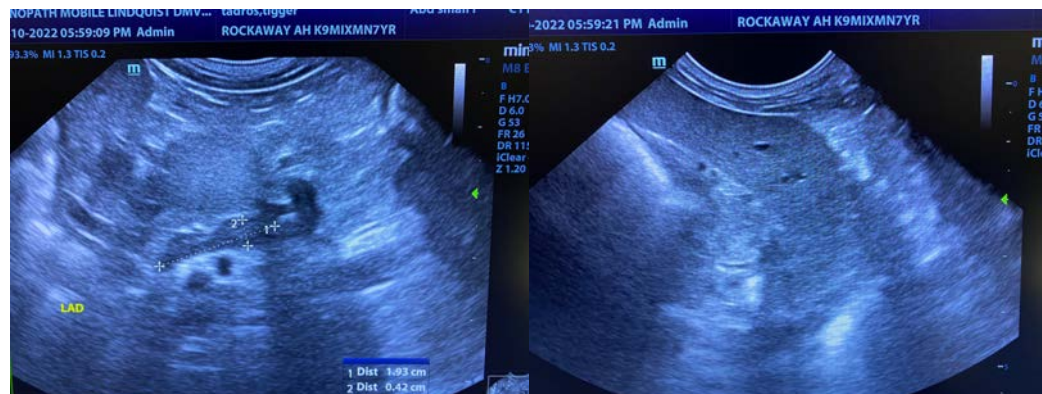
INTERPRETED BY

Eric Lindquist, DMV
DABVP, Cert. IVUSS



IMAGING PERFORMED BY

Eric Lindquist, DMV
DABVP, Cert. IVUSS



HOSPITAL NAME

Rockaway AH

REFERRING VET

Dr. Maniar

INVOICE

38616

DATE

6/10/22



PATIENT

Tigger Tadros

SPECIES

Canine

BREED

Mixed

SEX

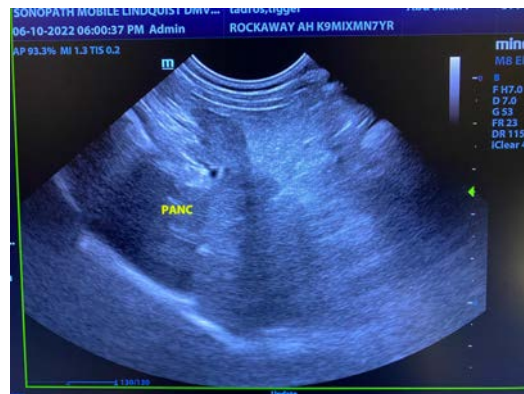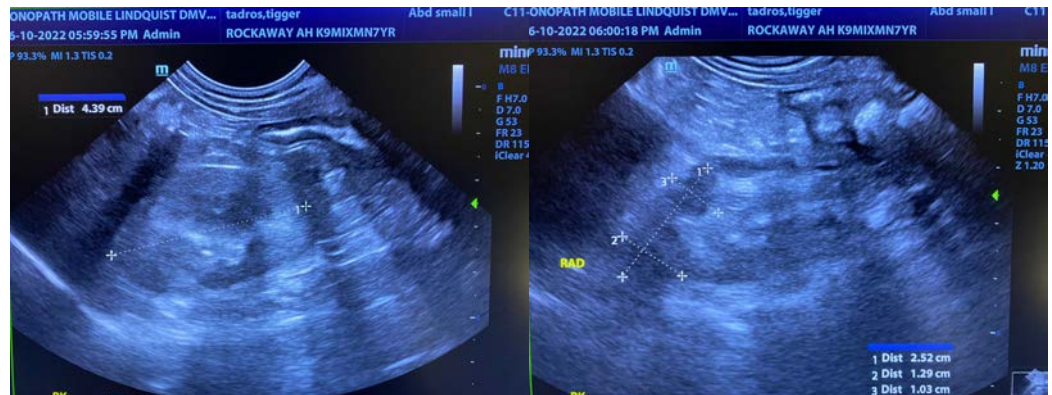
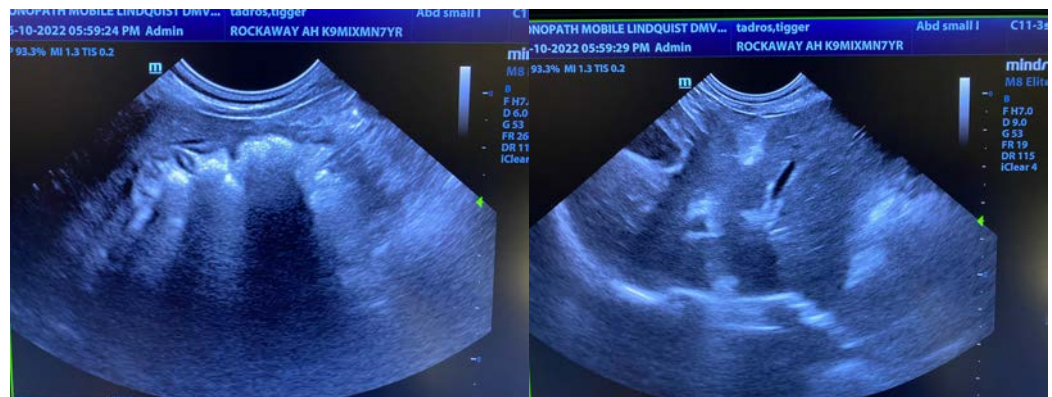
Neutered Male

AGE

7 Years

WEIGHT

18.34 Pounds



INTERPRETED BY

Eric Lindquist, DMV

DABVP, Cert. IVUSS

IMAGING PERFORMED BY

Eric Lindquist, DMV

DABVP, Cert. IVUSS

HOSPITAL NAME

Rockaway AH

REFERRING VET

Dr. Maniar

INVOICE

38616

DATE

6/10/22

The information and recommendations provided are based on the images presented by the referring veterinarian/sonographer. No evaluation can be communicated regarding pathology that was not visible in the image/video clips provided.

Thank you for this referral. If the clinical or image interpretation does not parallel your findings or if I can be of any further assistance please contact me.

Eric Lindquist, DMV, DABVP, Cert. IVUSS, CEO of SonoPath.com

info@SonoPath.com