



PATIENT

Shiloh Johnson

SPECIES

Canine

BREED

Dachshund

SEX

Male

AGE

13 years

WEIGHT

7.7 kg

INTERPRETED BY

Eric Lindquist, DMV
DABVP, Cert. IVUSS

IMAGING PERFORMED BY

Dr. Ebert

HOSPITAL NAME

Wilvet Salem

REFERRING VET

Dr. Ebert

INVOICE

30936

DATE

6/9/22

PRESENTING CLINICAL SIGNS

P has been wheezing for a few months now with on and off increased effort. No C. Not E/D since WED, also dry heaving but not producing any V. No BM last few days. Eats table scraps regularly. Abnormal PE/Chem/CBC/UA Results: cbc - mild normocytic regenerative anemia (RBC 4.05, HCT 26%, Hemoglob 9.9, retic 136), inc WBC 26k inc neutrophils 23k, inc monocytes 1.4k, dec eos 0.02k chem10 - glu 172, BUN 57, CRE 3.1, hypochloridemia 104, inc ALT 218, Inc ALP >2000 cPI - 1517 very high UA - unable to obtain sample due to patient not tolerating being on his back well. poor gum color and inc RE for a couple of minutes after rads.

ULTRASONOGRAPHIC EXAMINATION OF THE ABDOMEN

Urinary System

The **urinary bladder** was over distended with suspended debris. Urination history should be evaluated in this patient as regional enhanced mesentery was noted.

The **kidneys** revealed normal size and structure, corticomedullary definition and ratio for this age. The cortices presented largely uniform texture with normal echogenic relationship to liver and spleen. Medullary structure differed distinctly from the cortex. The left kidney measured 4.0 cm with minor pyelectasia and enhanced pericapsular fat. The right kidney was swollen with slight pyelectasia and reactive mesentery. Blood flow to the kidneys appeared to be adequate.

Adrenal Glands

The left **adrenal gland** was not visualized. The right adrenal gland was not visualized; however, hypoechoic, undifferentiated tissue was noted in this region and measured approximately 4.0 x 3.0 cm. This may represent an adrenal tumor.

Spleen

The **spleen** was volume contracted and uniform.

Liver

The **liver** revealed generalized enlargement with slight areas of biliary mineralization and irregular contour. The gallbladder and common bile duct were unremarkable.

Gastrointestinal

The **duodenum** was thickened with enhanced surrounding mesentery. Variable intestinal thickening was noted with reactive mesentery. Pockets of free fluid were noted.

Pancreas



PATIENT

Shiloh Johnson

The **pancreas** revealed heterogenous parenchymal changes with enhanced surrounding fat. This is suggestive for inflammation.

SPECIES

Canine

ULTRASONOGRAPHIC FINDINGS

Mass in the region of the right adrenal gland deviating the right kidney. Regional systemic inflammatory pattern involving the duodenum, pancreas and kidneys.

BREED

Dachshund

Subjectively benign hepatopathy.

Acute nephritis.

SEX

Male

INTERPRETATION OF THE FINDINGS & FURTHER RECOMMENDATIONS

Further imaging of the area of the right adrenal gland is recommended under full sedation or CT evaluation. I am concerned for right adrenal tumor, possibly pheochromocytoma and this may be the underlying source of the entire systemic, inflammatory presentation.

AGE

13 years

WEIGHT

7.7 kg

INTERPRETED BY

Eric Lindquist, DMV
DABVP, Cert. IVUSS

IMAGING PERFORMED BY

Dr. Ebert

HOSPITAL NAME

Wilvet Salem

REFERRING VET

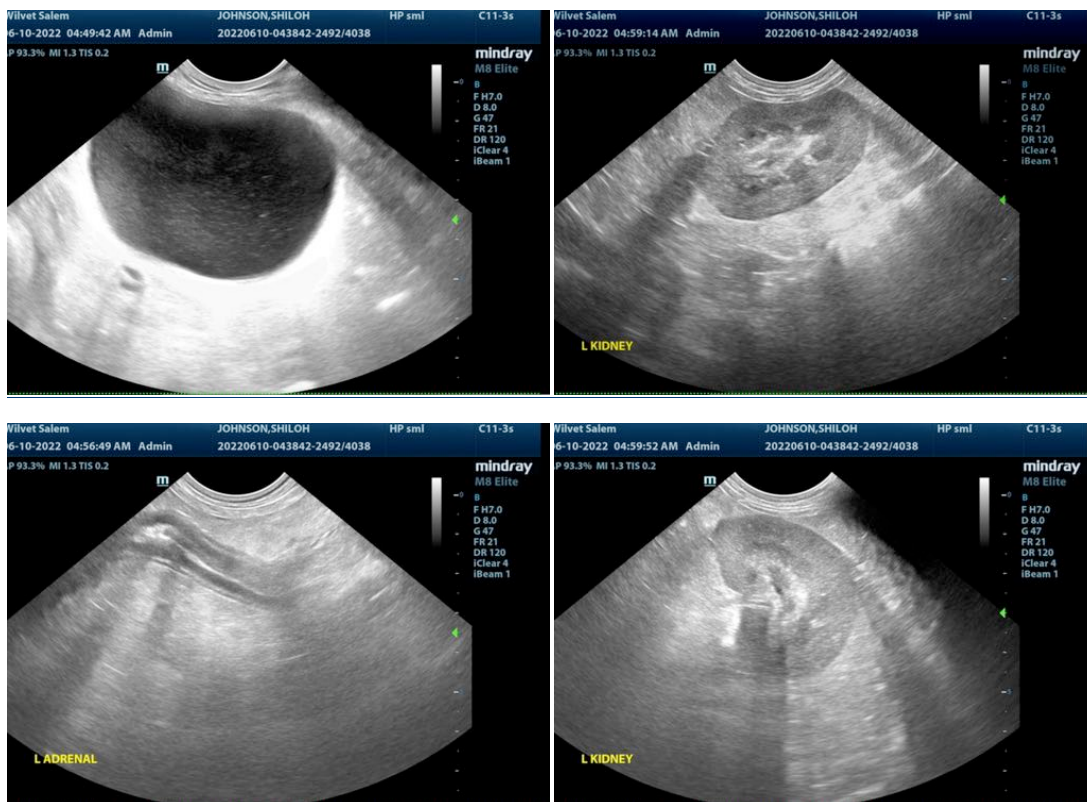
Dr. Ebert

INVOICE

30936

DATE

6/9/22





PATIENT

Shiloh Johnson

SPECIES

Canine

BREED

Dachshund

SEX

Male

AGE

13 years

WEIGHT

7.7 kg

INTERPRETED BY

Eric Lindquist, DMV
DABVP, Cert. IVUSS

IMAGING PERFORMED BY

Dr. Ebert

HOSPITAL NAME

Wilvet Salem

REFERRING VET

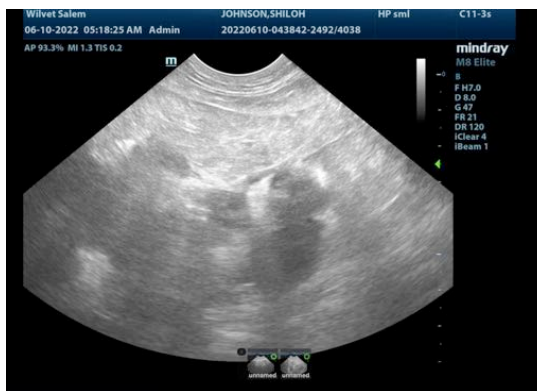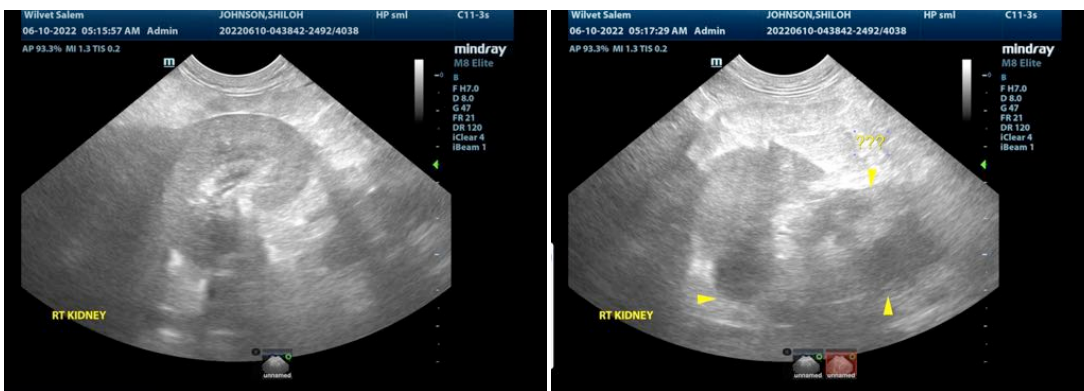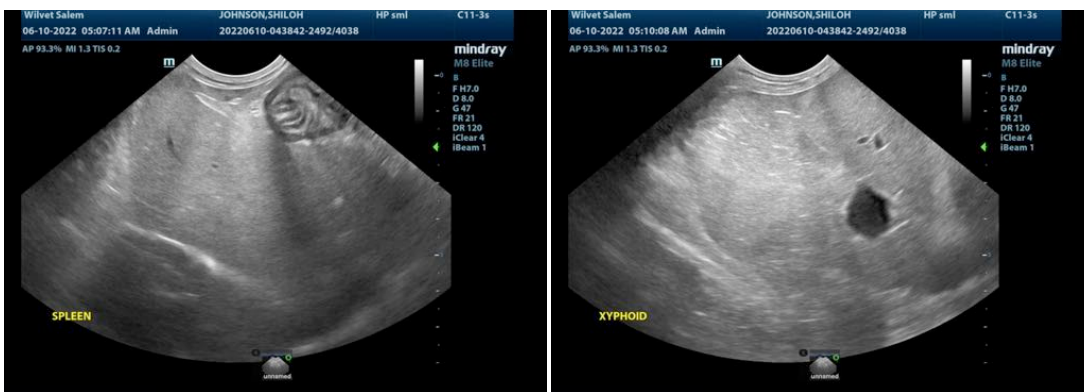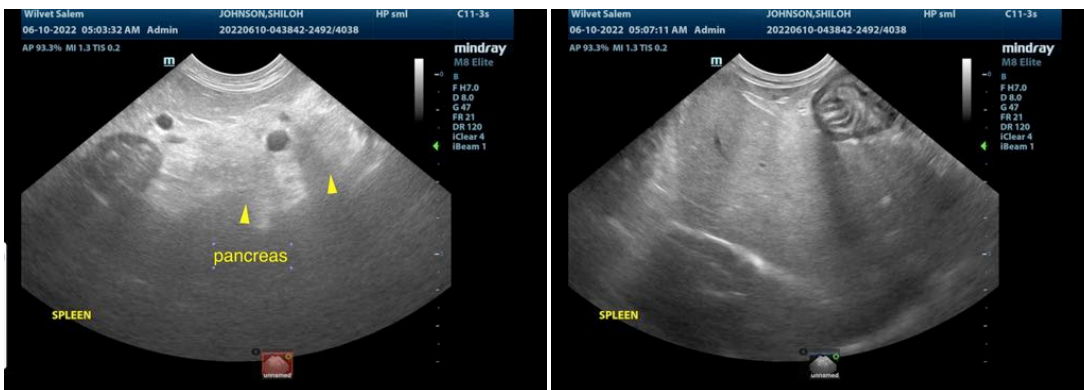Dr. Ebert

INVOICE

30936

DATE

6/9/22





PATIENT

Shiloh Johnson

The information and recommendations provided are based on the images presented by the referring veterinarian/sonographer. No evaluation can be communicated regarding pathology that was not visible in the image/video clips provided.

SPECIES

Canine

Thank you for this referral. If the clinical or image interpretation does not parallel your findings or if I can be of any further assistance please contact me.

BREED

Dachshund

Eric Lindquist, DMV, DABVP, Cert. IVUSS, CEO of SonoPath.com
info@SonoPath.com

SEX

Male

AGE

13 years

WEIGHT

7.7 kg

INTERPRETED BY

Eric Lindquist, DMV
DABVP, Cert. IVUSS

**IMAGING
PERFORMED BY**

Dr. Ebert

HOSPITAL NAME

Wilvet Salem

REFERRING VET

Dr. Ebert

INVOICE

30936

DATE

6/9/22