
**PATIENT PRESENTING CLINICAL SIGNS**

Pluto Jackson

History: Follow up echo, Last was on May 11, 2022 under last name Caiazza on last scan. Recommended recheck scan prior to surgery. Has been on Spironolactone, Fortekor, Vetmedin and Gabapentin, Aventikidney.

**SPECIES**

Canine

Abnormal PE/Chem/CBC/UA Results: n/a

**BREED**

Shih Tzu

**SEX**

Intact Male

**AGE**

9 Years

**WEIGHT**

15 Pounds

**ULTRASONOGRAPHIC EXAMINATION OF THE HEART**

CANINE CARDIAC PARAMETERS	MR VMAX (m/s)	TR VMAX (m/s)	LA/AO (Boon method)	LA/AO (Heart Base; Swe)	FS (%)	EF (%)	EPSS (cm)
NORMAL PARAMETER	4.5-5.5	<2.7	1.3	<1.3	28-40	40-100	<0.6
PATIENT	--	--	1.2	1.46	56	88	0.1
CANINE CARDIAC PARAMETERS	HR (BPM)	AV VMAX (m/s)	PV MAX (m/s)	BODY WEIGHT (kg)	LA 2D short axis Base view (cm)	LVIDd Avg; 2D and m-mode short axis (cm)	LVIDs Avg; 2D and m-mode short axis (cm)
NORMAL PARAMETER	50-100	0.7-1.7	0.7-1.6				
PATIENT	168	--	--	--	3.23	2.86	--

**INTERPRETED BY**

 Eric Lindquist, DMV  
 DABVP, Cert. IVUSS

**IMAGING PERFORMED BY**

Crystal Hill

**HOSPITAL NAME**

St. Catharines AH

**REFERRING VET**

Dr. Bactor

**INVOICE**

15992

**DATE**

6/10/22

**Cardiac Presentation**

The cardiac presentation in this patient presented persistent mitral and tricuspid insufficiency. Left ventricular, right atrial and right ventricular volumes were normal. Contractility was adequate. Left atrial size as slightly excessive yet well contained on this current protocol. No pericardial or pleural effusion or extracardiac disease noted.

**ULTRASONOGRAPHIC FINDINGS**

- Compensated valvular disease with minor left atrial enlargement

**INTERPRETATION OF THE FINDINGS & FURTHER RECOMMENDATIONS**

Minimal risk for minor anesthetic procedure. Tobuterol (premed), Propofol (induction) and Isoflurane (maintenance) recommended, as long as blood pressures, clinical status and basil respiratory rate are normal. Continuation of the current protocol and recheck echo in 3 months recommended.



**PATIENT**

Pluto Jackson

**SPECIES**

Canine

**BREED**

Shih Tzu

**SEX**

Intact Male

**AGE**

9 Years

**WEIGHT**

15 Pounds

**INTERPRETED BY**

Eric Lindquist, DMV  
DABVP, Cert. IVUSS

**IMAGING  
PERFORMED BY**

Cyrstal Hill

**HOSPITAL NAME**

St. Catharines AH

**REFERRING VET**

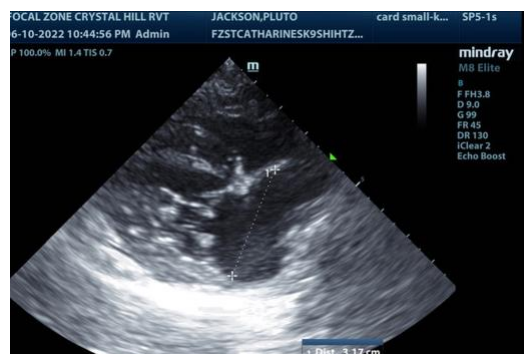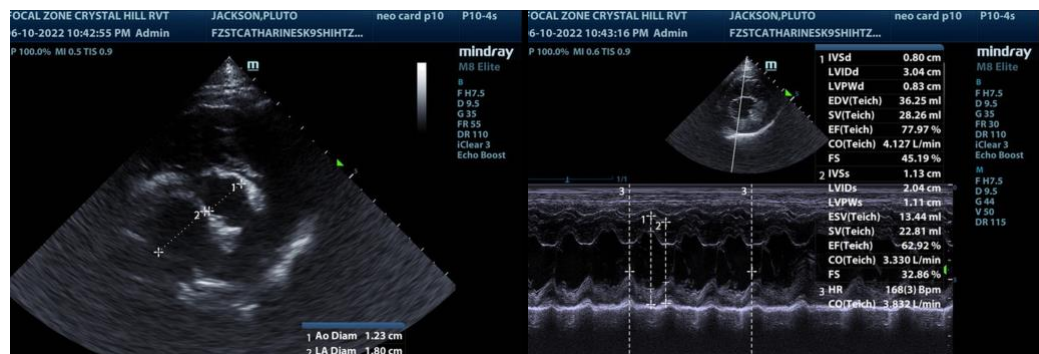
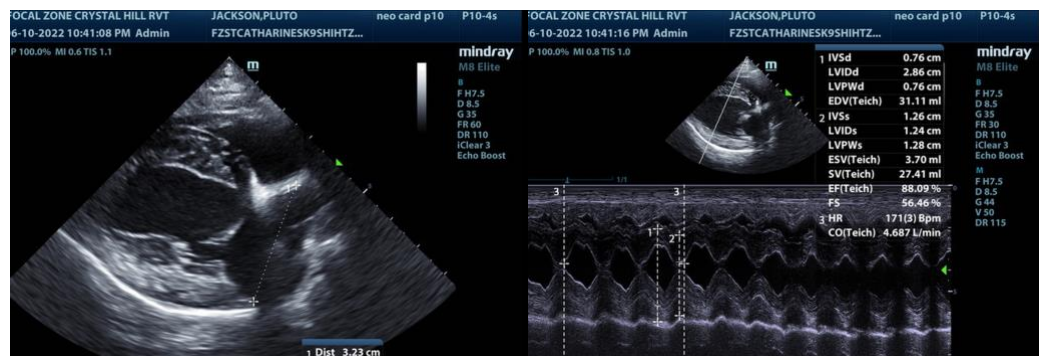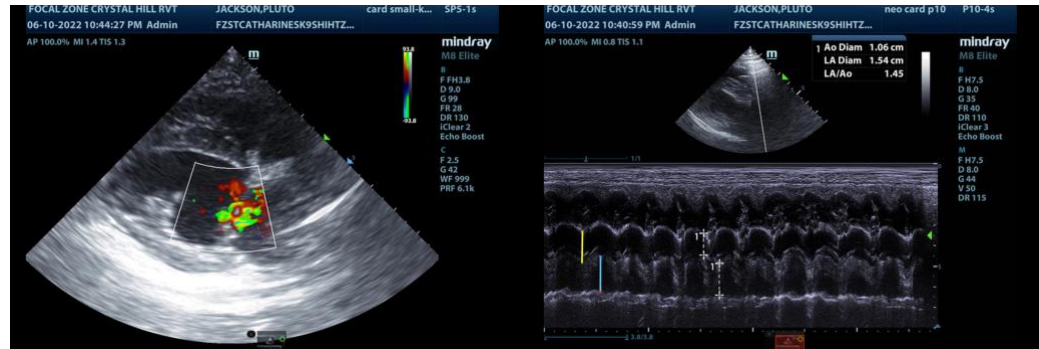
Dr. Boctor

**INVOICE**

15992

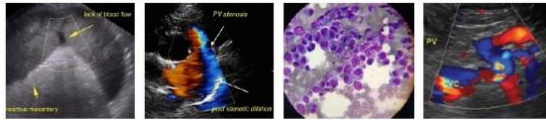
**DATE**

6/10/22



The information and recommendations provided are based on the images presented by the referring veterinarian. No evaluation can be communicated regarding pathology that was not visible in the image/video clips provided.

Thank you for this referral. If the clinical or image interpretation does not parallel your findings or if I can be of any further assistance please contact me.



## PATIENT

Pluto Jackson

**Eric Lindquist**, DMV, DABVP, Cert. IVUSS, CEO of SonoPath.com  
Eric.Lindquist@SonoPath.com

## SPECIES

Canine

## BREED

Shih Tzu

## SEX

Intact Male

## AGE

9 Years

## WEIGHT

15 Pounds

## INTERPRETED BY

Eric Lindquist, DMV  
DABVP, Cert. IVUSS

## IMAGING PERFORMED BY

Cyrstal Hill

## HOSPITAL NAME

St. Catharines AH

## REFERRING VET

Dr. Boctor

## INVOICE

15992

## DATE

6/10/22