



PATIENT

Willow Petrella

SPECIES

Canine

BREED

Shepherd Bully Mix

SEX

Female

AGE

5 months

WEIGHT

32 lbs

INTERPRETED BY

Eric Lindquist, DMV
DABVP, Cert. IVUSS

IMAGING PERFORMED BY

Dr. Shonk

HOSPITAL NAME

Court Street VH

REFERRING VET

Dr. Shonk

INVOICE

78213

DATE

6/1/26

PRESENTING CLINICAL SIGNS

History of PU/PD at home, P urinating in home right after bathroom break outside; inappropriate urinations (both with and without posturing)

Hoping to rule out ectopic ureters, urinary tract congenital structural issue

Abnormal PE/Chem/CBC/UA Results: Hooded vulva, CBC/chem 17 + lytes pending UA: SG 1.023 (O unable to collect first morning sample), WBC 20-30/hpf, no RBC/hpf; neg protein, cystatin B < 50

ULTRASONOGRAPHIC EXAMINATION OF THE ABDOMEN

Urinary System

The **urinary bladder**, trigone, and pelvic urethra presented normal thicknesses and normal tone. The pelvic urethra was imaged 1.0 cm beyond the cystourethral junction and appeared normal. There was no gross evidence of ectopic ureters. However, I cannot completely rule out the possibility of a small ectopic ureter. No uroliths or sediment were visualized and anechoic urine was present. No evidence of inflammatory or neoplastic changes was noted. Ureteral papillae were normal.

The **kidneys** revealed normal size and structure, corticomedullary definition and ratio for this age. The cortices presented largely uniform texture with normal echogenic relationship to liver and spleen. Medullary structure differed distinctly from the cortex and no evidence of pelvic dilation was present. The capsules were acceptably uniform without significant irregularities. The right kidney measured 5.0 cm. The left kidney measured 4.5 cm.

Adrenal Glands

Both **adrenal glands** were visualized and recognized as having normal shape, size, position and echogenicity for this breed. The phrenic vasculature, glandular echogenicity and detail were unremarkable. Capsule, cortex, and medullary definition were normal for this age patient. The left adrenal gland measured 0.5 cm. The right adrenal gland measured 0.6 cm.

Spleen

The **spleen** presented a smooth homogeneous parenchyma hyperechoic to liver and renal cortical parenchyma. The capsule was smooth without noticeable expansion or deviation from within the spleen or adjacent pathology. The splenic vasculature demonstrated normal volume without signs of congestion or thrombosis. No sonographic evidence of acute or chronic inflammatory, neoplastic, or infarctual changes was noted.

Liver

The **liver** images submitted revealed subjectively normal liver size, contour, and structure. Parenchymal echogenicity was naturally coarse and hypoechoic to the spleen. Vascular and biliary tracts were of normal volume with no evidence of congestion. The gallbladder presented acceptably thin walls with primarily anechoic content. The cystic and common bile ducts were normal. No pathological hepatic



PATIENT

Willow Petrella

lymphadenopathy was evident. No overt structural evidence of inflammatory, infiltrative or regenerative pathology was evident.

SPECIES

Canine

Gastrointestinal

Examination of the **gastrointestinal tract** revealed a stomach and intestine free of stasis, of normal wall thickness, acceptable curvilinear mural detail, and peristaltic activity. Small and large intestine demonstrated normal luminal chyme and stool consistency respectively. No obstructive or overt infiltrative disease was noted. No associated abnormal lymphatic activity was noted.

BREED

Shepherd Bully Mix

SEX

Female

Pancreas

The base and limbs of the **pancreas** were observed to be largely isoechoic to surrounding omental fat. Pancreatic duct and capsular contour were acceptably normal and parenchyma respected normal curvilinear patterns. No overt evidence of active inflammatory or neoplastic disease was noted.

AGE

5 months

WEIGHT

32 lbs

ULTRASONOGRAPHIC FINDINGS

Structurally unremarkable abdomen.

INTERPRETED BY

Eric Lindquist, DMV
DABVP, Cert. IVUSS

INTERPRETATION OF THE FINDINGS & FURTHER RECOMMENDATIONS

There was no evidence of ectopic ureters. I cannot completely rule out a small ectopic ureter, yet the urinary tract sonographically appears normal at this time. Examination of the vaginal vestibule is recommended for predisposing issues. If ectopic ureter is suspected after empirical treatment for UTI, then CT with contrast is indicated.

IMAGING PERFORMED BY

Dr. Shonk

HOSPITAL NAME

Court Street VH

REFERRING VET

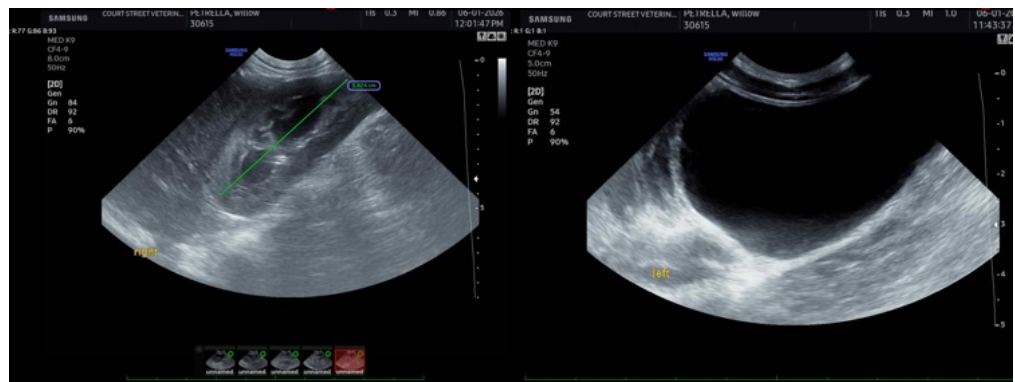
Dr. Shonk

INVOICE

78213

DATE

6/1/26





PATIENT

Willow Petrella

SPECIES

Canine

BREED

Shepherd Bully Mix

SEX

Female

AGE

5 months

WEIGHT

32 lbs

INTERPRETED BY

Eric Lindquist, DMV
DABVP, Cert. IVUSS

IMAGING PERFORMED BY

Dr. Shonk

HOSPITAL NAME

Court Street VH

REFERRING VET

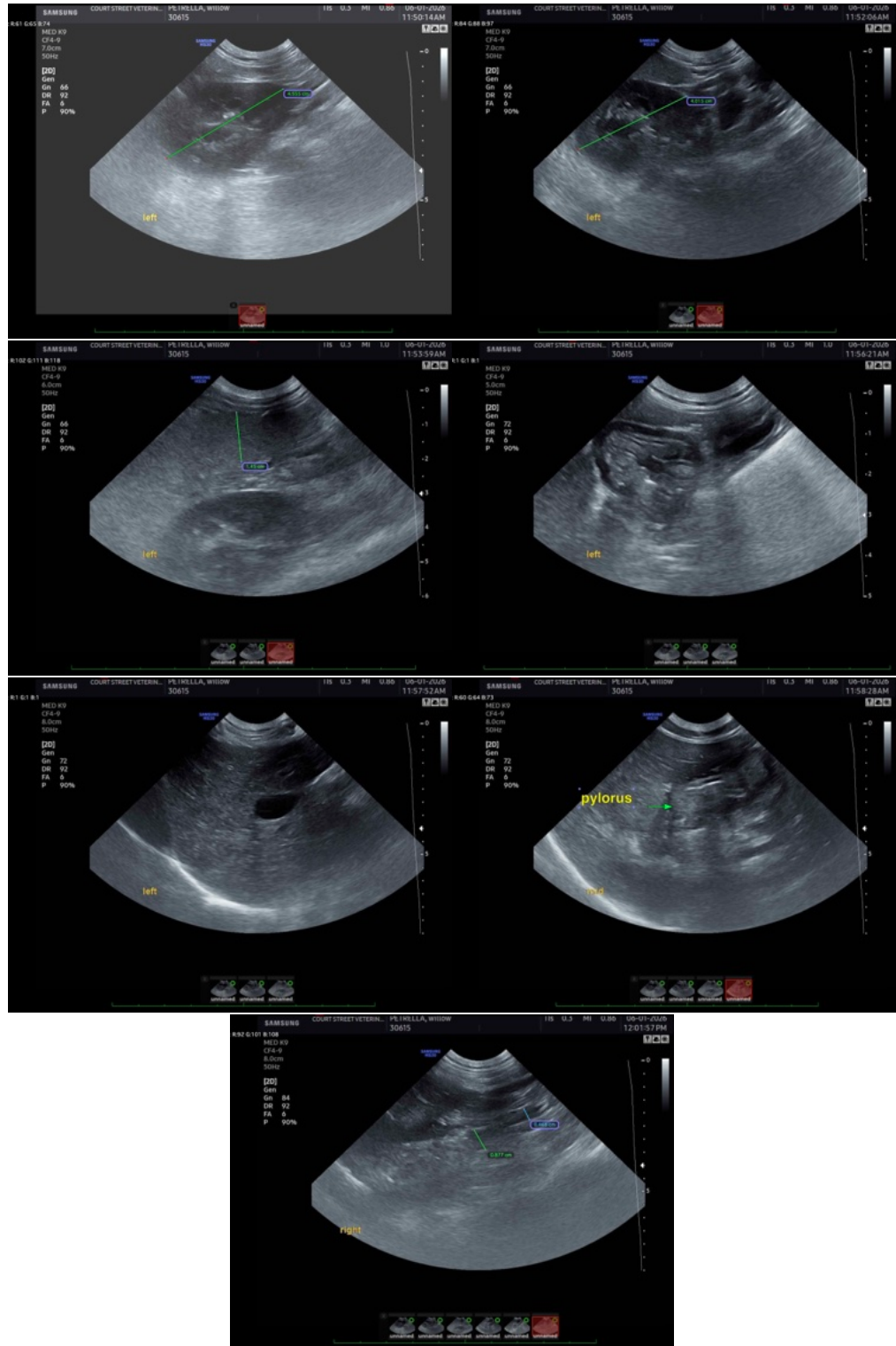
Dr. Shonk

INVOICE

78213

DATE

6/1/26





PATIENT

Willow Petrella

SPECIES

Canine

BREED

Shepherd Bully Mix

SEX

Female

AGE

5 months

WEIGHT

32 lbs

INTERPRETED BY

Eric Lindquist, DMV
DABVP, Cert. IVUSS

IMAGING PERFORMED BY

Dr. Shonk

HOSPITAL NAME

Court Street VH

REFERRING VET

Dr. Shonk

INVOICE

78213

DATE

6/1/26

The information and recommendations provided are based on the images presented by the referring veterinarian/sonographer. No evaluation can be communicated regarding pathology that was not visible in the image/video clips provided.

Thank you for this referral. If the clinical or image interpretation does not parallel your findings or if I can be of any further assistance please contact me.

Eric Lindquist, DMV, DABVP (CFM), Cert. IVUSS, CEO of SonoPath.com

info@SonoPath.com