



PATIENT

Milo Nissel

SPECIES

Canine

BREED

Yorkie

SEX

Neutered Male

AGE

10

WEIGHT

17.8

INTERPRETED BY

Eric Lindquist, DMV,
DABVP(CFM), Cert.
IVUSS

IMAGING PERFORMED BY

Jenn

HOSPITAL NAME

Rockaway Animal
Hospital

REFERRING VET

Dr. Brooks

INVOICE

16621

DATE

06/01/26

PRESENTING CLINICAL SIGNS

Hx of seizures, vomiting, lethargy, anorexia, trouble standing. Treating for pancreatitis Had a prev abd u/s 12/18/25 Current meds Zonisamide, Thyro tabs Panoquel

Abnormal PE/Chem/CBC/UA Results: WBC 17.45 Glob 4.8 ALT 492 ALP 1724 GGT 20 Lipase 837

ULTRASONOGRAPHIC EXAMINATION OF THE ABDOMEN

Urinary System

The **urinary bladder**, trigone, and pelvic urethra presented normal thicknesses and normal tone. The ureters were not visible which is normal. No uroliths or sediment were visualized, and anechoic urine was present. No evidence of inflammatory or neoplastic changes were noted. Ureteral papillae were normal.

The **residual prostate** measured 8.0 mm.

The **kidneys** revealed largely normal size and structure, corticomedullary definition and ratio (cortex 1/3 of medulla) were essentially maintained with some minor age-related loss of curvilinear patterns regarding the capsule and C/M junction. The cortices presented largely uniform texture with some increased echogenicity expected for his age patient. Medullary structure differed distinctly from that of the cortex. Slight mineralizations were noted. The left kidney measured 4.5 cm in length. The right kidney measured 4.2 cm in length.

Adrenal Glands

Both **adrenal glands** were visualized and recognized as having normal shape, size, position and echogenicity for this breed. The phrenic vasculature, glandular echogenicity and detail were unremarkable. Capsule, cortex, and medullary definition were normal for this age patient. The left adrenal gland measured 1.9 cm x 0.56 cm width at the caudal pole and 0.79 cm width at the cranial pole. The right adrenal gland measured 1.6 cm x 0.7 cm width at the caudal pole and 0.73 cm width at the cranial pole.

Spleen

The **spleen** revealed a focal mixed microcystic 1.5 cm nodule at the caudal pole.

Liver

The **liver** images from right and left intercostal as well as subcostal views revealed subjectively normal liver size, contour, and structure. Some minor age-related parenchymal remodeling was noted but likely not clinically significant at this time. Vascular and biliary tracts were of normal volume and no evidence of congestion was noted. The gallbladder presented some dependent debris with essentially normal contour. The cystic and common bile ducts were normal. No overt evidence of active inflammatory, infiltrative or regenerative pathology was noted but should be paired with current or past LE elevations regarding any clinical significance to this presentation. The hepatic lymph nodes were unremarkable.

Gastrointestinal



PATIENT

Milo Nissel

The upper **duodenum** was enveloped by pancreatic inflammation. The stomach and colon were unremarkable. There is a 0.84 cm structure in the upper duodenum that does not appear obstructive. This may be transiting medication, however, a foreign body cannot be ruled out.

SPECIES

Canine

Pancreas

The **pancreas** revealed mixed echogenic changes in the left limb with hyperechoic steatitis pattern. Heterogenous right pancreatic changes were also present.

BREED

Yorkie

Free Abdomen

Rapid view of the heart revealed no evident pathology in the right atrium, right auricle or pericardium.

SEX

Neutered Male

ULTRASONOGRAPHIC FINDINGS

- Duodenitis/pancreatitis pattern.
- Concerning splenic nodule- hemangiosarcoma, nodular hyperplasia, abscessation less likely.
- Age-related renal changes with mineralizations.
- Age-related hepatic remodeling.

AGE

10

INTERPRETATION OF THE FINDINGS & FURTHER RECOMMENDATIONS

WEIGHT

17.8

Recommend chest radiographs. A skull CT would be ideal given the seizure activity to ensure metastatic disease is not an issue. Intensive therapy for pancreatitis is indicated. Recheck in 48-72 hours. Once the patient is stabilized, proactive splenectomy is recommended unless metastatic disease is found in the CNS.

INTERPRETED BY

Eric Lindquist, DMV,
DABVP(CFM), Cert.
IVUSS

ABOUT SONOPATH CT SERVICES:

SonoPath CT Services are offered at the SonoPath Imaging and Veterinary Education Center, 141 Main St (rt 206), Andover, New Jersey, a 20-minute drive west on route 80/206 North from the route 80/287 interchange/Parsippany, New Jersey. More information can be found at <https://sonopath.com/services/sonopath-ct-services>

IMAGING PERFORMED BY

Jenn

HOSPITAL NAME

Rockaway Animal
Hospital

REFERRING VET

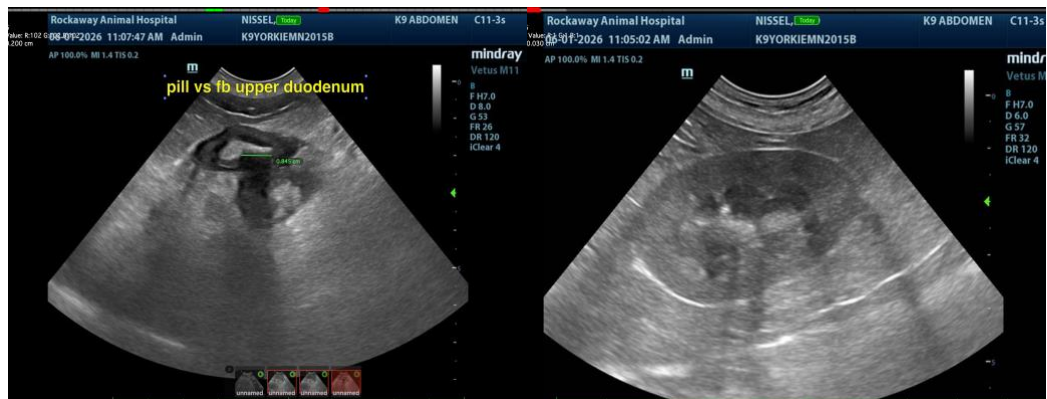
Dr. Brooks

INVOICE

16621

DATE

06/01/26





PATIENT

Milo Nissel

SPECIES

Canine

BREED

Yorkie

SEX

Neutered Male

AGE

10

WEIGHT

17.8

INTERPRETED BY

Eric Lindquist, DMV,
DABVP(CFM), Cert.
IUUS

IMAGING PERFORMED BY

Jenn

HOSPITAL NAME

Rockaway Animal
Hospital

REFERRING VET

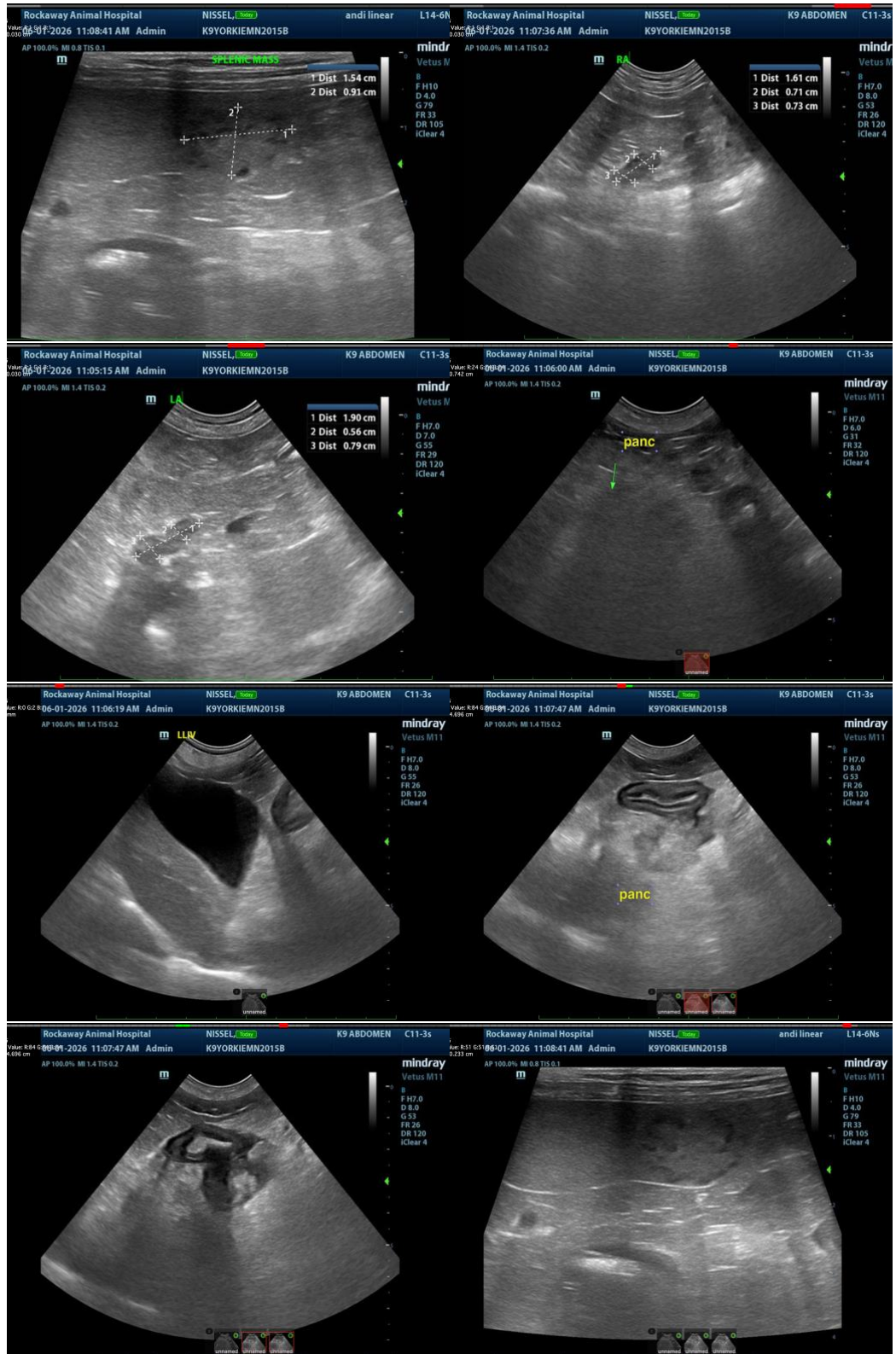
Dr. Brooks

INVOICE

16621

DATE

06/01/26





PATIENT

Milo Nissel

SPECIES

Canine

BREED

Yorkie

SEX

Neutered Male

AGE

10

WEIGHT

17.8

INTERPRETED BY

Eric Lindquist, DMV,
DABVP(CFM), Cert.
IVUSS

IMAGING PERFORMED BY

Jenn

HOSPITAL NAME

Rockaway Animal
Hospital

REFERRING VET

Dr. Brooks

INVOICE

16621

DATE

06/01/26

The information and recommendations provided are based on the images presented by the referring veterinarian/sonographer. No evaluation can be communicated regarding pathology that was not visible in the image/video clips provided.

Thank you for this referral. If the clinical or image interpretation does not parallel your findings or if I can be of any further assistance, please contact me.

Eric Lindquist, DMV, DABVP(CFM), Cert. IVUSS,

CEO, Owner, Founder -- SonoPath.com

info@SonoPath.com