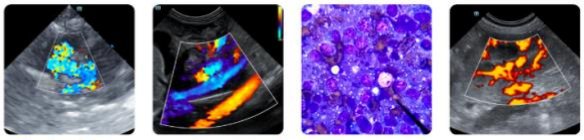

PATIENT
Lola Orluck

SPECIES
Canine

BREED
Labrador Retriever

SEX
Spayed Female

AGE
8 Years 2 Months

WEIGHT
57 lbs

INTERPRETED BY
Eric Lindquist, DMV, DABVP(CFM), Cert. IVUSS

IMAGING PERFORMED BY
Dr. Jessie Evoniuk

HOSPITAL NAME
State Avenue Vet Clinic

REFERRING VET
Dr. Jessie Evoniuk

INVOICE
16229

DATE
06/01/26

PRESENTING CLINICAL SIGNS

Presents for vomiting, increased respiratory effort, hoarse bark, and weight loss. Vomiting: Intermittent, ~50% of meals, onset ~2 weeks ago, sometimes post-prandial. Coughing/gagging: Recent onset, with mucous; one episode of blood-tinged mucous (reported 2026-05-29). Weight loss: From 66 lb to 57 lb since last visit. Appetite: Eating but only finishes meal ~50% of the time. Water intake: Normal per client. Defecation: Normal per client, no diarrhea. Activity: Lethargic, decreased energy, increased sleep, more pronounced since loss of housemate. Pruritus: None reported. Floor licking: Frequent, non-localized, possible anxiety component. Diet: Switched to Purina Pro Plan Salmon ~3 months ago (previously lamb & rice). Hypothyroidism: Diagnosed fall 2025, on levothyroxine; dose reduced to once daily due to weight loss. No known dietary indiscretion, no recent travel outside the state, some hunting activity. No fever noted at home. Current medications: Levothyroxine (dose reduced to once daily due to weight loss)

BCS 4/9; significant muscle and fat loss, CRT <2 sec, Discoloration and pulpitis of 204 and 103; grade 2 calculus, increased respiratory effort, more prominent breathing LYM 0.50, RDWc 20.7, PLT 57, noted bruising after shaving, no petechiation reported/noted prior Chem wnl, SDMA wnl, TT4 wnl (1.3) Multiple pulmonary nodules noted on chest rad, pending specialist's review

ULTRASONOGRAPHIC EXAMINATION OF THE ABDOMEN

Urinary System

The **urinary bladder**, trigone, and pelvic urethra to a depth of 1.0 cm presented normal thicknesses and normal tone. The ureters were not visible which is normal. No uroliths or sediment were visualized, and anechoic urine was present. No evidence of inflammatory or neoplastic changes were noted. Ureteral papillae were normal.

The **kidneys** revealed normal size and structure, corticomedullary definition and ratio for this age. The cortices presented largely uniform texture with normal echogenic relationship to liver and spleen. Medullary structure differed distinctly from the cortex and no evidence of pelvic dilation was present. The capsules were acceptably uniform without significant irregularities. The left kidney measured 6.9 cm in length. The right kidney measured 5.3 cm in length.

Adrenal Glands

The **left adrenal gland** was visualized and recognized as having normal shape, size, position and echogenicity for this breed. The phrenic vasculature, glandular echogenicity and detail were unremarkable. Capsule, cortex, and medullary definition were normal for this age patient. The left adrenal gland measured 0.6 cm width.

The region of the **right adrenal gland** was imaged without evident pathology.

Spleen

The **spleen** presented a smooth homogeneous parenchyma hyperechoic to liver and renal cortical parenchyma. The capsule was smooth without noticeable expansion or deviation from within the spleen or adjacent pathology. The splenic vasculature demonstrated normal volume without signs of congestion or thrombosis. No sonographic evidence of acute or chronic inflammatory, neoplastic, or infarctual changes were noted.

Liver

PATIENT

Lola Orluck

SPECIES

Canine

BREED

Labrador Retriever

SEX

Spayed Female

AGE

8 Years 2 Months

WEIGHT

57 lbs

INTERPRETED BY

Eric Lindquist, DMV, DABVP(CFM), Cert. IVUSS

IMAGING PERFORMED BY

Dr. Jessie Evoniuk

HOSPITAL NAME

State Avenue Vet Clinic

REFERRING VET

Dr. Jessie Evoniuk

INVOICE

16229

DATE

06/01/26

The **liver** in this patient revealed dilated hepatic veins and what appears to be pericardial effusion throughout the diaphragm. The hepatic parenchyma was uniform. The gallbladder and common bile duct were unremarkable.

Gastrointestinal

There was some minor retention of ingesta noted in the **stomach**, yet not pathological. This is consistent with end post prandial presentation. Transit of chyme into the small intestine was normal. Curvilinear patterns were maintained throughout the GI tract. No evidence of pathology. Small and large intestine demonstrated normal luminal chyme and stool consistency respectively. No obstructive or overt infiltrative disease was noted. No associated abnormal lymphatic activity was noted. Some hyperperistalsis was noted in the small intestine.

Pancreas

The base and limbs of the **pancreas** were observed to be largely isoechoic to surrounding omental fat. Some parenchymal remodeling, however, with mild deviation from curvilinear normalcy was observed. Pancreatic duct and capsular irregularities were present consistent with age related changes. If pain upon imaging (+ Murphy sign) was present or if the patient is focally painful in subxiphoid palpation then low-grade smoldering chronic pancreatitis should be suspected.

ULTRASONOGRAPHIC FINDINGS

- Unremarkable abdomen with slight hepatic vein dilation.
- Nonspecific gastrointestinal upset with retention of ingesta.
- Age-related pancreatic remodeling.

INTERPRETATION OF THE FINDINGS & FURTHER RECOMMENDATIONS

A rapid echocardiogram and thoracic workup are warranted to ensure that cardiac disease is not an issue.

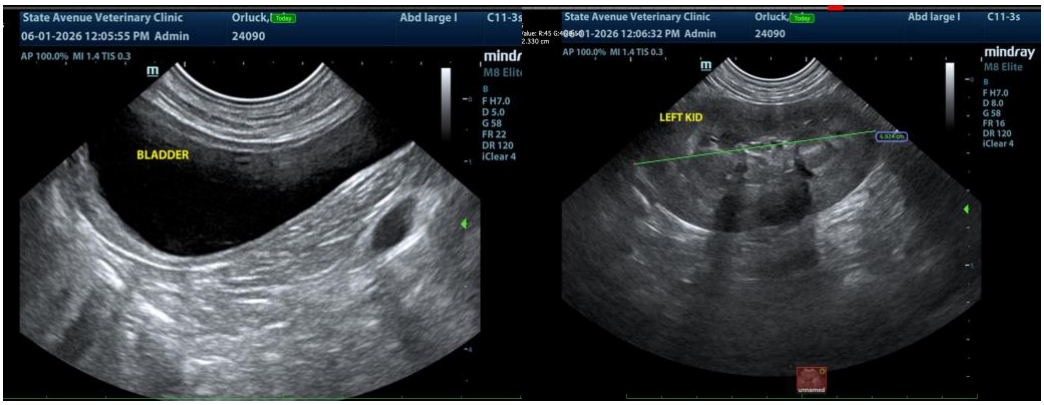

SonoPath

FOSTERING THE ART OF VETERINARY MEDICINE™

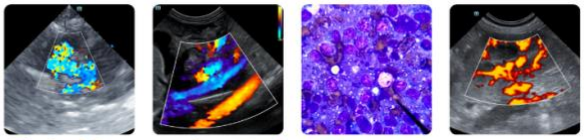

Clinical Sonography & Telecytology

Educational Teleconsultation Services™

SonoPath.com info@sonopath.com 1.800.838.4268

PATIENT

Lola Orluck

SPECIES

Canine

BREED

Labrador Retriever

SEX

Spayed Female

AGE

8 Years 2 Months

WEIGHT

57 lbs

INTERPRETED BY

Eric Lindquist, DMV, DABVP(CFM), Cert. IVUSS

IMAGING PERFORMED BY

Dr. Jessie Evoniuk

HOSPITAL NAME

State Avenue Vet Clinic

REFERRING VET

Dr. Jessie Evoniuk

INVOICE

16229

DATE

06/01/26

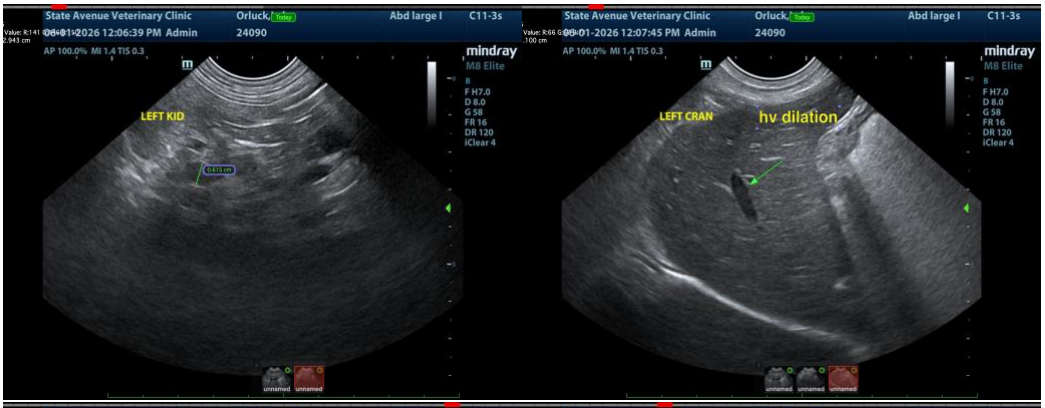

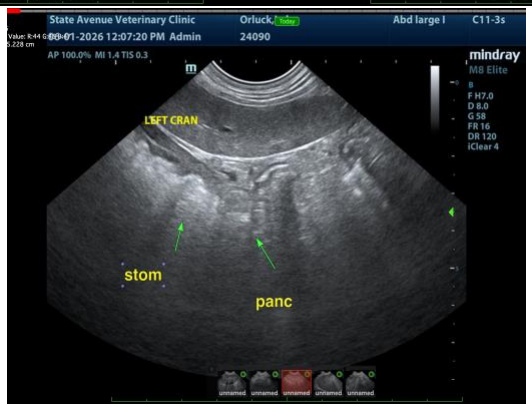

The information and recommendations provided are based on the images presented by the referring veterinarian/sonographer. No evaluation can be communicated regarding pathology that was not visible in the image/video clips provided.

Thank you for this referral. If the clinical or image interpretation does not parallel your findings or if I can be of any further assistance, please contact me.

Eric Lindquist, DMV, DABVP(CFM), Cert. IVUSS,

CEO, Owner, Founder -- SonoPath.com

info@SonoPath.com

SonoPath
FOSTERING THE ART OF VETERINARY MEDICINE™

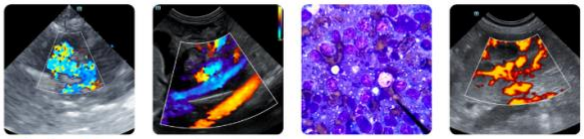

Clinical Sonography & Telecytology
Educational Teleconsultation Services™

SonoPath.com info@sonopath.com 1.800.838.4268

PATIENT

Lola Orluck

SPECIES

Canine

BREED

Labrador Retriever

SEX

Spayed Female

AGE

8 Years 2 Months

WEIGHT

57 lbs

INTERPRETED BY

Eric Lindquist, DMV, DABVP(CFM), Cert. IVUSS

IMAGING PERFORMED BY

Dr. Jessie Evoniuk

HOSPITAL NAME

State Avenue Vet Clinic

REFERRING VET

Dr. Jessie Evoniuk

INVOICE

16229

DATE

06/01/26