



PATIENT

Lola McComb

SPECIES

Canine

BREED

Golden Retriever

SEX

Spayed Female

AGE

7 Years

WEIGHT

82 Pounds

INTERPRETED BY

Eric Lindquist, DMV,
DABVP (CFM), Cert.
IVUSS

IMAGING PERFORMED BY

Chloe Lowe, CVT

HOSPITAL NAME

Walker Valley VH

REFERRING VET

Dr. Barnhorst

INVOICE

37272

DATE

6/1/26

PRESENTING CLINICAL SIGNS

History of mass cell tumors, possible IHA. Fever, lethargy. Prednisone, Sucralfate, Prilosec, immunosuppressive.

Abnormal PE/Chem/CBC/UA Results: Coag panel PT 9.6, PTT 13.2 Regenerative anemia 24% Tp 6. Leukocytosis 219k. Alt 171, Alkp 443. Bili normal. Platelet 164k, HCT 18% this am.

ULTRASONOGRAPHIC EXAMINATION OF THE ABDOMEN

Urinary System

The **urinary bladder**, trigone, and pelvic urethra presented normal thicknesses and normal tone. The ureters were not visible which is normal. No uroliths or sediment were visualized and anechoic urine was present. No evidence of inflammatory or neoplastic changes was noted. Ureteral papillae were normal.

The **kidneys** revealed largely normal size and structure, corticomedullary definition and ratio (cortex 1/3 of medulla) were essentially maintained with some age-related loss of curvilinear patterns regarding the capsule and C/M junction. The cortices presented largely uniform texture with some increased echogenicity expected for this age patient. Medullary structure differed distinctly from that of the cortex and no evidence of pelvic dilation was present. The left kidney measured 7.16 cm. The right kidney measured 7.0 cm.

Adrenal Glands

Both **adrenal glands** were visualized and recognized as having normal shape, size, position and echogenicity for this breed. The phrenic vasculature, glandular echogenicity and detail were unremarkable. Capsule, cortex, and medullary definition were normal for this age patient. The left adrenal gland measured 1.88 cm x 0.41 cm at the cranial pole and 0.62 cm at the caudal pole. The right adrenal gland measured 1.81 cm x 0.88 cm at the cranial pole and 0.5 cm at the caudal pole.

Spleen

The **spleen** in this patient presented moderate to severe splenomegaly and scalloping hypoechoic parenchyma with enhanced surrounding mesentery and subtle micronodular changes. This change is strongly consistent with infiltrative disease.

Liver

The **liver** was swollen, hypoechoic and irregular. No evidence of vascular compromise was noted. No evidence of thrombosis nor torsion. The gallbladder and common bile duct were unremarkable.

Gastrointestinal

Variable **gastrointestinal** thickening was noted with enhanced surrounding mesentery.

Pancreas

The **pancreas** was obscured by hyperechoic surrounding fat secondary to the Splenohepatic and GI presentation. No primary disease was noted in the pancreas.

Free Abdomen



PATIENT

Slight free fluid was noted in the abdomen.

Lola McComb

ULTRASONOGRAPHIC FINDINGS

SPECIES

- Splenohepatic and early GI infiltrative disease.
- Age-related renal changes
- Free fluid
- Hyperechoic fat surrounding the pancreas- no evidence of primary pancreatic disease.

BREED

INTERPRETATION OF THE FINDINGS & FURTHER RECOMMENDATIONS

Golden Retriever

FNA of the spleen and liver is recommended. Round cell neoplasia is suspected.

SEX

Spayed Female

AGE

7 Years

WEIGHT

82 Pounds

INTERPRETED BY

Eric Lindquist, DMV,
 DABVP (CFM), Cert.
 IVUSS

IMAGING PERFORMED BY

Chloe Lowe, CVT

HOSPITAL NAME

Walker Valley VH

REFERRING VET

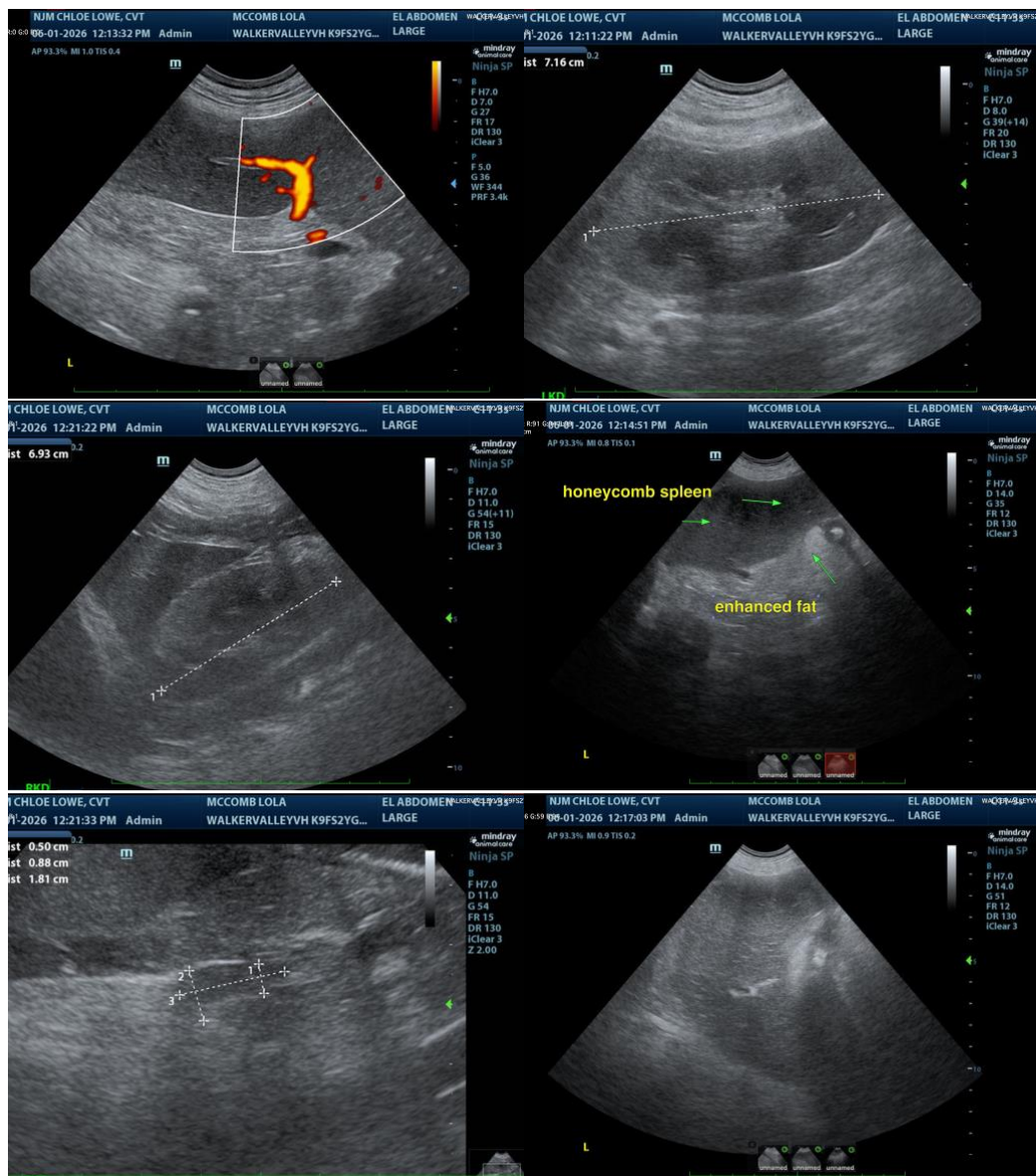
Dr. Barnhorst

INVOICE

37272

DATE

6/1/26





PATIENT

Lola McComb

SPECIES

Canine

BREED

Golden Retriever

SEX

Spayed Female

AGE

7 Years

WEIGHT

82 Pounds

INTERPRETED BY

Eric Lindquist, DMV,
 DABVP (CFM), Cert.
 IVUSS

IMAGING PERFORMED BY

Chloe Lowe, CVT

HOSPITAL NAME

Walker Valley VH

REFERRING VET

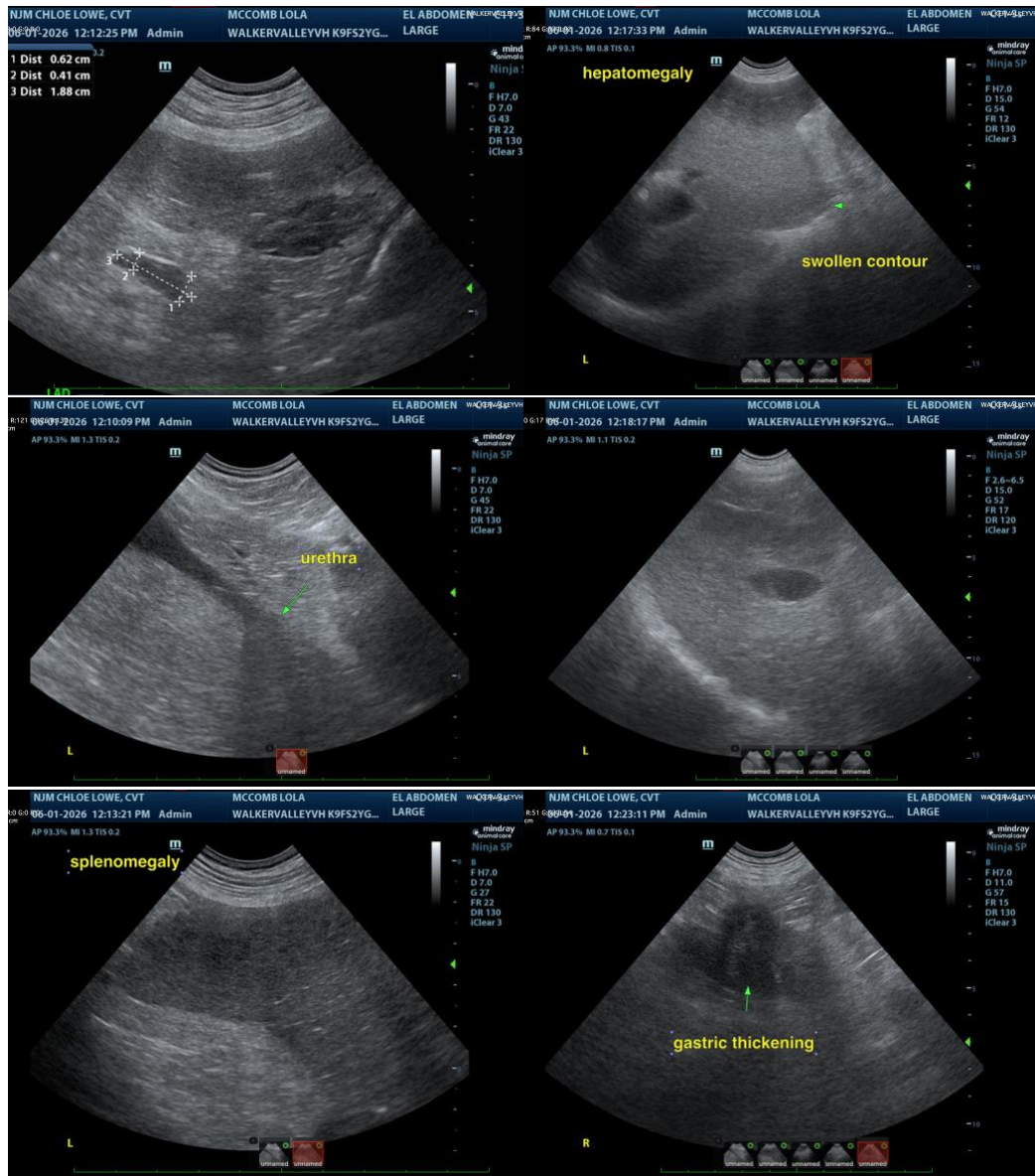
Dr. Barnhorst

INVOICE

37272

DATE

6/1/26

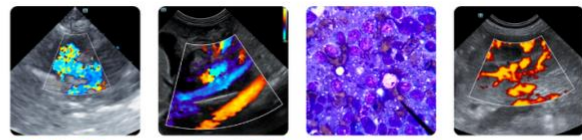


The information and recommendations provided are based on the images presented by the referring veterinarian/sonographer. No evaluation can be communicated regarding pathology that was not visible in the image/video clips provided.

Thank you for this referral. If the clinical or image interpretation does not parallel your findings or if I can be of any further assistance please contact me.

Eric Lindquist, DMV, DABVP(CFM), Cert. IVUSS,
 CEO, Owner, Founder -- SonoPath.com
info@SonoPath.com

Excerpt from the Curbside Guide: <https://sonopath.com/thecurbsideguide/>



PATIENT

Lola McComb

SPECIES

Canine

BREED

Golden Retriever

SEX

Spayed Female

AGE

7 Years

WEIGHT

82 Pounds

INTERPRETED BY

Eric Lindquist, DMV,
DABVP (CFM), Cert.
IVUSS

IMAGING PERFORMED BY

Chloe Lowe, CVT

HOSPITAL NAME

Walker Valley VH

REFERRING VET

Dr. Barnhorst

INVOICE

37272

DATE

6/1/26

FEVER OF UNKNOWN ORIGIN

DESCRIPTON Fever of unknown origin (FUO) is any fever greater than a few days duration in which the cause is not obvious on initial history and physical examination. Important etiologies are infectious disease, immune-mediated diseases, and neoplasia. The common causes of FUO were summarized concisely in a presentation at the American College of Veterinary Internal Medicine 2004 Forum as follows:

| Final Diagnosis | Bennett (Dogs & Cats) | Dunn and Dunn (Dogs Only) | Lunn (Dogs & 1 cat) | Total | Percent |
|----------------------------|-----------------------|---------------------------|---------------------|-------|---------|
| Infection | 21 | 16 | 10 | 47 | 28 |
| Immune | 18 | 22 | 6 | 46 | 27 |
| Bone Marrow Disease | 4 | 22 | 2 | 28 | 16 |
| Neoplasia (outside marrow) | 0 | 10 | 2 | 12 | 7 |
| Miscellaneous | 2 | 12 | 2 | 16 | 9 |
| No Diagnosis | 0 | 19 | 2 | 21 | 12 |
| TOTALS | 45 | 101 | 24 | 170 | 99 |

The types of infection diagnosed in this case series were varied, ranging from discospondylitis (8 cases), blastomycosis (6 cases), and bacterial endocarditis (4 cases), to leishmaniasis (1 case), prostatitis (1 case), and Ehrlichia canis infection (1 case); a multitude of other infectious causes also fell within the spectrum. Of the cases where immune-mediated disease was found, 44% had immune-mediated polyarthritis. Bone marrow diseases included myeloproliferative disease, myelodysplasia (8 cases), lymphocytic leukemia (8 cases), myeloma (3 cases), chronic granulocytic leukemia (3 cases), lymphoblastic leukemia, and malignant histiocytosis. The types of neoplasia located outside the bone marrow included lymphoma (6 cases), metastatic disease (2 cases), and neoplasms of the lung, spleen, and stomach. Finally, miscellaneous diseases included hypertrophic osteodystrophy (6 cases), meningitis (3 cases), portosystemic shunt (3 cases), lymphadenitis (2 cases), panosteitis, and intervertebral disc disease. Overall, the most common causes across all cases were polyarthritis (44 cases), lymphoid neoplasia (15 cases), discospondylitis (8 cases), myelodysplasia (8 cases), hypertrophic osteodystrophy (6 cases), and blastomycosis (6 cases).

CLINICAL SIGNS Animals usually present with either persistent or waxing and waning fevers ranging from 103–106 °F (39.5–41 °C). Other clinical signs depend on the underlying cause of the fever. Careful and thorough physical examination is required to assess potential causes. History and physical examination represent the first, best, and least expensive opportunity to localize the disease process causing the fever.

DIAGNOSTICS FUO etiologies are partly related to geography and thus, locale or travel history should factor into a practitioner’s diagnostic approach. A patient’s lifestyle may also provide clues regarding exposure to certain etiologic agents. Therefore, obtaining a thorough history can unveil important pieces of the diagnostic puzzle. Physical examination is especially important and should include an inspection of all accessible lymph nodes, palpation and movement of the joints, a fundic examination, a neurological evaluation, spinal and limb palpation and range of motion tests, and a rectal examination.

A minimum database should include a CBC reviewed by a clinical pathologist, as well as a biochemical profile and urinalysis and retroviral testing in cats. In areas where tick-borne disease is prevalent, in-house testing should be performed early. Advanced laboratory work can include urine culture, blood culture, and infectious disease panels (PCR and/or serology). In dogs, one may screen for the following infectious agents: Ehrlichia spp., Borrelia burgdorferi, Rocky Mountain Spotted Fever, Bartonella spp. (culture and PCR), and Leptospira spp. in cases of hepatic or renal involvement. In cats, one should evaluate for FeLV,



PATIENT

Lola McComb

SPECIES

Canine

BREED

Golden Retriever

SEX

Spayed Female

AGE

7 Years

WEIGHT

82 Pounds

INTERPRETED BY

Eric Lindquist, DMV,
DABVP (CFM), Cert.
IVUSS

IMAGING PERFORMED BY

Chloe Lowe, CVT

HOSPITAL NAME

Walker Valley VH

REFERRING VET

Dr. Barnhorst

INVOICE

37272

DATE

6/1/26

FIV, feline infectious peritonitis (FIP) virus, toxoplasmosis, Hemoplasma spp. (Mycoplasma), and Bartonella spp. (culture and PCR). Testing for Ehrlichia spp., Rickettsia spp., and Anaplasma phagocytophilum can also be considered. A fungal assay is indicated if the patient lives in or has had exposure to a region with a higher incidence of fungal disease. Other infectious disease tests may be performed depending on the geographical location of the pet. Screening for Brucella should be done in breeding dogs. Immune-mediated disease screening can include a Coombs test, a slide agglutination test (if the patient is anemic), and an antinuclear antibody (ANA) test. Immune disease is often a diagnosis of exclusion.

Imaging should include thoracic radiographs, abdominal ultrasound, and/or abdominal radiographs. Ultrasound can be very useful for assessing evidence of cholangiohepatitis, pyelonephritis, chronic urinary tract infection, abscess formation, peritonitis, and neoplasia. It also permits an examination of the intra-abdominal lymph nodes. An echocardiogram can offer assessment for vegetative endocarditis, whereas spinal radiographs offer assessment for discospondylitis. In cases where all other testing has proven negative and the patient has not responded to broad-spectrum antibiotics and supportive care, arthrocentesis should be considered to evaluate for septic joint disease, immune-mediated polyarthritis, and infectious disease. Finally, one can consider assessing the cerebrospinal fluid for meningoencephalitis, GME, and meningitis/arteritis. A bone marrow exam should be performed if blood dyscrasias are noted on the CBC.

TREATMENT Treatment of the fever depends entirely on the underlying cause. Ideally, a thorough diagnostic plan will yield a diagnosis that will guide the appropriate therapeutic course. However, if an exhaustive approach has not produced a definitive diagnosis and there is no response to broad-spectrum antibiotics, trial therapy with immunosuppressive agents such as prednisolone can be considered to treat presumed immune-mediated diseases. Given the potential for negative sequelae should an underlying infection be present, one must be certain that the investigation is thorough and monitor the patient's response carefully.

CONCLUSION If a documented fever has not responded to antibiotics, antipyretics, or general nursing care, it is important to obtain a diagnosis to guide more specific treatment. A systematic physical examination and thorough history-taking will help inform further diagnostics in addition to what is revealed by the minimum database.

REFERENCES

1. Battersby IA, Murphy KF, et al. Retrospective study of fever in dogs: laboratory testing, diagnoses and influence of prior treatment. J Small Anim Pract. 2006; 47: 370-376.
2. Flood J. The diagnostic approach to fever of unknown origin in cats. Compend Contin Educ Vet 2009; 31 (1): 26-31.
3. Flood J. The diagnostic approach to fever of unknown origin in dogs. Compend Contin Educ Vet 2009; 31 (1): 14-21.
4. Lappin MR. The role of blood borne pathogens in feline fever of unknown origin. Proceed-ings from the American College of Veterinary Internal Medicine, Denver, CO, June 15-18, 2011.
5. Lunn KF. Fever of unknown origin: a systematic approach to diagnosis. Compend Contin Educ Vet 2001; 23 (11): 976-92.
6. Lunn KF. Fever of unknown origin: appropriate choice of diagnostic tests. Proceedings from the American College of Veterinary Internal Medicine, Minneapolis, MN, June 9-12, 2004.