



PATIENT

Wilbur Small

SPECIES

Canine

BREED

Basset Hound

SEX

Male

AGE

12 years

WEIGHT

54.5 lbs

INTERPRETED BY

Eric Lindquist, DMV
DABVP, Cert. IVUSS

IMAGING PERFORMED BY

Chaley Hunt LVT

HOSPITAL NAME

Columbia AC

REFERRING VET

Dr. Baker

INVOICE

30837

DATE

6/1/22

PRESENTING CLINICAL SIGNS

History: Was seen on 5/7/22 for enlarged testicle. Prostate enlarged with firm nodule on the right caudal pole, left side of prostrate was larger than the right.
Abnormal PE/Chem/CBC/UA Results: Elevated thyroid, on thyroid medication.

ULTRASONOGRAPHIC EXAMINATION OF THE ABDOMEN

Urinary System

The **urinary bladder**, trigone, and pelvic urethra presented normal thicknesses and normal tone. The pelvic urethra was imaged 3.0 cm beyond the cystourethral junction. The ureters were not visible which is normal. No uroliths or sediment were visualized and anechoic urine was present. No evidence of inflammatory or neoplastic changes was noted. Ureteral papillae were normal.

The **prostate** was uniformly enlarged with lobar swelling appeared to impinge upon the urethra and mildly deviate the descending colon. The prostate was mildly irregular with disparity of the lobar size. The prostatic tissue was hyperechoic containing focal areas of decreased echogenicity. These changes are suggestive of either chronic inflammatory episodes, benign cystic pathology or both. Underlying neoplasia cannot be completely ruled-out but is lower on the differential list. This presentation is most consistent with benign prostatic hyperplasia with possible active prostatitis. Neutering or off-label Finasteride (Propecia) (0.1-0.5 mg/kg Sid) treatment is indicated +/- FNA or prostatic wash cytology and culture. The prostate measured 4.0 cm in width.

The **kidneys** revealed normal size and structure, corticomedullary definition and ratio for this age. The cortices presented largely uniform texture with normal echogenic relationship to liver and spleen. Medullary structure differed distinctly from the cortex and no evidence of pelvic dilation was present. The capsules were acceptably uniform without significant irregularities. A 2.0 cm cortical nodule was noted at the dorsal cortex of the left kidney. The right kidney measured 6.58 cm and the left kidney measured 7.31 cm.

Adrenal Glands

Both **adrenal glands** were visualized and recognized as having normal shape, size, position and echogenicity for this breed. The phrenic vasculature, glandular echogenicity and detail were unremarkable. Capsule, cortex, and medullary definition were normal for this age patient. The left adrenal gland measured 0.67 cm at the caudal pole and 0.57 cm at the cranial pole.

Spleen

The **spleen** in this patient was mildly enlarged with uniform parenchyma and was folded upon itself caudally. This is a positional variant and is not pathological. There was no evidence of significant disease.

Liver

The **liver** images submitted revealed subjectively normal liver size, contour, and structure. Parenchymal echogenicity was naturally coarse and hypoechoic to the spleen. Vascular and biliary tracts were of normal volume with no evidence of congestion. The gallbladder presented acceptably thin walls with primarily anechoic content. The cystic and common bile ducts were normal. No pathological hepatic



PATIENT

lymphadenopathy was evident. No overt structural evidence of inflammatory, infiltrative or regenerative pathology was evident.

Wilbur Small

SPECIES

Gastrointestinal

Canine

Examination of the **gastrointestinal tract** revealed a stomach and intestine free of stasis, of normal wall thickness, acceptable curvilinear mural detail, and peristaltic activity. Small and large intestine demonstrated normal luminal chyme and stool consistency respectively. No obstructive or overt infiltrative disease was noted. No associated abnormal lymphatic activity was noted.

BREED

Basset Hound

Pancreas

SEX

The base and limbs of the **pancreas** were observed to be largely isoechoic to surrounding omental fat. Some parenchymal remodeling, however, with mild deviation from curvilinear normalcy was observed. Pancreatic duct and capsular irregularities were present consistent with age related changes. If pain upon imaging (+ Murphy sign) was present or if the patient is focally painful in subxiphoid palpation then low-grade smoldering chronic pancreatitis should be suspected.

Male

AGE

12 years

ULTRASONOGRAPHIC FINDINGS

WEIGHT

BPH prostate with left renal nodule. Complicated cyst, abscessation or neoplasia event is all possible.

54.5 lbs

INTERPRETED BY

INTERPRETATION OF THE FINDINGS & FURTHER RECOMMENDATIONS

Eric Lindquist, DMV
DABVP, Cert. IVUSS

25-gauge FNA is indicated after coagulation panel. Definition of the left renal nodule is recommended first followed by neutering and should prove curative regarding the prostatic presentation.

IMAGING PERFORMED BY

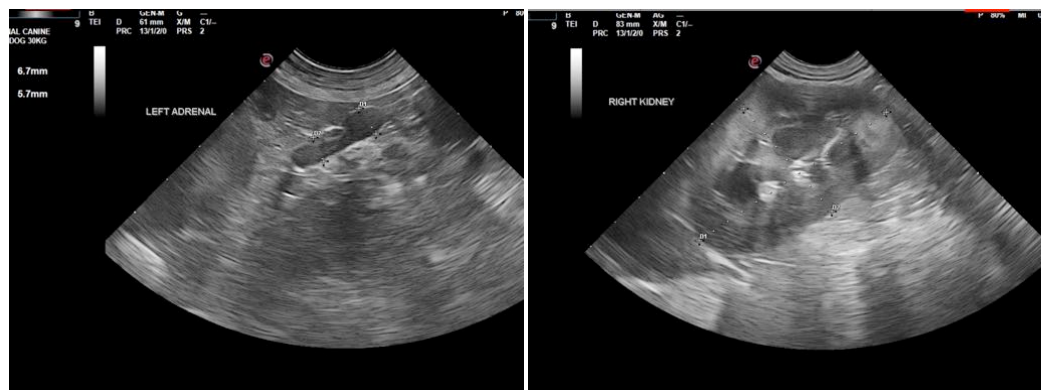Chaley Hunt LVT

HOSPITAL NAME

Columbia AC

REFERRING VET

Dr. Baker



INVOICE

30837

DATE

6/1/22



PATIENT

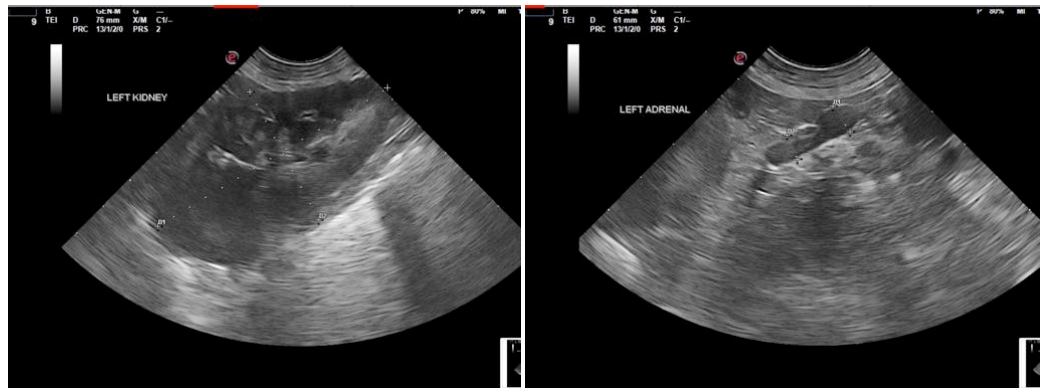Wilbur Small

SPECIES

Canine

BREED

Basset Hound



SEX

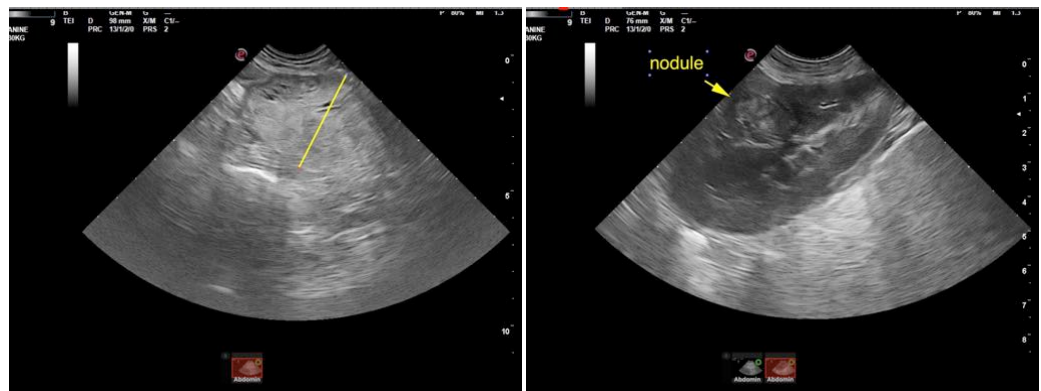
Male

AGE

12 years

WEIGHT

54.5 lbs



INTERPRETED BY

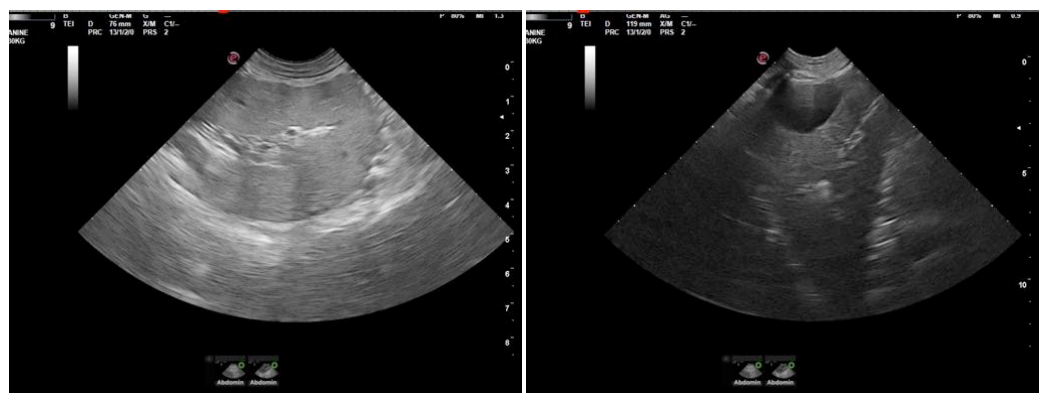
Eric Lindquist, DMV
DABVP, Cert. IVUS

IMAGING PERFORMED BY

Chaley Hunt LVT

HOSPITAL NAME

Columbia AC



REFERRING VET

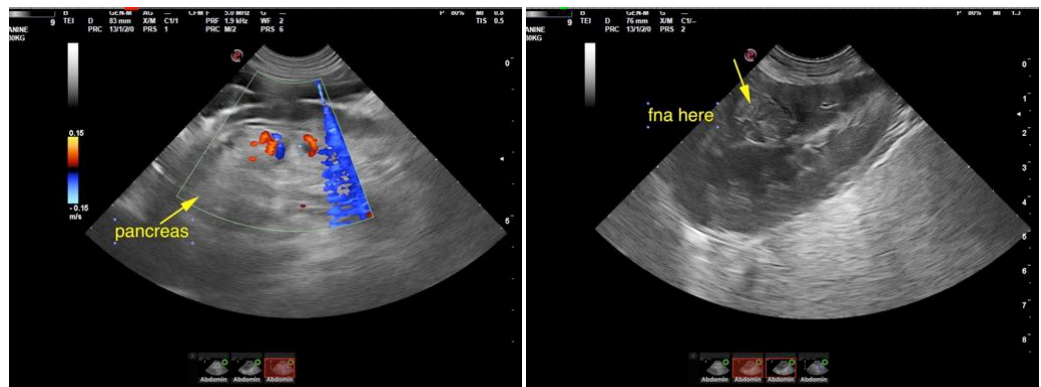
Dr. Baker

INVOICE

30837

DATE

6/1/22





PATIENT

Wilbur Small

The information and recommendations provided are based on the images presented by the referring veterinarian/sonographer. No evaluation can be communicated regarding pathology that was not visible in the image/video clips provided.

SPECIES

Canine

Thank you for this referral. If the clinical or image interpretation does not parallel your findings or if I can be of any further assistance please contact me.

BREED

Basset Hound

Eric Lindquist, DMV, DABVP, Cert. IVUSS, CEO of SonoPath.com
info@SonoPath.com

SEX

Male

AGE

12 years

WEIGHT

54.5 lbs

INTERPRETED BY

Eric Lindquist, DMV
DABVP, Cert. IVUSS

**IMAGING
PERFORMED BY**

Chaley Hunt LVT

HOSPITAL NAME

Columbia AC

REFERRING VET

Dr. Baker

INVOICE

30837

DATE

6/1/22