



**PATIENT**

Shane Murphy

**SPECIES**

Canine

**BREED**

Chihuahua X

**SEX**

Neutered Male

**AGE**

7 Years 9 Months

**WEIGHT**

11.2 Pounds

**INTERPRETED BY**

Eric Lindquist, DMV

DABVP, Cert. IVUSS

**IMAGING PERFORMED BY**

Jessica Green

**HOSPITAL NAME**

Stanglein Vet Clinic

**REFERRING VET**

Dr. Nathaniel Stanglein

**INVOICE**

38158

**DATE**

6/1/22

**PRESENTING CLINICAL SIGNS**

CHF/Mitral valve, suspect collapsing trachea, recurrent pancreatitis, stable mild cough, more recently reduced activity and appetite, softer stools-resolve on metronidazole... Currently on Metronidazole, PRN gabapentin, theophylline, lasix, benazepril, pimobendan  
Abnormal PE/Chem/CBC/UA Results: last BW showed mild azotemia, mild elevation in renal values (on lasix) and a new elevation in both ALT/ALP.

**ULTRASONOGRAPHIC EXAMINATION OF THE ABDOMEN**

**Urinary System**

The **urinary bladder**, trigone, and pelvic urethra presented normal thicknesses and normal tone. The ureters were not visible which is normal. No uroliths or sediment were visualized and anechoic urine was present. No evidence of inflammatory or neoplastic changes were noted. Ureteral papillae were normal.

The **kidneys** revealed largely normal size and structure, corticomedullary definition and ratio (cortex 1/3 of medulla) were essentially maintained with some age-related loss of curvilinear patterns regarding the capsule and C/M junction. The cortices presented largely uniform texture with some increased echogenicity expected for his age patient. Medullary structure differed distinctly from that of the cortex and no evidence of pelvic dilation was present. The right kidney measured 4.24 cm. The left kidney measured 3.82 cm.

**Adrenal Glands**

Both **adrenal glands** were visualized and recognized as having normal shape, size, position and echogenicity for this breed. The phrenic vasculature, glandular echogenicity and detail were unremarkable. Capsule, cortex, and medullary definition were normal for this age patient. The left adrenal gland measured 1.49 cm x 0.65 cm. The right adrenal gland measured 1.36 cm x 0.58 cm.

**Spleen**

The **spleen** presented a smooth homogeneous parenchyma hyperechoic to liver and renal cortical parenchyma. The capsule was smooth without noticeable expansion or deviation from within the spleen or adjacent pathology. The splenic vasculature demonstrated normal volume without signs of congestion or thrombosis. No sonographic evidence of acute or chronic inflammatory, neoplastic, or infarctual changes were noted.

**Liver**

The **liver** images from right and left intercostal as well as subcostal views revealed subjectively normal liver size, contour, and structure. Some age-related parenchymal remodeling was noted but likely not clinically significant at this time. Vascular and biliary tracts were of normal volume and no evidence of congestion was noted. The gallbladder presented some dependent debris with essentially normal contour. The cystic and common bile ducts were normal. No overt evidence of active inflammatory, infiltrative or regenerative pathology was noted but should be paired with current or past LE elevations regarding any clinical significance to this presentation. The hepatic lymph nodes were unremarkable.

**Gastrointestinal**

Examination of the **gastrointestinal tract** revealed a stomach and intestine free of stasis, of normal wall thickness, acceptable curvilinear mural detail, and peristaltic activity. Small and large intestine demonstrated normal luminal chyme and stool consistency respectively. No obstructive or overt infiltrative disease was noted. No associated abnormal lymphatic activity was noted.



**PATIENT**

Shane Murphy

**Pancreas**

**SPECIES**

Canine

The **pancreas** was hyperechoic with coarse architecture and areas of remodeling. History of pancreatitis +/- low-grade inflammation suspected.

**BREED**

Chihuahua X

**ULTRASONOGRAPHIC FINDINGS**

- Possible low-grade pancreatic inflammation
- Mild to moderate degenerative renal changes

**SEX**

Neutered Male

**INTERPRETATION OF THE FINDINGS & FURTHER RECOMMENDATIONS**

No evidence of significant disease. Subxiphoid palpation recommended to assess for any discomfort that may be playing a role in the reduced appetite. Long-term management with hydrolyzed diet would be indicated. The kidneys appear to have only mild to moderate degenerative changes. Enrofloxacin/Metronidazole combination over a 10 day period, transition to hydrolyzed diet long term, and reassessment of the clinical signs would be suggested from an empirical standpoint.

**AGE**

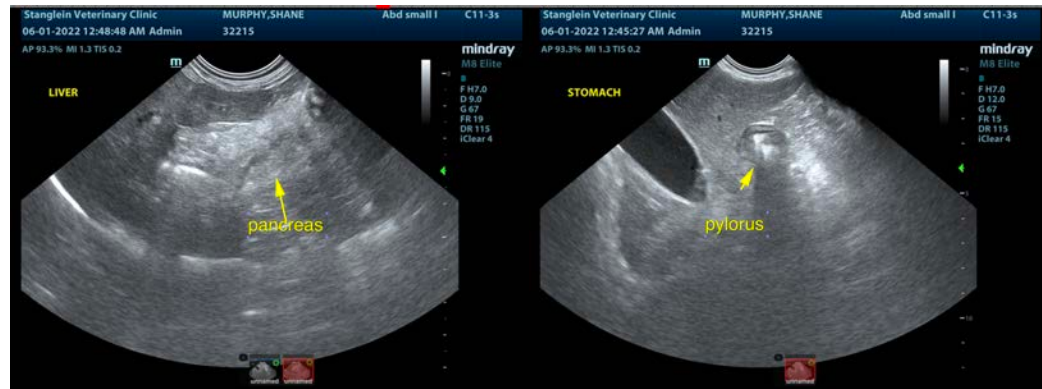
7 Years 9 Months

**WEIGHT**

11.2 Pounds

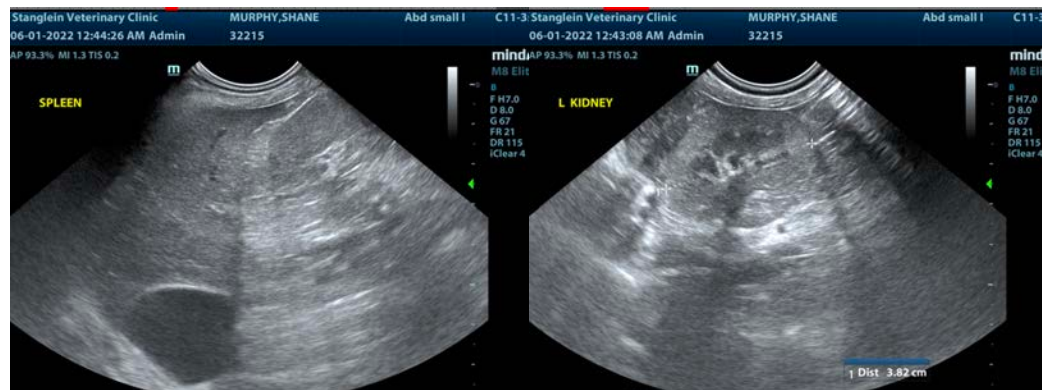
**INTERPRETED BY**

Eric Lindquist, DMV  
DABVP, Cert. IVUSS



**IMAGING PERFORMED BY**

Jessica Green



**HOSPITAL NAME**

Stanglein Vet Clinic

**REFERRING VET**

Dr. Nathaniel Stanglein

**INVOICE**

38158

**DATE**

6/1/22



**PATIENT**

Shane Murphy

**SPECIES**

Canine

**BREED**

Chihuahua X

**SEX**

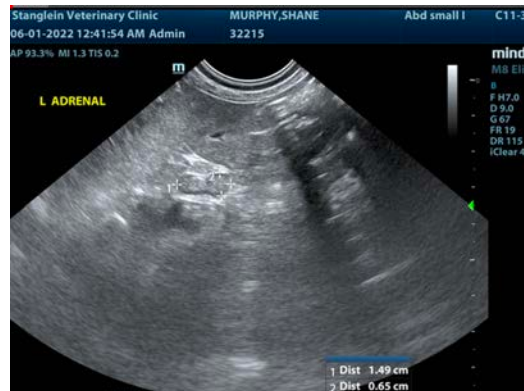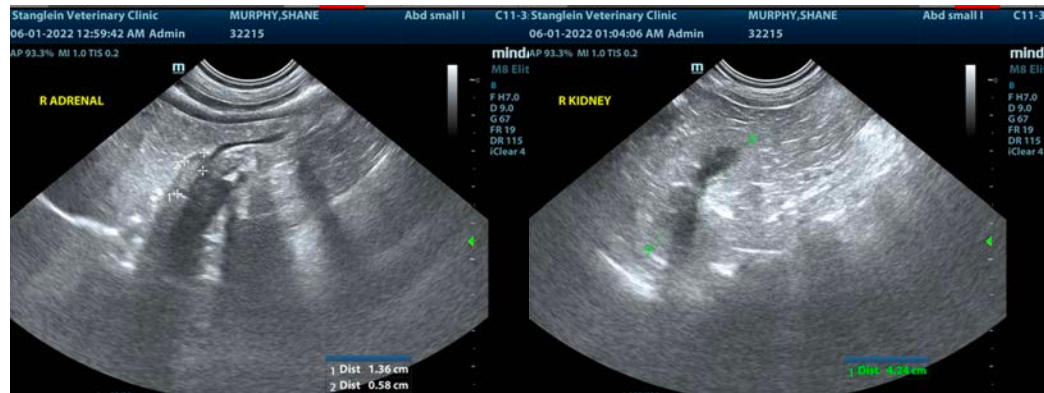
Neutered Male

**AGE**

7 Years 9 Months

**WEIGHT**

11.2 Pounds



**INTERPRETED BY**

Eric Lindquist, DMV

DABVP, Cert. IVUSS

**IMAGING PERFORMED BY**

Jessica Green

**HOSPITAL NAME**

Stanglein Vet Clinic

**REFERRING VET**

Dr. Nathaniel Stanglein

**INVOICE**

38158

**DATE**

6/1/22

The information and recommendations provided are based on the images presented by the referring veterinarian/sonographer. No evaluation can be communicated regarding pathology that was not visible in the image/video clips provided.

Thank you for this referral. If the clinical or image interpretation does not parallel your findings or if I can be of any further assistance please contact me.

Eric Lindquist, DMV, DABVP, Cert. IVUSS, CEO of SonoPath.com

[info@SonoPath.com](mailto:info@SonoPath.com)