**DATE**

6/1/22

PRESENTING CLINICAL SIGNS

Elevated liver values found in February, Rimadyl was discontinued. Liver values continue to increase.

Current Medications: Denamarin advanced 1 SID Since January

Glucosamine BID (Cosequin DS for several years), Rimadyl 75 mg 1 SID- BID 11/21-2/22 DISCONTINUED,

Tramadol 50 mg 1 BID-TID

Lab Results: See attached.

Date of Previous IntraPet Ultrasound: No previous.

Sedation: Not required to complete full diagnostic ultrasound.

Stat Report: Not requested.

Imaging Performed By: Rachel Brillhart, RDMS.

PATIENT

Henry Sawyer

SPECIES

Canine

BREED

Labradoodle

SEX

Neutered male

AGE

4/7/12

WEIGHT

73.5 lbs

INTERPRETED BYEric Lindquist, DMV
DABVP, Cert. IVUSS**HOSPITAL NAME**Animal Medical Clinic
of Dulvaney Valley**REFERRING VET**

Dr. Chrest

INVOICE

30832

ULTRASONOGRAPHIC EXAMINATION OF THE ABDOMEN**Urinary System**

The **urinary bladder**, trigone, and pelvic urethra presented normal thicknesses and normal tone. The ureters were not visible which is normal. No uroliths or sediment were visualized and anechoic urine was present. No evidence of inflammatory or neoplastic changes was noted. Ureteral papillae were normal.

The **kidneys** revealed largely normal size and structure, corticomedullary definition and ratio (cortex 1/3 of medulla) were essentially maintained with some age-related loss of curvilinear patterns regarding the capsule and C/M junction. The cortices presented largely uniform texture with some increased echogenicity expected for this age patient. Medullary structure differed distinctly from that of the cortex. Slight pyelectasia was noted in the kidneys. In the right kidney it measured 0.24 cm and 0.19 cm in the left kidney. The right kidney measured 6.79 cm. The left kidney measured 6.98 cm.

Adrenal Glands

Both **adrenal glands** were visualized and recognized as having normal shape, size, position and echogenicity for this breed. The phrenic vasculature, glandular echogenicity and detail were unremarkable. Capsule, cortex, and medullary definition were normal for this age patient. The right adrenal gland measured 2.81 x 0.77 cm at the cranial pole and 0.57 cm at the caudal pole. The left adrenal gland measured 3.17 x 0.63 cm at the caudal pole and 0.78 cm at the caudal pole.

Spleen

The **spleen** presented a smooth homogeneous parenchyma hyperechoic to liver and renal cortical parenchyma. The capsule was smooth without noticeable expansion or deviation from within the spleen or adjacent pathology. The splenic vasculature demonstrated normal volume without signs of congestion or thrombosis. No sonographic evidence of acute or chronic inflammatory, neoplastic, or infarctual changes was noted.

Liver

The **liver** revealed increased portal markings with coarse architecture and mild, irregular contour. Multifocal, hypoechoic nodular changes were noted and mildly disruptive measuring 2.7 cm. Increased portal markings were present. The gallbladder presented acceptably thin walls with primarily anechoic content. The cystic and common bile ducts were normal. No pathological hepatic lymphadenopathy was evident. No overt structural evidence of inflammatory, infiltrative or regenerative pathology was evident.

Gastrointestinal

The upper **duodenum** appeared mildly thickened with some echogenic remodeling. History of duodenitis is likely. The small intestines and colon were unremarkable.

Pancreas

The **pancreas** revealed heterogenous, mixed echogenic changes with remodeling. Some level of low-grade inflammation is suspected.

ULTRASONOGRAPHIC FINDINGS

Significant hepatic remodeling with nodular changes. Chronic fibrosing hepatopathy with nodular hyperplasia. Bile acid profile and core liver biopsy is indicated.

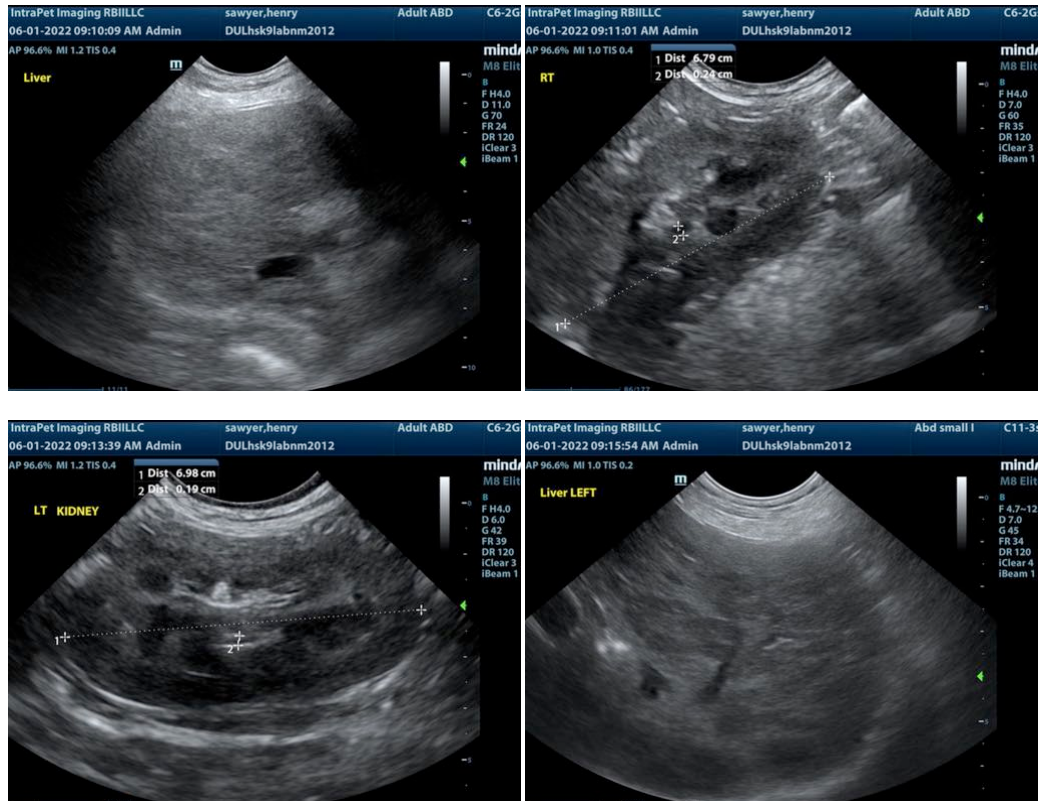
Mild to moderate degenerative renal changes.

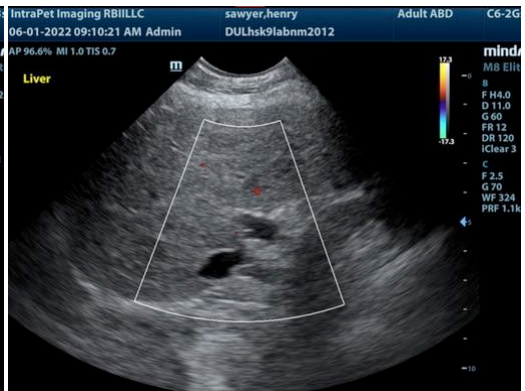
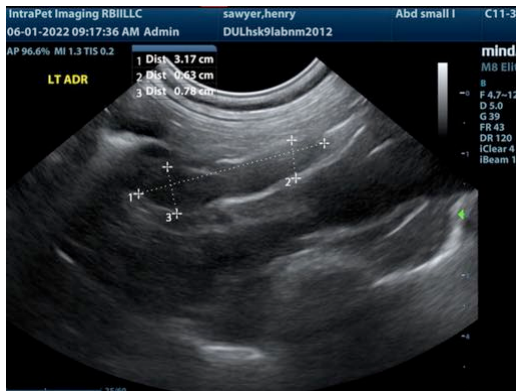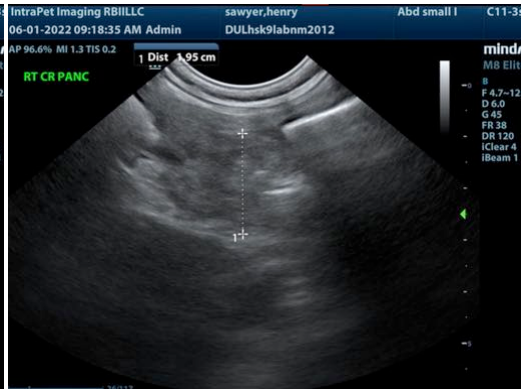
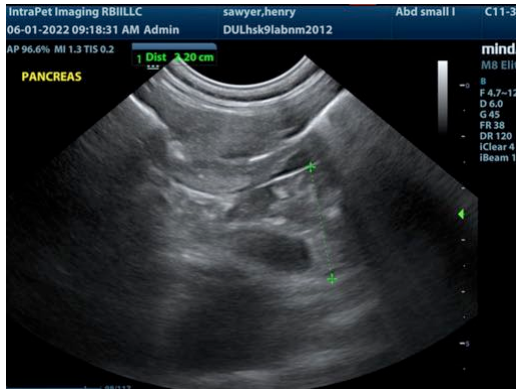
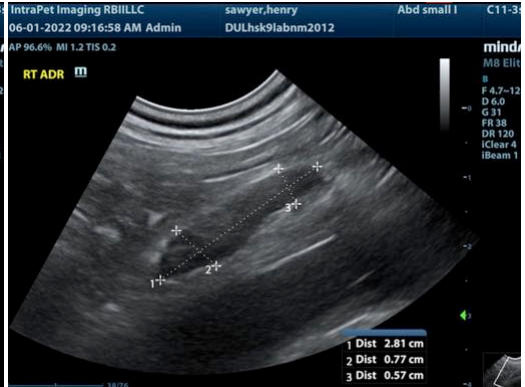
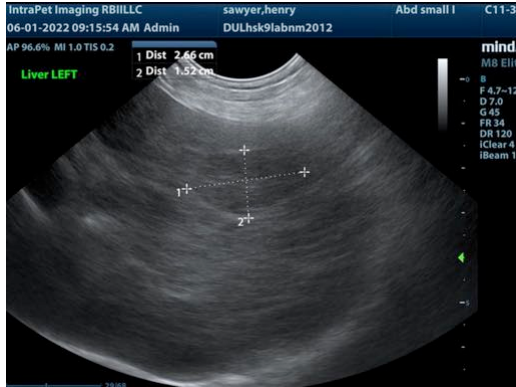
Pancreatic remodeling, potential low-grade inflammation.

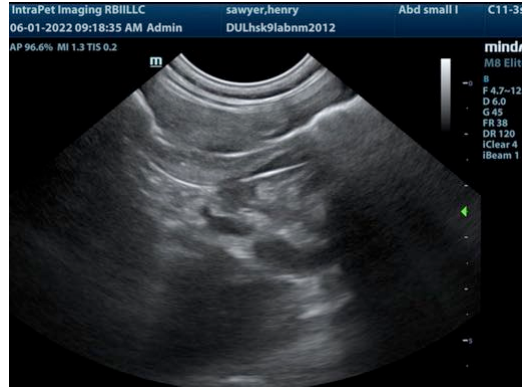
INTERPRETATION OF THE FINDINGS & FURTHER RECOMMENDATIONS

FNA is warranted to assess inflammatory cell type. There was no overt evidence or suspicion of neoplasia.

Hepatic sampling is recommended for refinement of therapy. Otherwise, general nutraceuticals, Enrofloxacin and Metronidazole combination could be considered.







The information and recommendations provided are based on the images presented by the referring veterinarian. No evaluation can be communicated regarding pathology that was not visible in the image/video clips provided.

Thank you for this referral. If the clinical or image interpretation does not parallel your findings or if I can be of any further assistance please contact me.

Eric Lindquist, DMV, DABVP, Cert. IVUSS, CEO of SonoPath.com
Eric.Lindquist@SonoPath.com