



PATIENT

Arlo Bashkin

PRESENTING CLINICAL SIGNS

Pt clinically healthy. Using pt to practice technique.

SPECIES

Feline

ULTRASONOGRAPHIC EXAMINATION OF THE ABDOMEN

Urinary System

The **urinary bladder**, trigone, and pelvic urethra presented normal thicknesses and normal tone. The ureters were not visible which is normal. A minor amount of suspended debris was present. No evidence of inflammatory or neoplastic changes were noted. Ureteral papillae were normal. The pelvic urethra was imaged 2.0 cm beyond the cystourethral junction.

BREED

DLH

SEX

Neutered Male

The **kidneys** revealed largely normal size and structure, corticomedullary definition and ratio (cortex 1/3 of medulla) were essentially maintained with some age-related loss of curvilinear patterns regarding the capsule and C/M junction. The cortices presented largely uniform texture with some increased echogenicity expected for his age patient. Medullary structure differed distinctly from that of the cortex and no evidence of pelvic dilation was present. The kidneys measured 3.5 cm each.

AGE

11 Years

Adrenal Glands

The regions of the **adrenal glands** were unremarkable.

WEIGHT

15.3 Pounds

Spleen

The **spleen** presented a smooth homogeneous parenchyma hyperechoic to liver and renal cortical parenchyma. The capsule was smooth without noticeable expansion or deviation from within the spleen or adjacent pathology. The splenic vasculature demonstrated normal volume without signs of congestion or thrombosis. No sonographic evidence of acute or chronic inflammatory, neoplastic, or infarctual changes were noted.

INTERPRETED BY

Eric Lindquist, DMV

Liver

DABVP, Cert. IVUSS

The **liver** images submitted revealed subjectively normal liver size, contour, and structure. Parenchymal echogenicity was naturally coarse and hypoechoic to the spleen. Vascular and biliary tracts were of normal volume with no evidence of congestion. The gallbladder presented acceptably thin walls with primarily anechoic content. The cystic and common bile ducts were normal. No pathological hepatic lymphadenopathy was evident. No overt structural evidence of inflammatory, infiltrative or regenerative pathology was evident.

IMAGING PERFORMED BY

Dr. Claudia Giuliani

HOSPITAL NAME

The Pet Hospital of Stratford

Gastrointestinal

The **gastrointestinal** presentation revealed mild uniform prominence of the gastric mucosa as well as areas of "ropey" small intestinal wall with slight disruption of the normal 1:3 muscularis/mucosal ratio. Slight areas of 1:1 muscularis/mucosal ratio noted. The intestinal submucosa was slightly irregular, thickened and hyperechoic suggestive of low grade, chronic disease. No concerning lymphadenopathy was visible. No evidence of obstruction was present. Chronic inflammatory bowel disease is likely with a low possibility of an early neoplastic event such as lymphoma. Full thickness tissue biopsies via open laparotomy, ideally guided by intraoperative ultrasound in order to obtain the most representative mural sample, would be necessary to rule out this possibility.

REFERRING VET

Dr. Claudia Giuliani

INVOICE

38179

DATE

6/1/22



PATIENT

Arlo Bashkin

SPECIES

Feline

BREED

DLH

SEX

Neutered Male

AGE

11 Years

WEIGHT

15.3 Pounds

INTERPRETED BY

Eric Lindquist, DMV
DABVP, Cert. IVUSS

IMAGING PERFORMED BY

Dr. Claudia Giuliani

HOSPITAL NAME

The Pet Hospital of
Stratford

REFERRING VET

Dr. Claudia Giuliani

INVOICE

38179

DATE

6/1/22

Pancreas

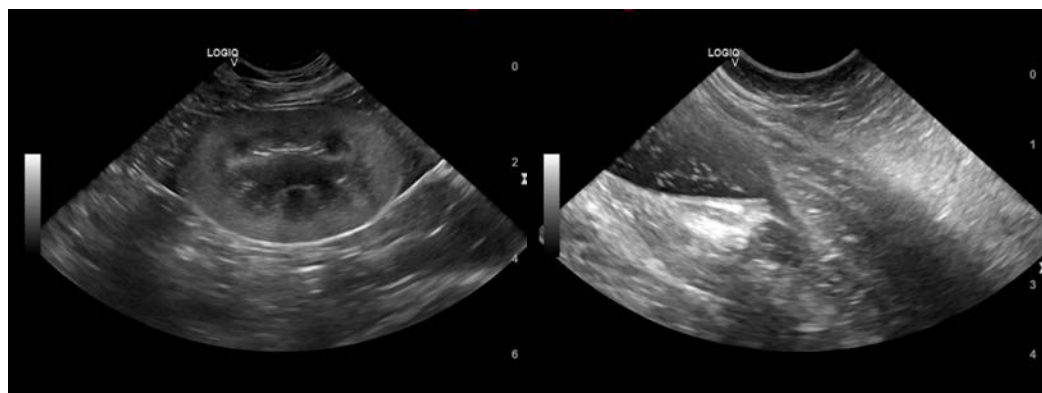
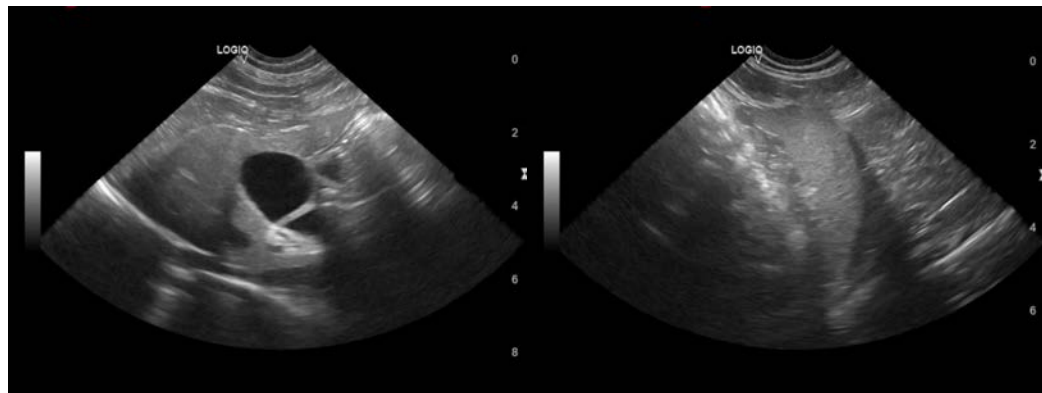
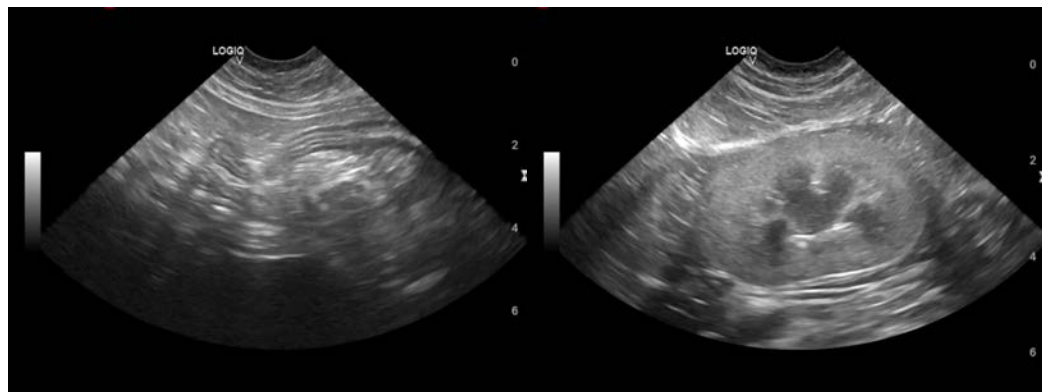
The base and limbs of the **pancreas** were observed to be largely isoechoic to surrounding omental fat. Pancreatic duct and capsular contour were acceptably normal and parenchyma respected normal curvilinear patterns. No overt evidence of active inflammatory or neoplastic disease was noted.

ULTRASONOGRAPHIC FINDINGS

- Unremarkable abdomen with minor intestinal thickening

INTERPRETATION OF THE FINDINGS & FURTHER RECOMMENDATIONS

No evidence of significant disease. Largely expected changes for this age patient.





PATIENT

Arlo Bashkin

The information and recommendations provided are based on the images presented by the referring veterinarian/sonographer. No evaluation can be communicated regarding pathology that was not visible in the image/video clips provided.

SPECIES

Feline

Thank you for this referral. If the clinical or image interpretation does not parallel your findings or if I can be of any further assistance please contact me.

Eric Lindquist, DMV, DABVP, Cert. IVUSS, CEO of SonoPath.com

info@SonoPath.com

BREED

DLH

SEX

Neutered Male

AGE

11 Years

WEIGHT

15.3 Pounds

INTERPRETED BY

Eric Lindquist, DMV

DABVP, Cert. IVUSS

IMAGING PERFORMED BY

Dr. Claudia Giuliani

HOSPITAL NAME

The Pet Hospital of
Stratford

REFERRING VET

Dr. Claudia Giuliani

INVOICE

38179

DATE

6/1/22