



PATIENT PRESENTING CLINICAL SIGNS

Spirit Smith History: Recheck Echo Current meds: Pimo 2.5 mg, 1.5-tab BID, Benazepril 5mg BID

SPECIES ULTRASONOGRAPHIC EXAMINATION OF THE HEART

Canine

BREED

American Eskimo

SEX

Spayed Female

AGE

9 Years

WEIGHT

27 Pounds

CANINE CARDIAC PARAMETERS	MR VMAX (m/s)	TR VMAX (m/s)	LA/AO (Boon method)	LA/AO (Heart Base; Swe)	FS (%)	EF (%)	EPSS (cm)
NORMAL PARAMETER	4.5-5.5	<2.7	1.3	<1.3	28-40	40-100	<0.6
PATIENT	6.0	3.2	1.4	1.69	47	80	NM
CANINE CARDIAC PARAMETERS	HR (BPM)	AV VMAX (m/s)	PV MAX (m/s)	BODY WEIGHT (kg)	LA 2D short axis Base view (cm)	LVIDd Avg; 2D and m-mode short axis (cm)	LVIDs Avg; 2D and m-mode short axis (cm)
NORMAL PARAMETER	50-100	0.7-1.7	0.7-1.6				
PATIENT	131	1.25	1.38	--	2.8	2.73	--

Cardiac Presentation

The cardiac presentation presented largely normalized volumes with prolapsed anterior mitral valve leaflet. Contractility was adequate. All four chambers appeared to be largely contained in volume. Left atrial and left ventricular dilation have largely normalized. Mitral and tricuspid insufficiency with mild pulmonary hypertension noted. No pericardial or pleural effusion were noted and no arrhythmogenic activity was noted. Trivial aortic insufficiency was noted.

ULTRASONOGRAPHIC FINDINGS

- Stable valvular disease on current protocol

INTERPRETATION OF THE FINDINGS & FURTHER RECOMMENDATIONS

Significant improvement has occurred from the prior sonogram. If the patient is currently coughing, then this would not be cardiogenic in nature. I recommend continuation of the current cardiac protocol. Recheck echo in 6-12 months or earlier if clinical signs initiate.

INTERPRETED BY

Eric Lindquist, DMV DABVP, Cert. IVUSS

IMAGING PERFORMED BY

Val Shumskaya

HOSPITAL NAME

Sumit Dog & Cat

REFERRING VET

Dr. Vogler

INVOICE

22427

DATE

5/9/23



PATIENT

Spirit Smith

SPECIES

Canine

BREED

American Eskimo

SEX

Spayed Female

AGE

9 Years

WEIGHT

27 Pounds

INTERPRETED BY

Eric Lindquist, DMV
DABVP, Cert. IVUSS

IMAGING PERFORMED BY

Val Shumskaya

HOSPITAL NAME

Sumit Dog & Cat

REFERRING VET

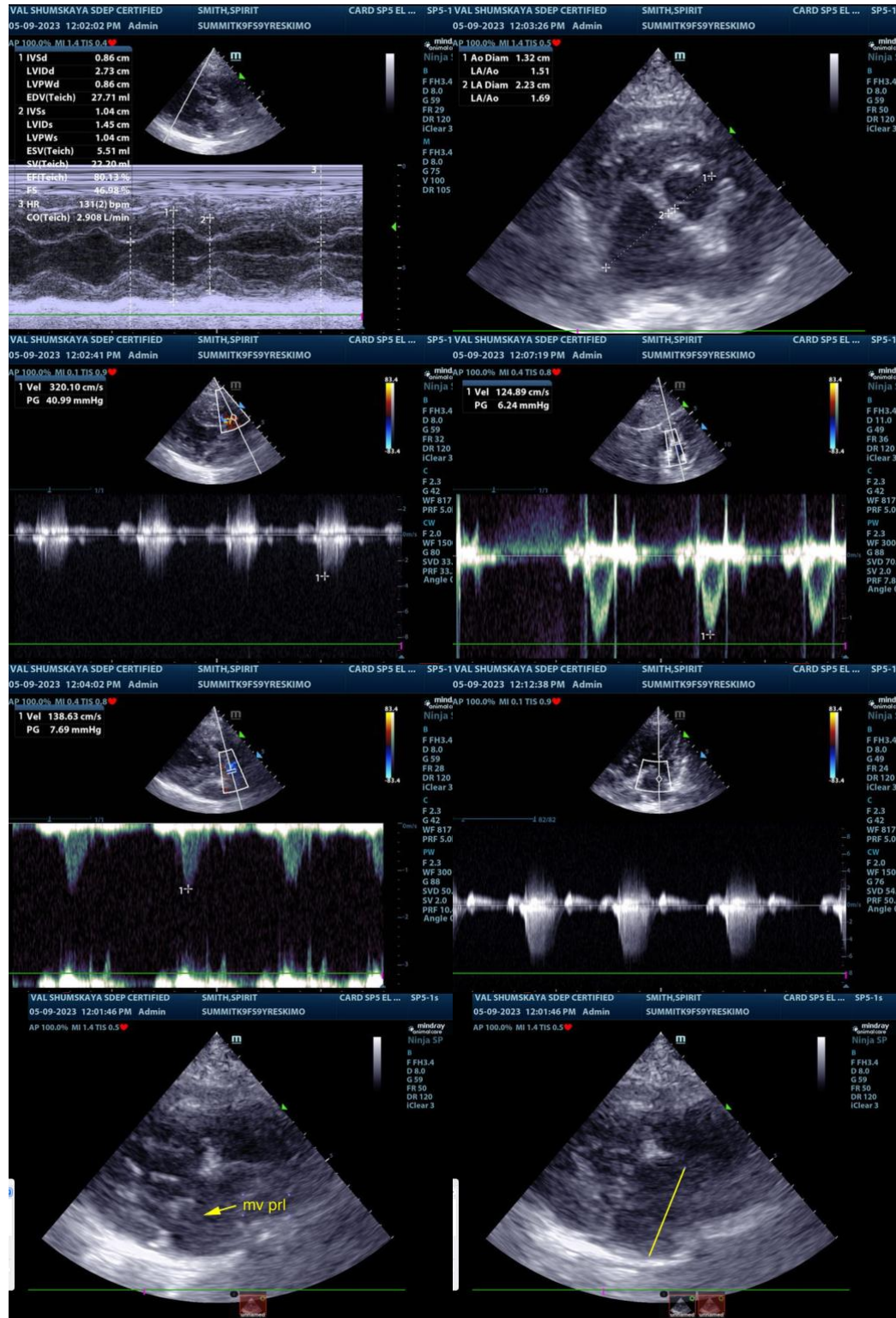
Dr. Vogler

INVOICE

22427

DATE

5/9/23



The information and recommendations provided are based on the images presented by the referring veterinarian. No evaluation can be communicated regarding pathology that was not visible in the image/video clips provided.



PATIENT

Spirit Smith

Thank you for this referral. If the clinical or image interpretation does not parallel your findings or if I can be of any further assistance please contact me.

SPECIES

Canine

Eric Lindquist, DMV, DABVP, Cert. IVUSS, CEO of SonoPath.com
info@SonoPath.com

BREED

American Eskimo

SEX

Spayed Female

AGE

9 Years

WEIGHT

27 Pounds

INTERPRETED BY

Eric Lindquist, DMV
DABVP, Cert. IVUSS

**IMAGING
PERFORMED BY**

Val Shumskaya

HOSPITAL NAME

Sumit Dog & Cat

REFERRING VET

Dr. Vogler

INVOICE

22427

DATE

5/9/23