

**DATE**

05/09/2022

PRESENTING CLINICAL SIGNS

Current Medications: Denamarin since 8/16/21.
Lab Results: Fasted bloodwork 2/12/2022: ALT 256U/L (10-125)
ALP 1015 U/L (23-212), GGT WNL.
Date of Previous IntraPet Ultrasound: No previous.
Sedation: Not required to complete full diagnostic ultrasound.
Stat Report: Not requested.
Imaging Performed By: Rachel Brillhart, RDMS.

PATIENT

Mason Vergara

SPECIES

Canine

ULTRASONOGRAPHIC EXAMINATION OF THE ABDOMEN**BREED**

Bichon Frise

Urinary System**SEX**

NM

The urinary bladder, trigone, and pelvic urethra presented normal thicknesses and normal tone. The ureters were not visible which is normal. Sand accumulation up to 5 mm was present in the proximal urethra with 1 cm of sand in the cystourethral junction.

AGE

5 years

The kidneys revealed normal size and structure, corticomedullary definition and ratio for this age. The cortices presented largely uniform texture with normal echogenic relationship to liver and spleen. Slight pinpoint mineralization was noted. Medullary structure differed distinctly from the cortex and no evidence of pelvic dilation was present. The capsules were acceptably uniform without significant irregularities. The left kidney measured 4.57 cm in length. The right kidney measured 4.38 cm in length.

WEIGHT

9.07 kg

Adrenal Glands**INTERPRETED BY**Eric Lindquist, DMV
DABVP, Cert. IVUSS

Both adrenal glands were visualized and recognized as having normal shape, size, position and echogenicity for this breed. The phrenic vasculature, glandular echogenicity and detail were unremarkable. Capsule, cortex, and medullary definition were normal for this age patient. The left adrenal gland measured 2.32 cm in length by 0.49 cm caudal pole width by 0.5 cm cranial pole width. The right adrenal gland measured 2.06 cm in length by 0.65 cm caudal pole width by 0.52 cm cranial pole width.

HOSPITAL NAME

Banfield Colombia

Spleen

The spleen presented a smooth homogeneous parenchyma hyperechoic to liver and renal cortical parenchyma. The capsule was smooth without noticeable expansion or deviation from within the spleen or adjacent pathology. The splenic vasculature demonstrated normal volume without signs of congestion or thrombosis. No sonographic evidence of acute or chronic inflammatory, neoplastic, or infarctual changes were noted.

REFERRING VET

Dr. Shobe

Liver**INVOICE**

10552ag

The liver images submitted revealed minor swelling with fairly uniform parenchyma. The gallbladder presented acceptably thin walls with primarily anechoic content. The cystic and common bile ducts were normal. No pathological hepatic lymphadenopathy was evident.

Gastrointestinal

Examination of the gastrointestinal tract revealed a stomach and intestine free of stasis, of normal wall thickness, acceptable curvilinear mural detail, and peristaltic activity. Small and large intestine demonstrated

normal luminal chyme and stool consistency respectively. No obstructive or overt infiltrative disease was noted. No associated abnormal lymphatic activity was noted.

Pancreas

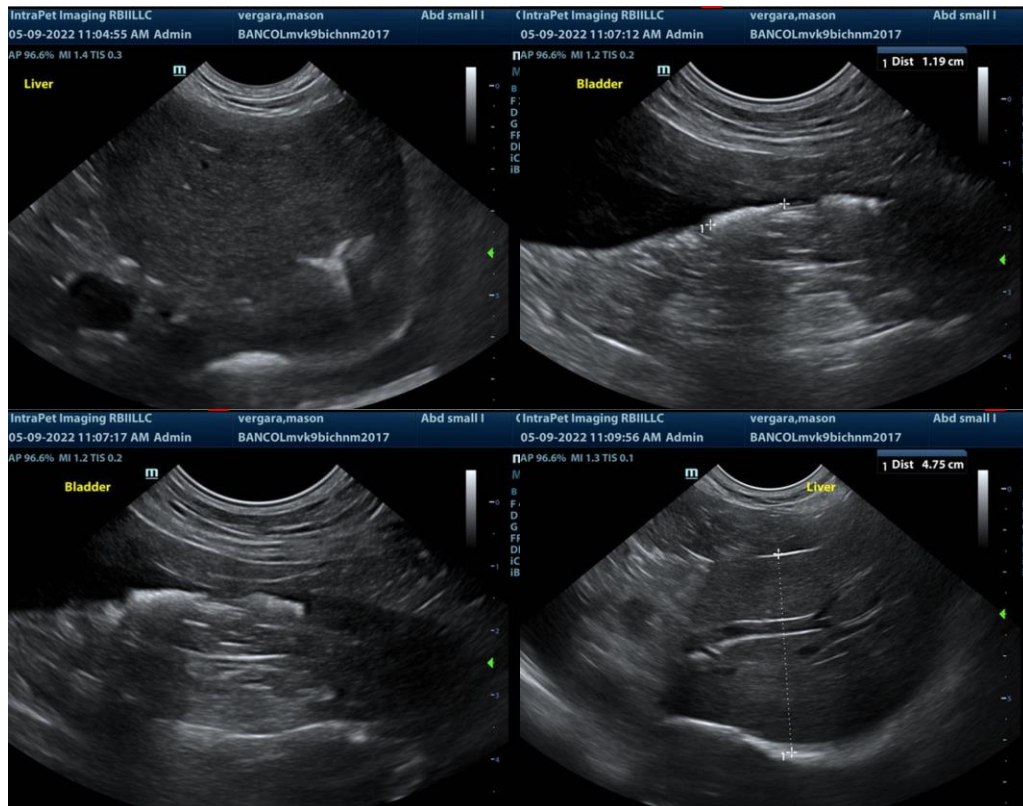
The base and limbs of the pancreas were observed to be largely isoechoic to surrounding omental fat. Pancreatic duct and capsular contour were acceptably normal and parenchyma respected normal curvilinear patterns. No overt evidence of active inflammatory or neoplastic disease was noted.

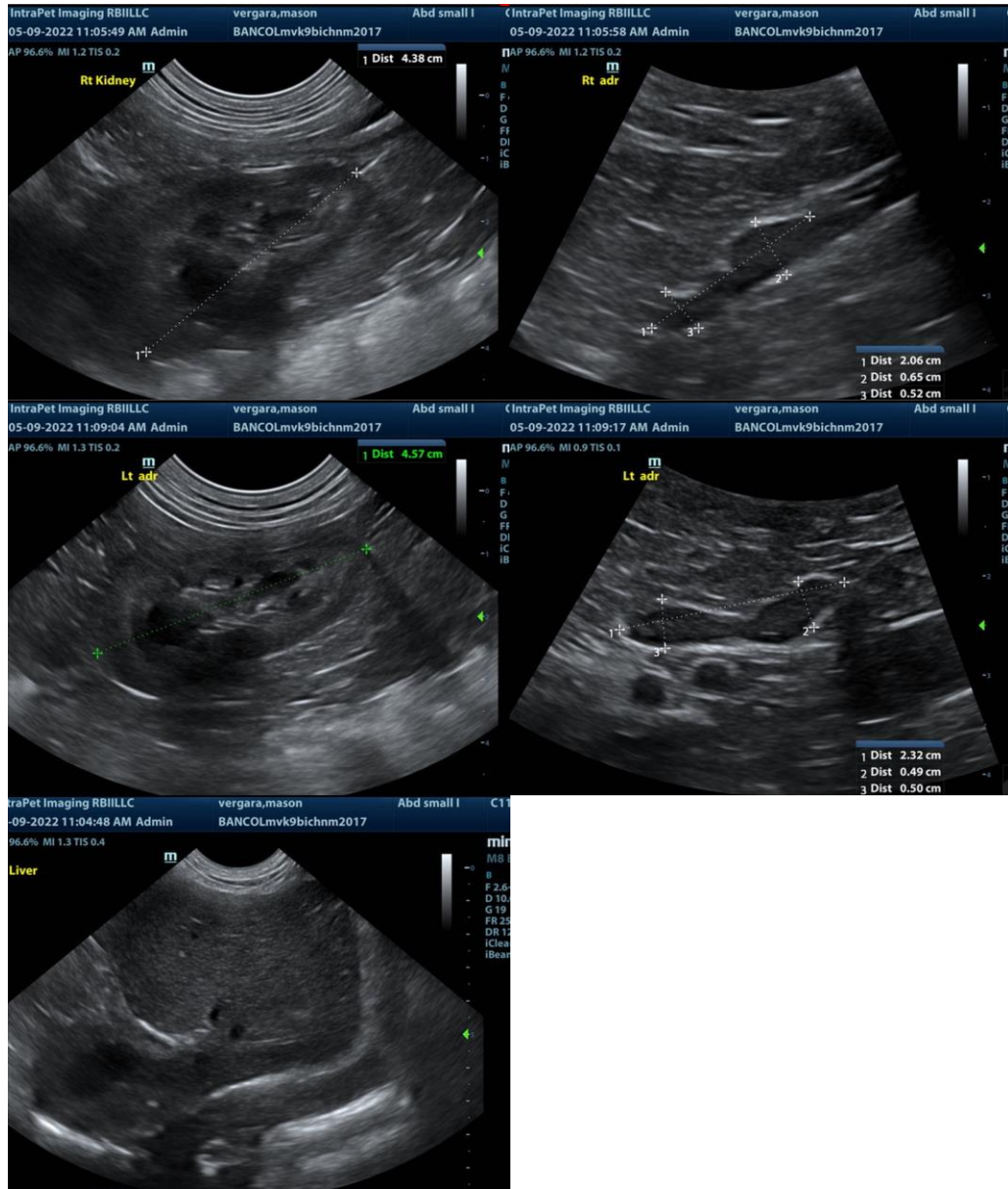
ULTRASONOGRAPHIC FINDINGS

- Benign hepatopathy
- Urethra and bladder sand
- Slight pinpoint renal mineralization

INTERPRETATION OF THE FINDINGS & FURTHER RECOMMENDATIONS

A FNA of the liver could be considered for further definition. A full urinalysis is warranted. Obstruction is a significant potential in this case. A cystostomy with sand analysis, normal and retrograde flushing is recommended. The liver presentation does not present a contraindication for any anesthetic procedures necessary. This patient is likely passing calculi periodically.





The information and recommendations provided are based on the images presented by the referring veterinarian. No evaluation can be communicated regarding pathology that was not visible in the image/video clips provided.

Thank you for this referral. If the clinical or image interpretation does not parallel your findings or if I can be of any further assistance please contact me.

Eric Lindquist, DMV, DABVP, Cert. IVUSS, CEO of SonoPath.com
Eric.Lindquist@SonoPath.com