



PATIENT

Goldie Carroll

SPECIES

Canine

BREED

Shih Tzu

SEX

FS

AGE

12 years

WEIGHT

9.6 pounds

INTERPRETED BY

Eric Lindquist, DMV
DABVP, Cert. IVUSS

IMAGING PERFORMED BY

Dr. John Boley

HOSPITAL NAME

Animal Hospital of
Colorado Springs

REFERRING VET

Dr. John Boley

INVOICE

10549ag

DATE

05/09/2022

PRESENTING CLINICAL SIGNS

History: Goldie has a history of elevated liver enzymes. There is no signs of PU/PD. There is no signs of excessive panting. She is eating well and there are no signs of weight loss.
Abnormal PE/Chem/CBC/UA Results: 4-21-22 AST-67; ALT-266; ALP-597

ULTRASONOGRAPHIC EXAMINATION OF THE ABDOMEN

Urinary System

The urinary bladder, trigone, and pelvic urethra presented normal thicknesses and normal tone. The ureters were not visible which is normal. No uroliths or sediment were visualized and anechoic urine was present. No evidence of inflammatory or neoplastic changes were noted. Ureteral papillae were normal.

The kidneys revealed largely normal size and structure, corticomedullary definition and ratio (cortex 1/3 of medulla) were essentially maintained with some minor age-related loss of curvilinear patterns regarding the capsule and C/M junction. The cortices presented largely uniform texture with some increased echogenicity expected for his age patient. Medullary structure differed distinctly from that of the cortex and no evidence of pelvic dilation was present.

The left kidney measured 3.3 cm in length. The right kidney measured 3.3 cm in length.

Adrenal Glands

No evident pathology in the area of the right and left adrenal glands.

Spleen

The spleen presented a smooth homogeneous parenchyma hyperechoic to liver and renal cortical parenchyma. The capsule was smooth without noticeable expansion or deviation from within the spleen or adjacent pathology. The splenic vasculature demonstrated normal volume without signs of congestion or thrombosis. No sonographic evidence of acute or chronic inflammatory, neoplastic, or infarctual changes were noted.

Liver

The liver images from right and left intercostal as well as subcostal views revealed subjectively normal liver size, contour, and structure. Some minor age-related parenchymal remodeling was noted but likely not clinically significant at this time. Vascular and biliary tracts were of normal volume and no evidence of congestion was noted. The gallbladder presented some dependent debris with essentially normal contour. The cystic and common bile ducts were normal. No overt evidence of active inflammatory, infiltrative or regenerative pathology was noted but should be paired with current or past LE elevations regarding any clinical significance to this presentation. The hepatic lymph nodes were unremarkable.

Gastrointestinal

Examination of the gastrointestinal tract revealed a stomach and intestine free of stasis, of normal wall thickness, acceptable curvilinear mural detail, and peristaltic activity. Small and large intestine demonstrated normal luminal chyme and stool consistency respectively. No obstructive or overt infiltrative disease was noted. No associated abnormal lymphatic activity was noted.



PATIENT

Goldie Carroll

Pancreas

SPECIES

Canine

BREED

Shih Tzu

SEX

FS

AGE

12 years

WEIGHT

9.6 pounds

INTERPRETED BY

Eric Lindquist, DMV
DABVP, Cert. IVUSS

IMAGING PERFORMED BY

Dr. John Boley

HOSPITAL NAME

Animal Hospital of
Colorado Springs

REFERRING VET

Dr. John Boley

INVOICE

10549ag

DATE

05/09/2022

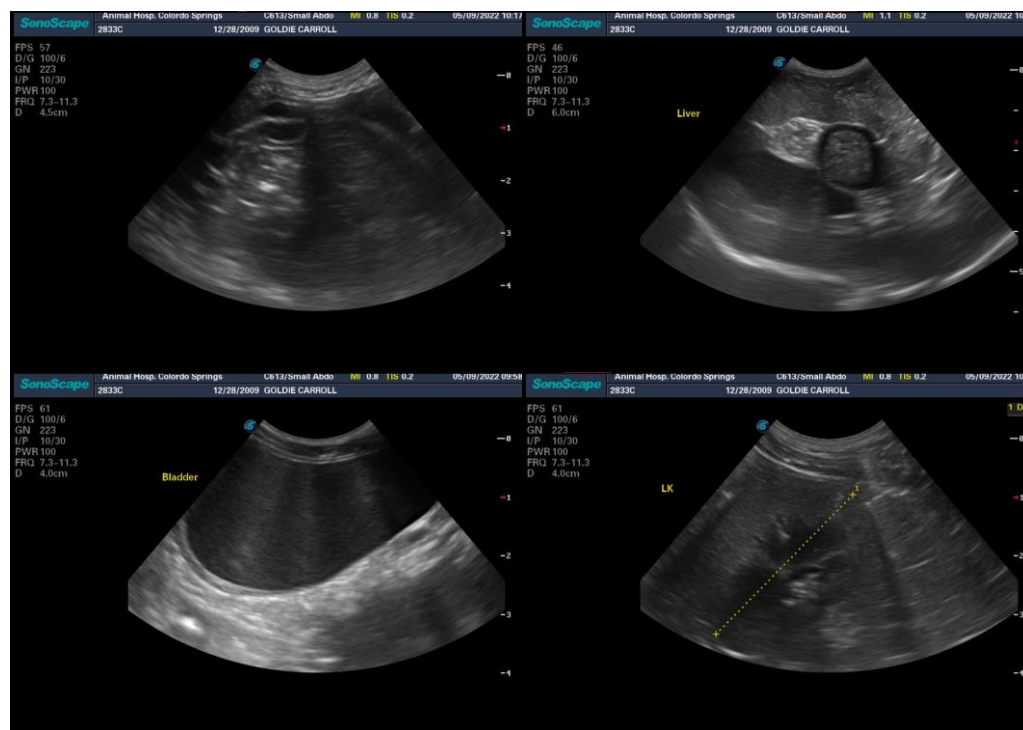
The base and limbs of the pancreas were observed to be largely isoechoic to surrounding omental fat. Pancreatic duct and capsular contour were acceptably normal, and parenchyma respected normal curvilinear patterns. No overt evidence of active inflammatory or neoplastic disease was noted.

ULTRASONOGRAPHIC FINDINGS

- Structurally unremarkable abdomen
- Age related hepatic changes

INTERPRETATION OF THE FINDINGS & FURTHER RECOMMENDATIONS

Overall, no evidence of structural abdominal pathology was noted. A FNA of the liver could be considered for further definition.





PATIENT

Goldie Carroll

SPECIES

Canine

BREED

Shih Tzu

SEX

FS

AGE

12 years

WEIGHT

9.6 pounds

INTERPRETED BY

Eric Lindquist, DMV
DABVP, Cert. IVUSS

**IMAGING
PERFORMED BY**

Dr. John Boley

HOSPITAL NAME

Animal Hospital of
Colorado Springs

REFERRING VET

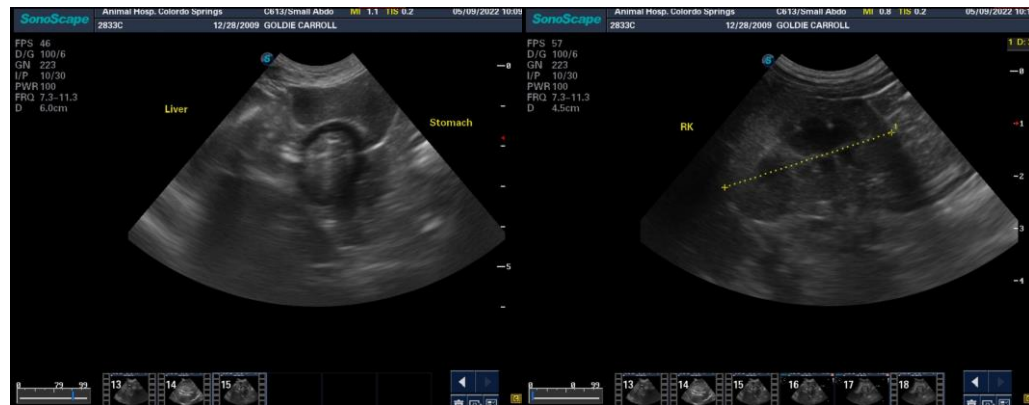Dr. John Boley

INVOICE

10549ag

DATE

05/09/2022



The information and recommendations provided are based on the images presented by the referring veterinarian. No evaluation can be communicated regarding pathology that was not visible in the image/video clips provided.

Thank you for this referral. If the clinical or image interpretation does not parallel your findings or if I can be of any further assistance please contact me.

Eric Lindquist, DMV, DABVP, Cert. IVUSS, CEO of SonoPath.com
Eric.Lindquist@SonoPath.com