



PATIENT	PRESENTING CLINICAL SIGNS
Clowie Montuoro	gastritis, got into fried rice
SPECIES	ULTRASONOGRAPHIC EXAMINATION OF THE ABDOMEN
Canine	Urinary System
BREED	The urinary bladder , trigone, and pelvic urethra presented normal thicknesses and normal tone. The ureters were not visible which is normal. No uroliths or sediment were visualized and anechoic urine was present. No evidence of inflammatory or neoplastic changes were noted. Ureteral papillae were normal.
Rat Terrier	
SEX	The kidneys revealed normal size and structure, corticomedullary definition and ratio for this age. The cortices presented largely uniform texture with normal echogenic relationship to liver and spleen. Medullary structure differed distinctly from the cortex and no evidence of pelvic dilation was present. The capsules were acceptably uniform without significant irregularities. The right kidney measured 3.6 cm. The left kidney measured 3.72 cm.
Spayed Female	
AGE	Adrenal Glands
1 Year	Both adrenal glands were visualized and recognized as having normal shape, size, position and echogenicity for this breed. The phrenic vasculature, glandular echogenicity and detail were unremarkable. Capsule, cortex, and medullary definition were normal for this age patient. The right adrenal gland measured 1.64 cm x 0.81 cm at the cranial pole and 0.57 cm at the caudal pole. The left adrenal gland measured 1.20 cm x 0.45 cm at the caudal pole and 0.44 cm at the cranial pole.
WEIGHT	Spleen
8 Pounds	The spleen presented a smooth homogeneous parenchyma hyperechoic to liver and renal cortical parenchyma. The capsule was smooth without noticeable expansion or deviation from within the spleen or adjacent pathology. The splenic vasculature demonstrated normal volume without signs of congestion or thrombosis. No sonographic evidence of acute or chronic inflammatory, neoplastic, or infarctual changes were noted.
INTERPRETED BY	Liver
Eric Lindquist, DMV	The liver images submitted revealed subjectively normal liver size, contour, and structure. Parenchymal echogenicity was naturally coarse and hypoechoic to the spleen. Vascular and biliary tracts were of normal volume with no evidence of congestion. The gallbladder presented acceptably thin walls with primarily anechoic content. The cystic and common bile ducts were normal. No pathological hepatic lymphadenopathy was evident. No overt structural evidence of inflammatory, infiltrative or regenerative pathology was evident.
DABVP, Cert. IVUSS	
IMAGING PERFORMED BY	Gastrointestinal
Jenn	The pylorus revealed a 1.0 cm shadowing structure, non-obstructive. Minor amount of chyme present otherwise. The small intestine and colon were unremarkable.
HOSPITAL NAME	Pancreas
Rockaway AH	The base and limbs of the pancreas were observed to be largely isoechoic to surrounding omental fat. Pancreatic duct and capsular contour were acceptably normal and parenchyma respected normal curvilinear patterns. No overt evidence of active inflammatory or neoplastic disease was noted.
REFERRING VET	
Dr. Maniar	
INVOICE	
37536	
DATE	
5/9/22	



PATIENT

Clowie Montuoro

ULTRASONOGRAPHIC FINDINGS

- Normal abdomen with 1.0 cm pyloric structure – probable medication or similar.

SPECIES

Canine

INTERPRETATION OF THE FINDINGS & FURTHER RECOMMENDATIONS

Oral medication history should be considered, non-obstructive. Supportive care should prove effective. No evidence of visceral GI disease from a structural standpoint.

BREED

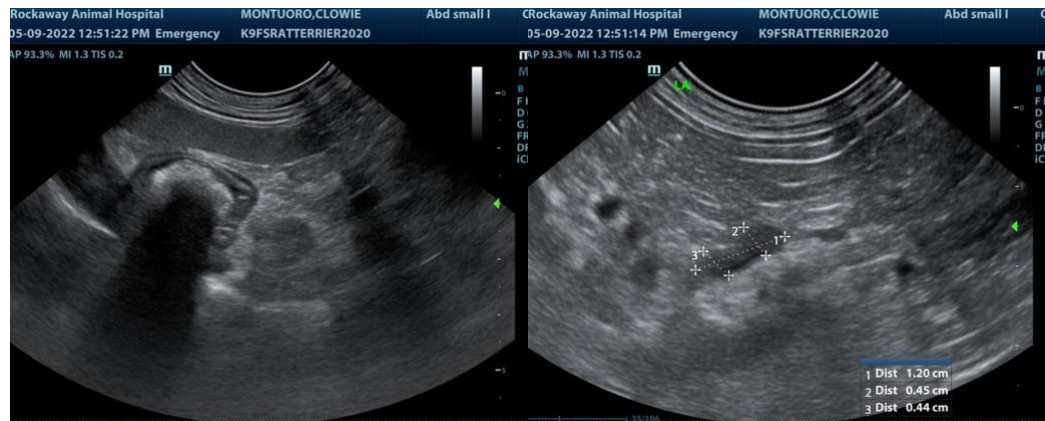
Rat Terrier

SEX

Spayed Female

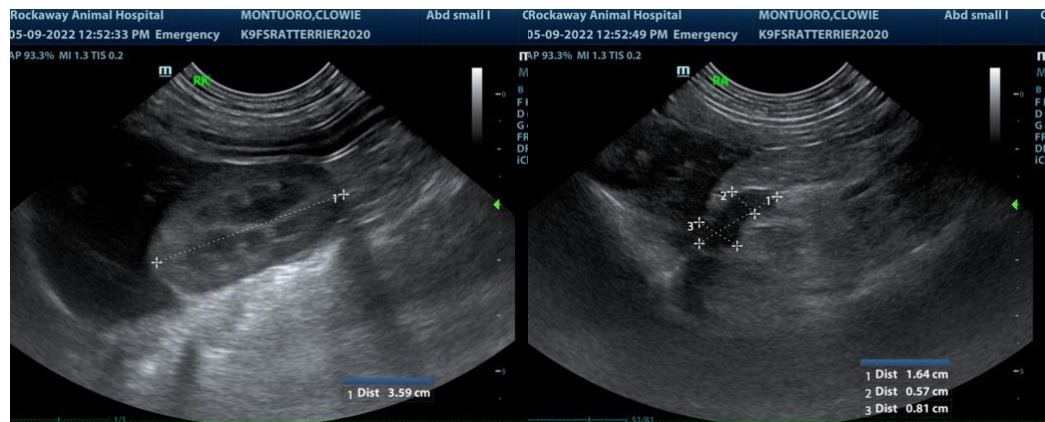
AGE

1 Year



WEIGHT

8 Pounds



INTERPRETED BY

Eric Lindquist, DMV

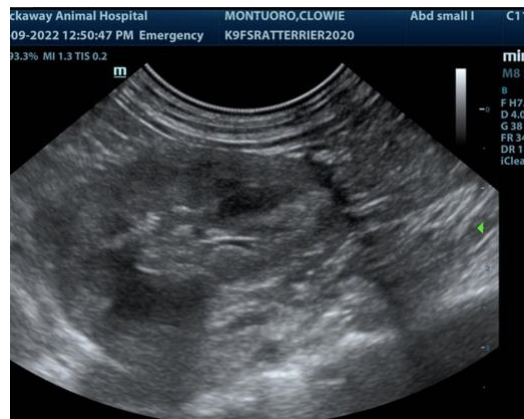
DABVP, Cert. IVUSS

IMAGING PERFORMED BY

Jenn

HOSPITAL NAME

Rockaway AH



REFERRING VET

Dr. Maniar

INVOICE

37536

DATE

5/9/22



PATIENT

Clowie Montuoro

The information and recommendations provided are based on the images presented by the referring veterinarian/sonographer. No evaluation can be communicated regarding pathology that was not visible in the image/video clips provided.

SPECIES

Canine

Thank you for this referral. If the clinical or image interpretation does not parallel your findings or if I can be of any further assistance please contact me.

BREED

Rat Terrier

Eric Lindquist, DMV, DABVP, Cert. IVUSS, CEO of SonoPath.com

SEX

Spayed Female

info@SonoPath.com

AGE

1 Year

WEIGHT

8 Pounds

INTERPRETED BY

Eric Lindquist, DMV

DABVP, Cert. IVUSS

IMAGING PERFORMED BY

Jenn

HOSPITAL NAME

Rockaway AH

REFERRING VET

Dr. Maniar

INVOICE

37536

DATE

5/9/22