



## PATIENT

Eve Schafer

## SPECIES

Rabbit

## BREED

Polish

## SEX

Spayed Female

## AGE

10 Years 4 Months

## WEIGHT

1.35 kg

## INTERPRETED BY

Eric Lindquist, DVM,  
DABVP, Cert. IVUSS

## IMAGING PERFORMED BY

Holly

## HOSPITAL NAME

All Pet Medical Center

## REFERRING VET

Agnes Rupley, DVM

## INVOICE

37015

## DATE

5/8/26

## PRESENTING CLINICAL SIGNS

History: Cardiac Silhouette is subjectively enlarged on chest x-rays

## ULTRASONOGRAPHIC EXAMINATION OF THE HEART

RABBIT CARDIAC PARAMETERS	BODY WEIGHT (kg)	HR (BPM)	IVSd (cm)	LVIDd (cm)	LVWd (cm)	FS (%)	EF (%)
<b>NORMAL PARAMETER</b>	-----	150-240	0.3-0.6	1.0-2.1	0.25-0.6	35-67	80-100
<b>PATIENT</b>	1.35	220	0.25	1.1	0.27	50	--
FELINE CARDIAC PARAMETERS	LA/AO (M-mode)	LA/AO HEART BASE (Sisson)	LAD LA MAX 4 Chamber		LVOT VEL. (m/s)	RVOT VEL. (m/s)	IVRT (m/)
<b>NORMAL PARAMETER</b>	<1.5	1.6	0.7-1.7		<1.6	<1.3	40-60
<b>PATIENT</b>	1.3	1.4	--		--	--	NM

Adapted from June Boon, Veterinary Echocardiography, 1998  
Sisson D et al. JVIM 1991; 5: 232, Jacobs et al. Am J Vet Res 1985; 46:1705

## Cardiac Presentation

The echocardiogram in this patient demonstrated normal **left atrial** size based on 3 separate LA measurements. The cranial and caudal **mitral** valve leaflets presented normal linear structure and kinetics. The **left ventricle** presented normal thicknesses with linear contour and was not dilated nor restricted. The **myocardium** presented normal echogenicity without subjective evidence of significant fibrotic or ischemic disease. **Contractility** of the ventricular walls was adequate and in normal range for this patient evidenced by the fractional shortening measurement and subjective evaluation of the different regions and angles of the myocardium. The **left ventricular outflow** tract demonstrated normal laminar flow and subjective structural integrity. The **right atrium** and auricle revealed normal size, structure and content. No evidence of masses was noted or chamber overload. **Tricuspid** valvular assessment demonstrated adequate linear morphology and kinetics. The **right ventricle** was of normal size (1/3 diameter of LV), chordae structure, myocardial echogenicity and thickness. **Pulmonic** tract assessment revealed normal valve structure, laminar flow, and diameter (approx. 1:1 pa/ao ratio). No visible **pericardial** or free pleura fluid was noted or extra cardiac pathology in the visible planes. The cranial **mediastinum and pericardial regions** were free of masses in the visible window. A large amount of thoracic fat was noted in this patient.

## ULTRASONOGRAPHIC FINDINGS

- Structurally unremarkable heart



**PATIENT**

Eve Schafer

**SPECIES**

Rabbit

**BREED**

Polish

**SEX**

Spayed Female

**AGE**

10 Years 4 Months

**WEIGHT**

1.35 kg

**INTERPRETED BY**

Eric Lindquist, DVM,  
DABVP, Cert. IVUSS

**IMAGING PERFORMED BY**

Holly

**HOSPITAL NAME**

All Pet Medical Center

**REFERRING VET**

Agnes Rupley, DVM

**INVOICE**

37015

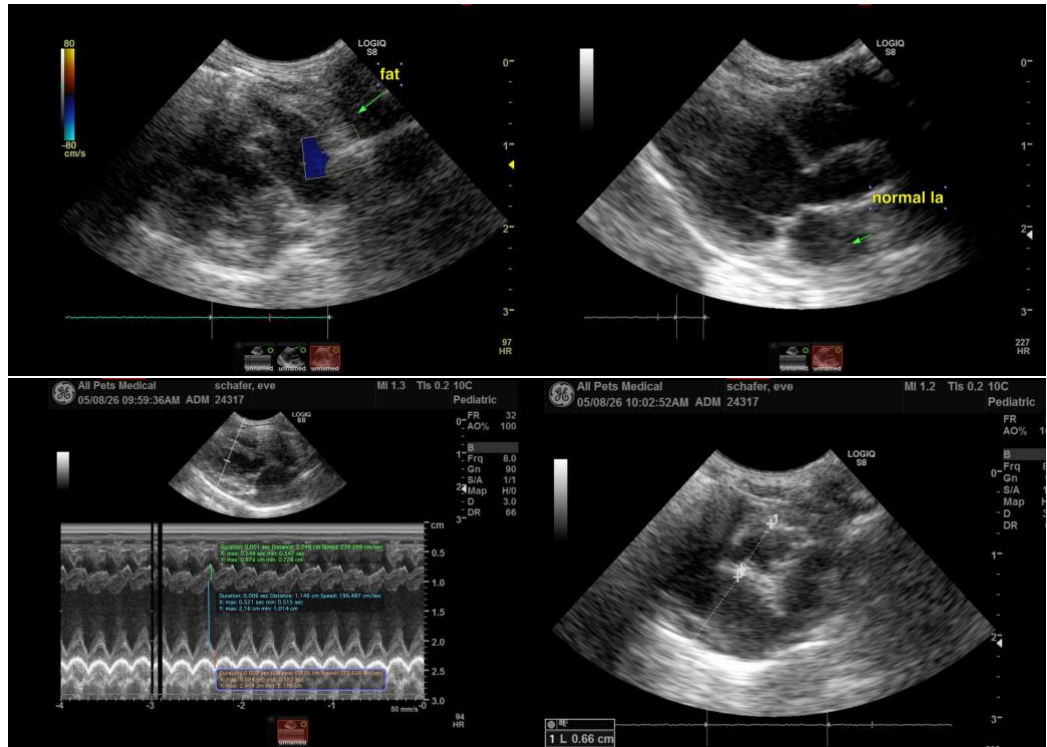
**DATE**

5/8/26

- Large amount of thoracic fat- This may be causing the appearance of cardiomegaly owing to fat overlay.

**INTERPRETATION OF THE FINDINGS & FURTHER RECOMMENDATIONS**

No evidence of primary cardiac pathology.



The information and recommendations provided are based on the images presented by the referring veterinarian/sonographer. No evaluation can be communicated regarding pathology that was not visible in the image/video clips provided.

Thank you for this referral. If the clinical or image interpretation does not parallel your findings or if I can be of any further assistance please contact me.

**Eric Lindquist**, DMV, DABVP(CFM), Cert. IVUSS,  
CEO, Owner, Founder -- SonoPath.com  
[info@SonoPath.com](mailto:info@SonoPath.com)