

PATIENT

Spencer Ramsell

SPECIES

Ferret

BREED

Ferret

SEX

Neutered Male

AGE

6.5 Years

WEIGHT

3.74 lbs

INTERPRETED BY

Eric Lindquist, DMV,
DABVP (CFM), Cert.
IVUSS

IMAGING PERFORMED BY

Heidi Putnam, LVT

HOSPITAL NAME

Nothwest Exotic Pet
Vet

REFERRING VET

Dr. Ramsell

INVOICE

75047

DATE

5/8/26

PRESENTING CLINICAL SIGNS

Previous films showed some abdominal distension, but minimal fluid. Now seems to have some abdominal fluid.

ULTRASONOGRAPHIC EXAMINATION OF THE ABDOMEN

Urinary System

The **urinary bladder** was empty at the time of the sonogram with minor subjective hypertrophy.

The **kidneys** revealed largely normal size and structure, corticomedullary definition and ratio (cortex 1/3 of medulla) were essentially maintained with some age-related loss of curvilinear patterns regarding the capsule and C/M junction. The cortices presented largely uniform texture with some increased echogenicity expected for his age patient. Medullary structure differed distinctly from that of the cortex and no evidence of pelvic dilation was present. A cortical cyst was noted in the dorsal cranial cortex of the left kidney measuring 0.38 cm. Left kidney measures 3.0 cm. Right kidney measured 2.96 cm with pinpoint mineralizations noted.

Adrenal Glands

Both **adrenal glands** were visualized and recognized as having normal shape, size, position and echogenicity for this breed. The phrenic vasculature, glandular echogenicity and detail were unremarkable. Capsule, cortex, and medullary definition were normal for this age patient. Right measured 0.34 cm. Left measured 0.33 cm.

Spleen

The **spleen** was mildly enlarged with scalloping contour.

Liver

The **liver** presented multiple cystic and nodular mixed echogenic masses measuring up to 1.7 cm. A mass in the left liver measured 1.5 cm. The gallbladder and common bile duct were unremarkable. No passive congestion noted to suggest thoracic disease as a primary issue.

Gastrointestinal


Examination of the **gastrointestinal tract** revealed a stomach and intestine free of stasis, of normal wall thickness, acceptable curvilinear mural detail, and peristaltic activity. Small and large intestine demonstrated normal luminal chyme and stool consistency respectively. No obstructive or overt infiltrative disease was noted. No associated abnormal lymphatic activity was noted.

Pancreas

The base and limbs of the **pancreas** were observed to be largely isoechoic to surrounding omental fat. Pancreatic duct and capsular contour were acceptably normal and parenchyma respected normal curvilinear patterns. No overt evidence of active inflammatory or neoplastic disease was noted. Right pancreatic limb measured 0.69 cm.

Free Abdomen

Moderate echogenic free fluid noted.



PATIENT

Spencer Ramsell

SPECIES

Ferret

BREED

Ferret

SEX

Neutered Male

AGE

6.5 Years

WEIGHT

3.74 lbs

INTERPRETED BY

Eric Lindquist, DMV,
DABVP (CFM), Cert.
IVUSS

IMAGING PERFORMED BY

Heidi Putnam, LVT

HOSPITAL NAME

Nothwest Exotic Pet
Vet

REFERRING VET

Dr. Ramsell

INVOICE

75047

DATE

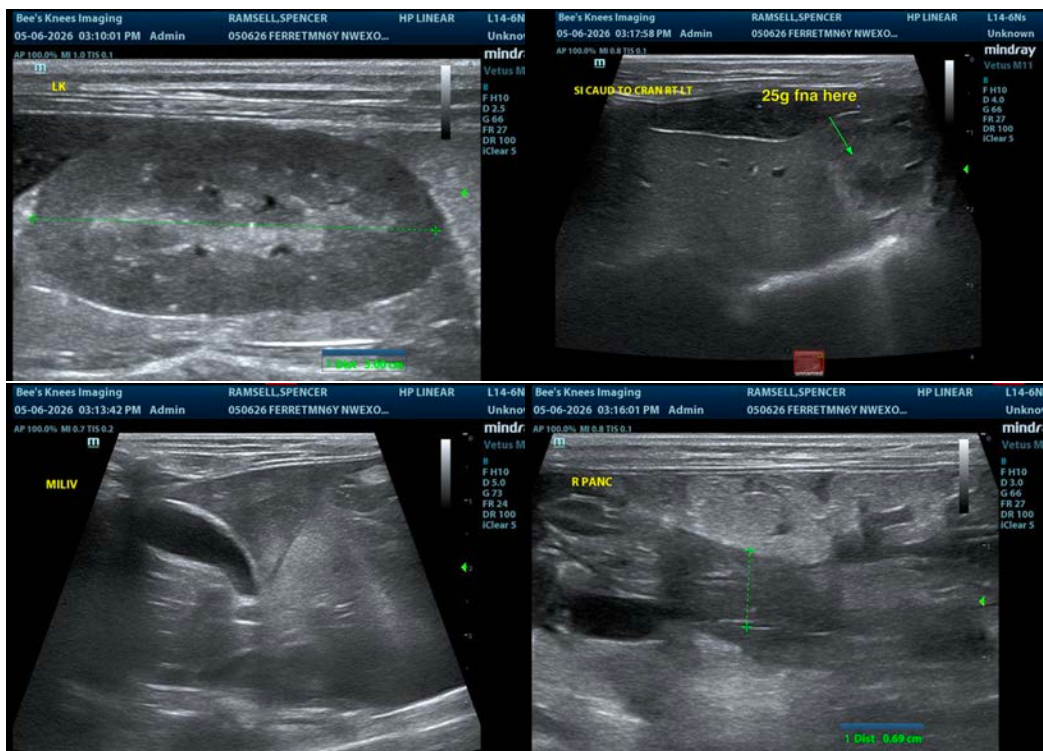
5/8/26

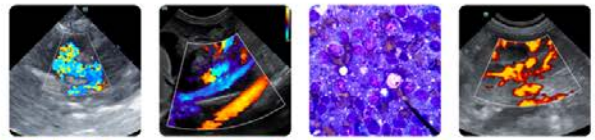
ULTRASONOGRAPHIC FINDINGS

- Abdominal fluid of unknown cause - Strong concern for lymphomatosis, mastocytosis, carcinoma or similar. FIP-like syndrome is also a minor potential.
- Liver masses - biliary cystadenoma or carcinoma possible.
- Mildly enlarged, scalloping spleen.
- Age related renal changes with slight mineralizations.
- Empty urinary bladder with minor subjective hypertrophy.

INTERPRETATION OF THE FINDINGS & FURTHER RECOMMENDATIONS

Given the echogenic abdominal fluid, recommend cytospin of the fluid after abdominocentesis. 25-gauge FNA of the parenchymal portions of the liver masses recommended. Prognosis is very guarded.





PATIENT

Spencer Ramsell

SPECIES

Ferret

BREED

Ferret

SEX

Neutered Male

AGE

6.5 Years

WEIGHT

3.74 lbs

INTERPRETED BY

Eric Lindquist, DMV,
DABVP (CFM), Cert.
IVUSS

**IMAGING
PERFORMED BY**

Heidi Putnam, LVT

HOSPITAL NAME

Nothwest Exotic Pet
Vet

REFERRING VET

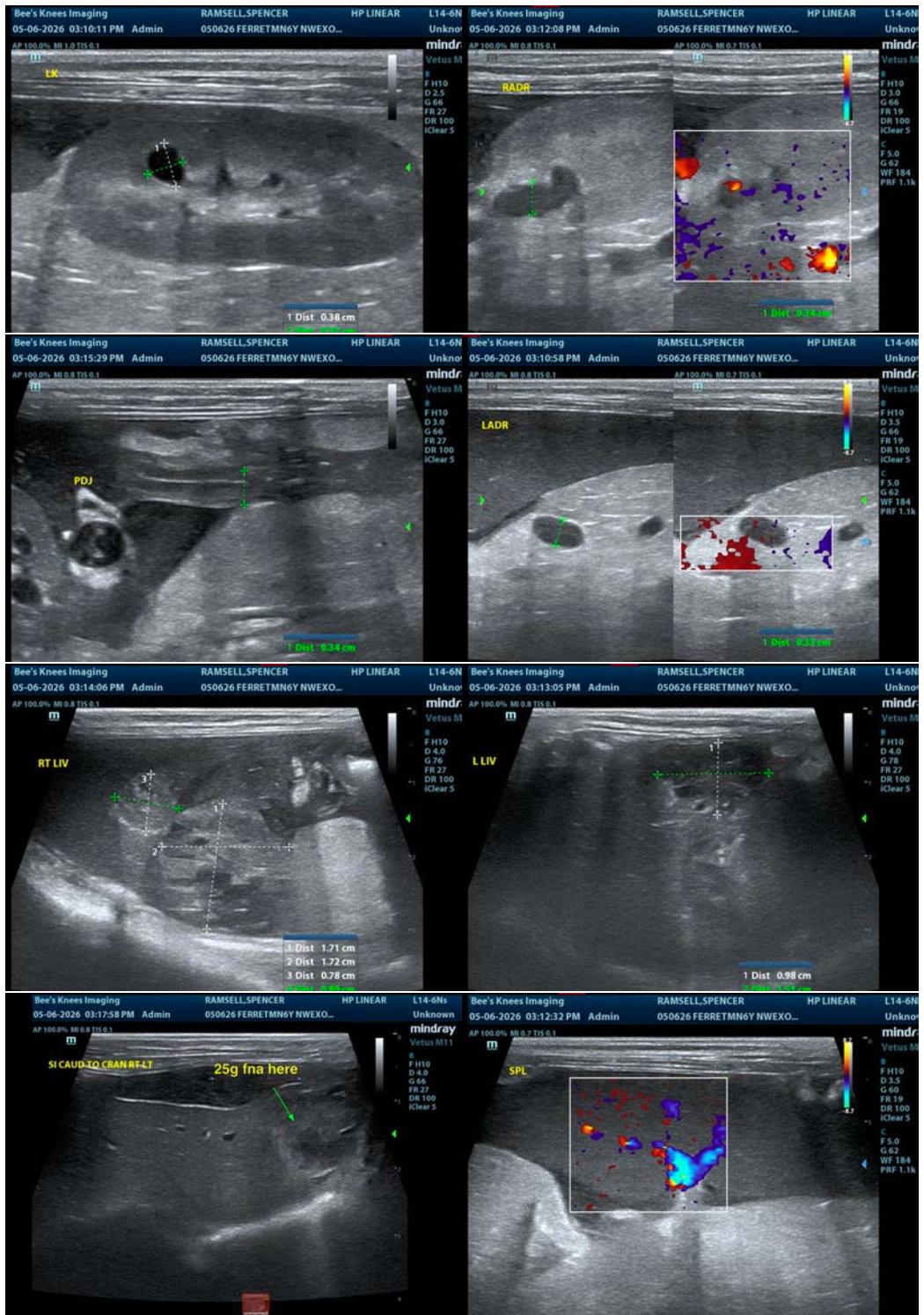
Dr. Ramsell

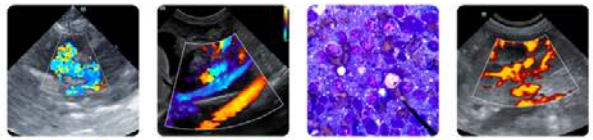
INVOICE

75047

DATE

5/8/26





PATIENT

Spencer Ramsell

The information and recommendations provided are based on the images presented by the referring veterinarian/sonographer. No evaluation can be communicated regarding pathology that was not visible in the image/video clips provided.

SPECIES

Ferret

Thank you for this referral. If the clinical or image interpretation does not parallel your findings or if I can be of any further assistance please contact me.

BREED

Ferret

Eric Lindquist, DMV, DABVP(CFM), Cert. IVUSS,
CEO, Owner, Founder -- SonoPath.com

info@SonoPath.com

SEX

Neutered Male

AGE

6.5 Years

WEIGHT

3.74 lbs

INTERPRETED BY

Eric Lindquist, DMV,
DABVP (CFM), Cert.
IVUSS

IMAGING PERFORMED BY

Heidi Putnam, LVT

HOSPITAL NAME

Nothwest Exotic Pet
Vet

REFERRING VET

Dr. Ramsell

INVOICE

75047

DATE

5/8/26