



**PATIENT**

Murphy McNulty

**SPECIES**

Canine

**BREED**

Cockapoo

**SEX**

Neutered Male

**AGE**

10 Years

**WEIGHT**

26 lbs

**INTERPRETED BY**

Eric Lindquist, DMV,  
DABVP(CFM), Cert.  
IVUSS

**IMAGING PERFORMED BY**

Chloe Lowe CVT

**HOSPITAL NAME**

The Animal Hospital of  
Sussex County

**REFERRING VET**

Dr. Lovell

**INVOICE**

15970

**DATE**

05/08/26

**PRESENTING CLINICAL SIGNS**

Grade 3 murmur left. Mild exercise intolerance. Vetmedin.

**ULTRASONOGRAPHIC EXAMINATION OF THE HEART**

CANINE CARDIAC PARAMETERS	MR VMAX (m/s)	TR VMAX (m/s)	LA/AO (M-Mode)	LA/AO (Heart Base; Swe)	FS (%)	EF (%)	EPSS (cm)
NORMAL PARAMETER	4.5-5.5	<2.7	1.3	Up to 1.6	28-40	40-100	<0.6
PATIENT	5.87	2.2	1.27	1.3	48	82	0.27
CANINE CARDIAC PARAMETERS	HR (BPM)	AV VMAX (m/s)	PV MAX (m/s)	BODY WEIGHT (lbs)	LAD LA MAX 4 Chamber	LVIDd Avg; 2D and m-mode short axis (cm)	LVIDs Avg; 2D and m-mode short axis (cm)
NORMAL PARAMETER	50-100	0.7-1.7	0.7-1.6				
PATIENT	146	1.7	0.89	26	3.0	2.35	--

E-wave Velocity: 0.8

**Cardiac Presentation**

The echocardiogram in this patient demonstrated normal **left atrial** size based on 3 different LA measurement methods. Chamber volumes and echogenicity were normal. The cranial and caudal **mitral** valve leaflets presented vegetative thickening consistent with endocardiosis. Doppler indicated measurable insufficiency. The **left ventricle** presented normal thicknesses with linear contour and was not dilated nor restricted. The **myocardium** presented normal echogenicity without subjective evidence of significant fibrotic or ischemic disease. **Contractility** of the ventricular walls was adequate and in normal range for this patient evidenced by the fractional shortening measurement and subjective evaluation of the different regions of the myocardium. The **left ventricular outflow** tract demonstrated normal laminar flow and subjective structural integrity. The **right atrium** and auricle revealed normal size, structure and content. No evidence of masses was noted or chamber overload. **Tricuspid** valvular assessment demonstrated adequate linear morphology. The **right ventricle** was of normal size (1/3 diameter of LV), chordae structure, myocardial echogenicity and thickness. **Pulmonic** tract assessment revealed normal valve structure, laminar flow, and diameter (approx.1:1 pa/ao ratio). No visible **pericardial** or free pleura fluid was noted. No echographically detectable evidence of infiltrative disease was visible. The cranial **mediastinum and pericardial regions** were free of masses in the visible window.

**ULTRASONOGRAPHIC FINDINGS**

- Compensated stage B2 valvular disease.

**INTERPRETATION OF THE FINDINGS & FURTHER RECOMMENDATIONS**



**PATIENT**

Murphy McNulty

No significant volume overload in the left heart. The patient is stable on the current medications. Recheck echo in 6 to 12 months depending upon clinical status. If the murmur grade increases or clinical signs initiate, then recheck echocardiogram is indicated.

**SPECIES**

Canine

**BREED**

Cockapoo

**SEX**

Neutered Male

**AGE**

10 Years

**WEIGHT**

26 lbs

**INTERPRETED BY**

Eric Lindquist, DMV,  
 DABVP(CFM), Cert.  
 IVUSS

**IMAGING PERFORMED BY**

Chloe Lowe CVT

**HOSPITAL NAME**

The Animal Hospital of  
 Sussex County

**REFERRING VET**

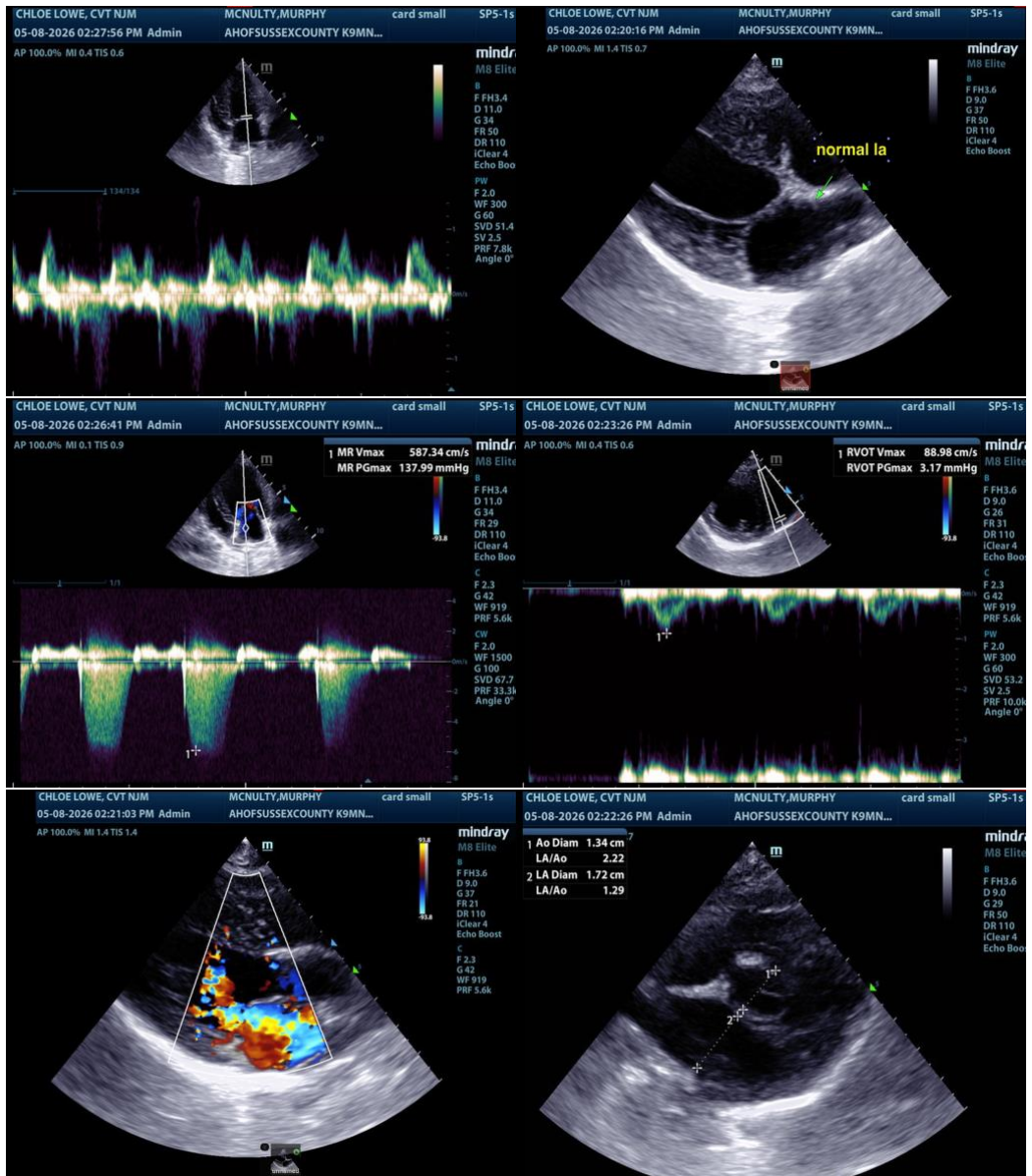
Dr. Lovell

**INVOICE**

15970

**DATE**

05/08/26





**PATIENT**

Murphy McNulty

**SPECIES**

Canine

**BREED**

Cockapoo

**SEX**

Neutered Male

**AGE**

10 Years

**WEIGHT**

26 lbs

**INTERPRETED BY**

Eric Lindquist, DMV,  
 DABVP(CFM), Cert.  
 IVUSS

**IMAGING PERFORMED BY**

Chloe Lowe CVT

**HOSPITAL NAME**

The Animal Hospital of  
 Sussex County

**REFERRING VET**

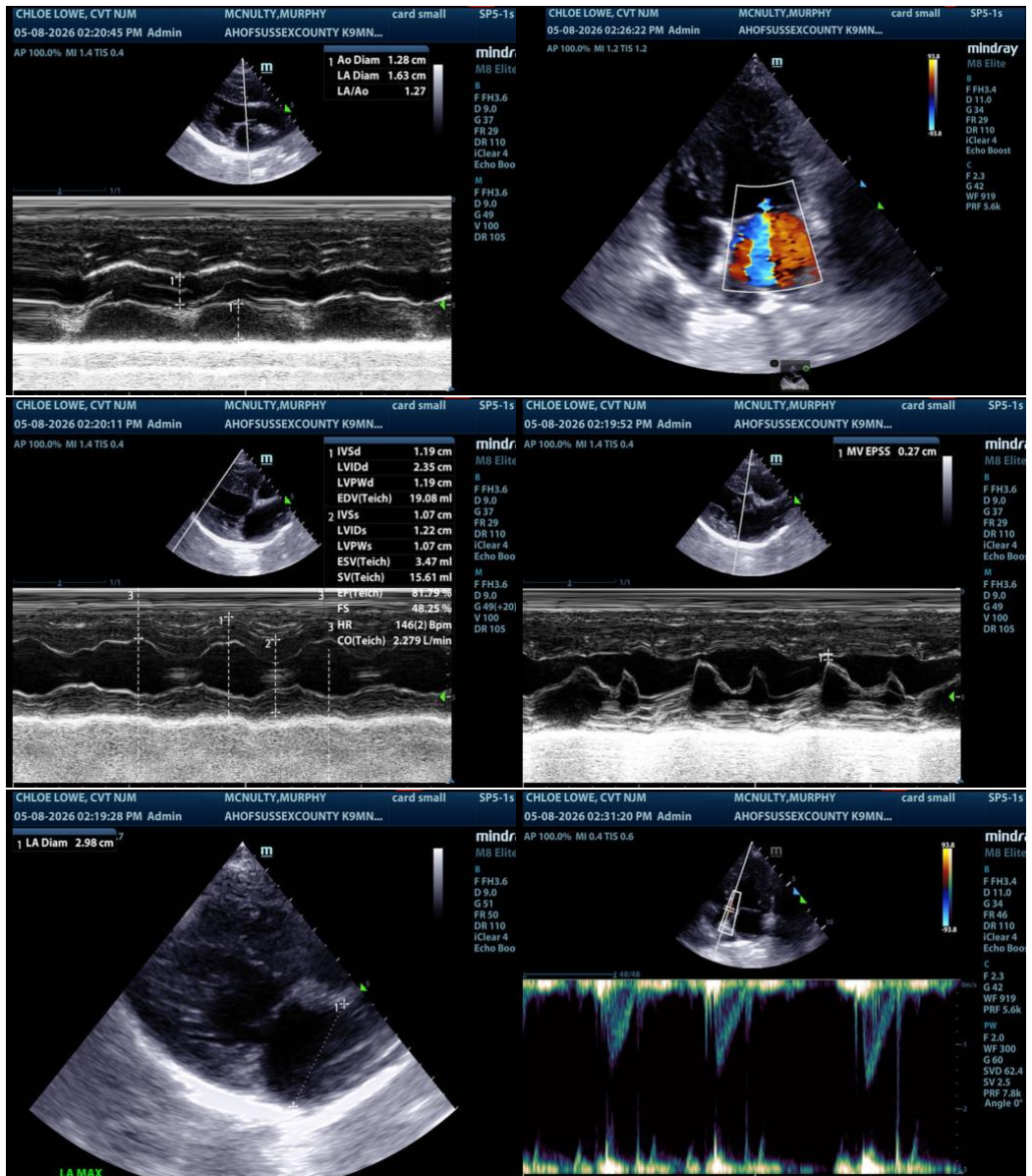
Dr. Lovell

**INVOICE**

15970

**DATE**

05/08/26



The information and recommendations provided are based on the images presented by the referring veterinarian/sonographer. No evaluation can be communicated regarding pathology that was not visible in the image/video clips provided.

Thank you for this referral. If the clinical or image interpretation does not parallel your findings or if I can be of any further assistance, please contact me.

Eric Lindquist, DMV, DABVP(CFM), Cert. IVUSS,

CEO, Owner, Founder -- SonoPath.com

[info@SonoPath.com](mailto:info@SonoPath.com)



**PATIENT**

Murphy McNulty

**SPECIES**

Canine

**BREED**

Cockapoo

**SEX**

Neutered Male

**AGE**

10 Years

**WEIGHT**

26 lbs

**INTERPRETED BY**

Eric Lindquist, DMV,  
DABVP(CFM), Cert.  
IVUSS

**IMAGING  
PERFORMED BY**

Chloe Lowe CVT

**HOSPITAL NAME**

The Animal Hospital of  
Sussex County

**REFERRING VET**

Dr. Lovell

**INVOICE**

15970

**DATE**

05/08/26