



PATIENT

Lucy Barger

SPECIES

Canine

BREED

Beagle

SEX

Spayed Female

AGE

9 Years

WEIGHT

27.4 Pounds

INTERPRETED BY

Eric Lindquist, DMV
DABVP, Cert. IVUSS

IMAGING PERFORMED BY

Brian Klug

HOSPITAL NAME

Sondel Family VC

REFERRING VET

Kara Wallisch

PRESENTING CLINICAL SIGNS

History: Recheck of spleen from last recheck on 12/5/23. Monitoring for growth of splenic nodules to determine if splenectomy is necessary at this time.

Abnormal PE/Chem/CBC/UA Results: No further diagnostics done since last AUS

LIMITED ULTRASONOGRAPHIC EXAMINATION

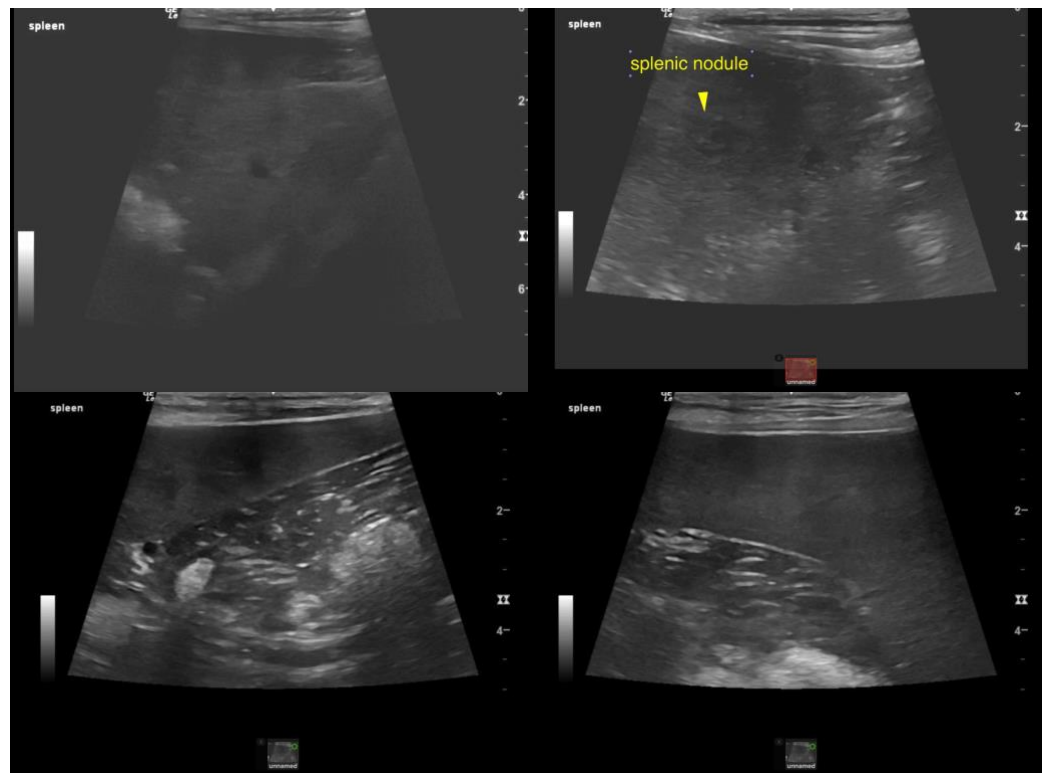
Mild heterogenous nonprogressive changes were noted in the spleen. The largest nodule measured approximately 7.0 mm. The spleen was folded upon itself. No overt evidence of neoplasia.

ULTRASONOGRAPHIC FINDINGS

- Nodular hyperplasia splenic pattern
- No evidence of significant progression from the prior sonogram

INTERPRETATION OF THE FINDINGS & FURTHER RECOMMENDATIONS

FNA could be considered if any weight loss is present, however, the pattern is most consistent with benign hyperplasia.



INVOICE

22391

DATE

5/8/23

The information and recommendations provided are based on the images presented by the referring veterinarian. No evaluation can be communicated regarding pathology that was not visible in the image/video clips provided.

Thank you for this referral. If the clinical or image interpretation does not parallel your findings or if I can be of any further assistance please contact me.



PATIENT

Lucy Barger

Eric Lindquist, DMV, DABVP, Cert. IVUSS, CEO of SonoPath.com
info@SonoPath.com

SPECIES

Canine

BREED

Beagle

SEX

Spayed Female

AGE

9 Years

WEIGHT

27.4 Pounds

INTERPRETED BY

Eric Lindquist, DMV
DABVP, Cert. IVUSS

**IMAGING
PERFORMED BY**

Brian Klug

HOSPITAL NAME

Sondel Family VC

REFERRING VET

Kara Wallisch

INVOICE

22391

DATE

5/8/23