



PATIENT

Holly Mirowsky

SPECIES

Canine

BREED

Catahoula Leopard
Dog

SEX

Spayed Female

AGE

4 Years

WEIGHT

48 Pounds

INTERPRETED BY

Eric Lindquist, DMV
DABVP, Cert. IVUSS

**IMAGING
PERFORMED BY**

Jessica Miller

HOSPITAL NAME

Rockaway AH

REFERRING VET

Dr. Maniar

INVOICE

22368

DATE

5/8/23

PRESENTING CLINICAL SIGNS

History: Post prandial V+, defecated out paper towel

Abnormal PE/Chem/CBC/UA Results: NSF

ULTRASONOGRAPHIC EXAMINATION OF THE ABDOMEN

Urinary System

The **urinary bladder**, trigone, and pelvic urethra presented normal thicknesses and normal tone. The ureters were not visible which is normal. No uroliths or sediment were visualized and anechoic urine was present. No evidence of inflammatory or neoplastic changes were noted. Ureteral papillae were normal. The pelvic urethra was imaged 2.0 cm beyond the cystourethral junction.

The **kidneys** revealed normal size and structure, corticomedullary definition and ratio for this age. The cortices presented largely uniform texture with normal echogenic relationship to liver and spleen. Medullary structure differed distinctly from the cortex and no evidence of pelvic dilation was present. The capsules were acceptably uniform without significant irregularities. The right kidney measured 5.48 cm. The left kidney measured 5.91 cm.

Adrenal Glands

Both **adrenal glands** were visualized and recognized as having normal shape, size, position and echogenicity for this breed. The phrenic vasculature, glandular echogenicity and detail were unremarkable. Capsule, cortex, and medullary definition were normal for this age patient. The left adrenal gland measured 2.57 cm x 0.62 cm at the caudal pole and 0.63 cm at the cranial pole. The right adrenal gland measured 2.15 cm x 1.2 cm at the cranial pole and 0.7 cm at the caudal pole.

Spleen

The **spleen** presented a smooth homogeneous parenchyma hyperechoic to liver and renal cortical parenchyma. The capsule was smooth without noticeable expansion or deviation from within the spleen or adjacent pathology. The splenic vasculature demonstrated normal volume without signs of congestion or thrombosis. No sonographic evidence of acute or chronic inflammatory, neoplastic, or infarctual changes were noted.

Liver

The **liver** images submitted revealed subjectively normal liver size, contour, and structure. Parenchymal echogenicity was naturally coarse and hypoechoic to the spleen. Vascular and biliary tracts were of normal volume with no evidence of congestion. The gallbladder presented acceptably thin walls with primarily anechoic content. The cystic and common bile ducts were normal. No pathological hepatic lymphadenopathy was evident. No overt structural evidence of inflammatory, infiltrative or regenerative pathology was evident.

Gastrointestinal

Mild **pyloric** hypertrophy was noted in this patient. No evidence of stasis. The small intestine and colon were unremarkable.

Pancreas

The base and limbs of the **pancreas** were observed to be largely isoechoic to surrounding omental fat. Pancreatic duct and capsular contour were acceptably normal and parenchyma respected normal curvilinear patterns. No overt evidence of active inflammatory or neoplastic disease was noted.



PATIENT **ULTRASONOGRAPHIC FINDINGS**

Holly Mirowsky • Pyloric hypertrophy

SPECIES **INTERPRETATION OF THE FINDINGS & FURTHER RECOMMENDATIONS**

Canine Given the clinical history, I recommend BID canned feedings over the next 3-4 weeks and the following protocol. Otherwise endoscopy is necessary to obtain mucosal biopsies for further definition.

BREED **Helicobacter/Gastritis protocol**

Catahoula Leopard Dog A clinical trial of **Zithromax (Dogs: 5-10 mg/kg p.o. q24h. May increase dosing interval to q48h after 3-5 days of treatment), Metronidazole (10-20 mg/kg p.o. b.i.d.), Pepcid (0.5-1 mg/kg s.i.d.) and Sucralfate (0.5-2 g/dog PO) or Omeprazole (1 mg/kg p.o. s.i.d.)** over the next 3 weeks along with a **novel-protein or hydrolyzed diet** with slurry feeding b.i.d./t.i.d. over the next 2-4 days and then increase to canned diet bid. Dry food should be avoided over the next 4 weeks. A recheck sonogram to assess GI improvement or progression would be ideal in 4 weeks.

AGE

4 Years

WEIGHT

48 Pounds

INTERPRETED BY

Eric Lindquist, DMV
DABVP, Cert. IVUSS

IMAGING PERFORMED BY

Jessica Miller

HOSPITAL NAME

Rockaway AH

REFERRING VET

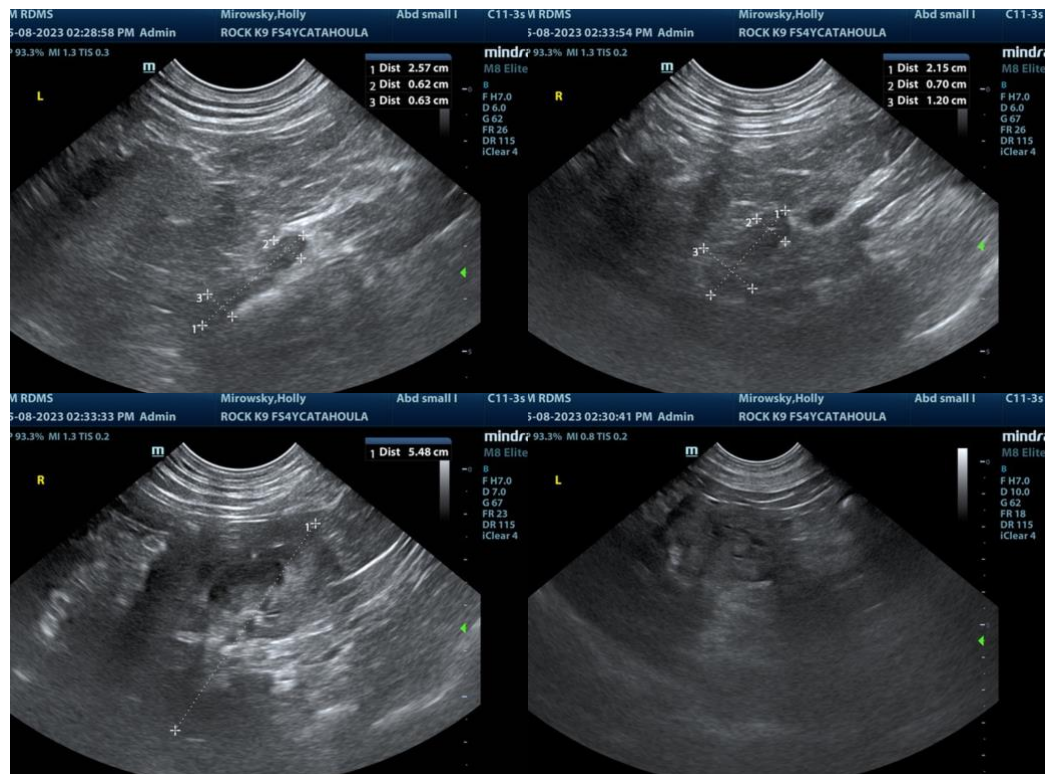
Dr. Maniar

INVOICE

22368

DATE

5/8/23



The information and recommendations provided are based on the images presented by the referring veterinarian. No evaluation can be communicated regarding pathology that was not visible in the image/video clips provided.

Thank you for this referral. If the clinical or image interpretation does not parallel your findings or if I can be of any further assistance please contact me.

Eric Lindquist, DMV, DABVP, Cert. IVUSS, CEO of SonoPath.com
info@SonoPath.com