



PATIENT

Buddy Charles

SPECIES

Canine

BREED

Bichon

SEX

Neutered Male

AGE

13 Years

WEIGHT

13 Pounds

INTERPRETED BY

Eric Lindquist, DMV
DABVP, Cert. IVUSS

IMAGING PERFORMED BY

Kelly Vazquez

HOSPITAL NAME

Marsh AH

REFERRING VET

Dr. Milwicki

INVOICE

22381

DATE

5/8/23

PRESENTING CLINICAL SIGNS

History: Patient presents for follow up ultrasound, new anemia, history of kidney disease and seizures, liver pathology on previous ultrasound. Current meds: Azodyl, Keppra, Bromide, Clopidogrel, ALOH, Cyproheptadine.

CBC/Chem findings: RBC 4.71, HCT 29%, HGB 8.8, MCH 18.7, MCHC 30.3, Reticulocyte HGB 20.7, Platelets 1077. Chem: SDMA 19, BUN 36, Calcium 12.1, Potassium 7.2, Na:K Ratio 20, ALT 220, ALP 4237, amylase 1647. U/A: Urine Protein Creatinine Ratio 2.3, USG 1.016.

ULTRASONOGRAPHIC EXAMINATION OF THE HEART & ABDOMEN

CANINE CARDIAC PARAMETERS	MR VMAX (m/s)	TR VMAX (m/s)	LA/AO (Boon method)	LA/AO (Heart Base; Swe)	FS (%)	EF (%)	EPSS (cm)
NORMAL PARAMETER	4.5-5.5	<2.7	1.3	<1.3	28-40	40-100	<0.6
PATIENT	6.0	2.4	NM	1.4	27	56	0.1
CANINE CARDIAC PARAMETERS	HR (BPM)	AV VMAX (m/s)	PV MAX (m/s)	BODY WEIGHT (kg)	LA 2D short axis Base view (cm)	LVIDd Avg; 2D and m-mode short axis (cm)	LVIDs Avg; 2D and m-mode short axis (cm)
NORMAL PARAMETER	50-100	0.7-1.7	0.7-1.6				
PATIENT	109	1.20	1.20	--	2.0	2.45	--

Cardiac Presentation

The echocardiogram in this patient demonstrated normal **left atrial** size based on 3 separate methods of LA evaluation. Mitral insufficiency was noted. The **left ventricle** presented thicknesses with linear contour and was not dilated nor restricted. The **myocardium** presented normal echogenicity without subjective evidence of significant fibrotic or ischemic disease. **Contractility** of the ventricular walls was adequate and in normal range for this patient evidenced by the fractional shortening measurement and subjective evaluation of the different regions of the myocardium. The **left ventricular outflow** tract demonstrated normal laminar flow and subjective structural integrity. The **right atrium** and auricle revealed normal size, structure and content. No evidence of masses was noted. **Tricuspid** insufficiency was noted. The **right ventricle** was of normal size (1/3 diameter of LV), chordae structure, myocardial echogenicity and thickness. **Pulmonary outflow** tract assessment revealed normal valve structure, laminar flow, and diameter (approx.1:1 pa/ao ratio). No visible **pericardial** or free pleura fluid was noted. The cranial **mediastinum and pericardial and extra-cardiac regions** were free of masses in the visible window.

Urinary System



PATIENT

Buddy Charles

The **urinary bladder**, trigone, and pelvic urethra presented normal thicknesses and normal tone. The ureters were not visible which is normal. No uroliths or sediment were visualized and anechoic urine was present. No evidence of inflammatory or neoplastic changes were noted. Ureteral papillae were normal. The pelvic urethra was imaged 3.0 cm beyond the cystourethral junction.

SPECIES

Canine

The **kidneys** revealed largely normal size and structure, corticomedullary definition and ratio (cortex 1/3 of medulla) were essentially maintained with some moderate age-related loss of curvilinear patterns regarding the capsule and C/M junction. The cortices presented largely uniform texture with some increased echogenicity expected for his age patient. Medullary structure differed distinctly from that of the cortex and no evidence of pelvic dilation was present. The right kidney measured 3.17 cm. The left kidney measured 3.52 cm. Occasional renal cysts were noted.

BREED

Bichon

Adrenal Glands

SEX

Neutered Male

Both **adrenal glands** were visualized and recognized as having normal shape, size, position and echogenicity for this breed. The phrenic vasculature, glandular echogenicity and detail were unremarkable. Capsule, cortex, and medullary definition were normal for this age patient. The right adrenal gland measured 1.13 cm x 0.57 cm at the caudal pole and 0.62 cm at the cranial pole. The left adrenal gland measured 1.58 cm x 0.45 cm at the caudal pole and 0.53 cm at the cranial pole.

AGE

13 Years

Spleen

WEIGHT

13 Pounds

The **spleen** presented a smooth homogeneous parenchyma hyperechoic to liver and renal cortical parenchyma. The capsule was smooth without noticeable expansion or deviation from within the spleen or adjacent pathology. The splenic vasculature demonstrated normal volume without signs of congestion or thrombosis. No sonographic evidence of acute or chronic inflammatory, neoplastic, or infarctual changes were noted.

INTERPRETED BY

Eric Lindquist, DMV
DABVP, Cert. IVUSS

Liver

The **liver** revealed multifocal mixed hyperechoic nodular changes and increased portal markings. An expansive adenomatous mass was noted in the left liver, measuring 3.9 cm. The gallbladder and common bile duct were unremarkable.

IMAGING PERFORMED BY

Kelly Vazquez

Gastrointestinal

Examination of the **gastrointestinal tract** revealed a stomach and intestine free of stasis, of normal wall thickness, acceptable curvilinear mural detail, and peristaltic activity. Small and large intestine demonstrated normal luminal chyme and stool consistency respectively. No obstructive or overt infiltrative disease was noted. No associated abnormal lymphatic activity was noted.

HOSPITAL NAME

Marsh AH

Pancreas

REFERRING VET

Dr. Milwicki

The base and limbs of the **pancreas** were observed to be largely isoechoic to surrounding omental fat. Pancreatic duct and capsular contour were acceptably normal and parenchyma respected normal curvilinear patterns. No overt evidence of active inflammatory or neoplastic disease was noted.

INVOICE

22381

- Stage B-1 valvular disease
- Diffuse nodular hepatic changes with irregular swelling, nodules and low-grade mass formation (likely adenoma or nodular hyperplasia).

DATE

5/8/23

ULTRASONOGRAPHIC FINDINGS


PATIENT

Buddy Charles

- Moderate chronic degenerative renal changes with occasional cysts in the kidneys- subjectively near end stage renal disease is present.

INTERPRETATION OF THE FINDINGS & FURTHER RECOMMENDATIONS
SPECIES

Canine

Screening FNA of the general liver and nodules is warranted for further definition. Bile acid profile would be appropriate. If bile acids are elevated, liver support diet that is compatible with emerging renal failure would be indicated. If neoplasia is present in the liver, it appears to be likely low grade. This is more consistent with chronic inflammatory hepatopathy and pronounced nodular hyperplasia/hepatoma formation. The cause of anemia is unclear, unless owing to emerging renal failure CBC path review is warranted. Blood pressure measurements are warranted, if not already performed. Ace-inhibitor is indicated if systolic pressure is >160. Skull CT with contrast would be ideal as well.

BREED

Bichon

SEX

Neutered Male

ABOUT SONOPATH CT SERVICES:

SonoPath CT Services are offered at the SonoPath Imaging and Veterinary Education Center, 141 Main St (rt 206), Andover, New Jersey, a 20-minute drive west on route 80/206 North from the route 80/287 interchange/Parsippany, New Jersey. More information can be found at <https://sonopath.com/resources/sonopaths-teleconsultation-services-and-sdep-certification/sonopath-ct-services>

AGE

13 Years

WEIGHT

13 Pounds

INTERPRETED BY

 Eric Lindquist, DMV
DABVP, Cert. IVUSS

IMAGING PERFORMED BY

Kelly Vazquez

HOSPITAL NAME

Marsh AH

REFERRING VET

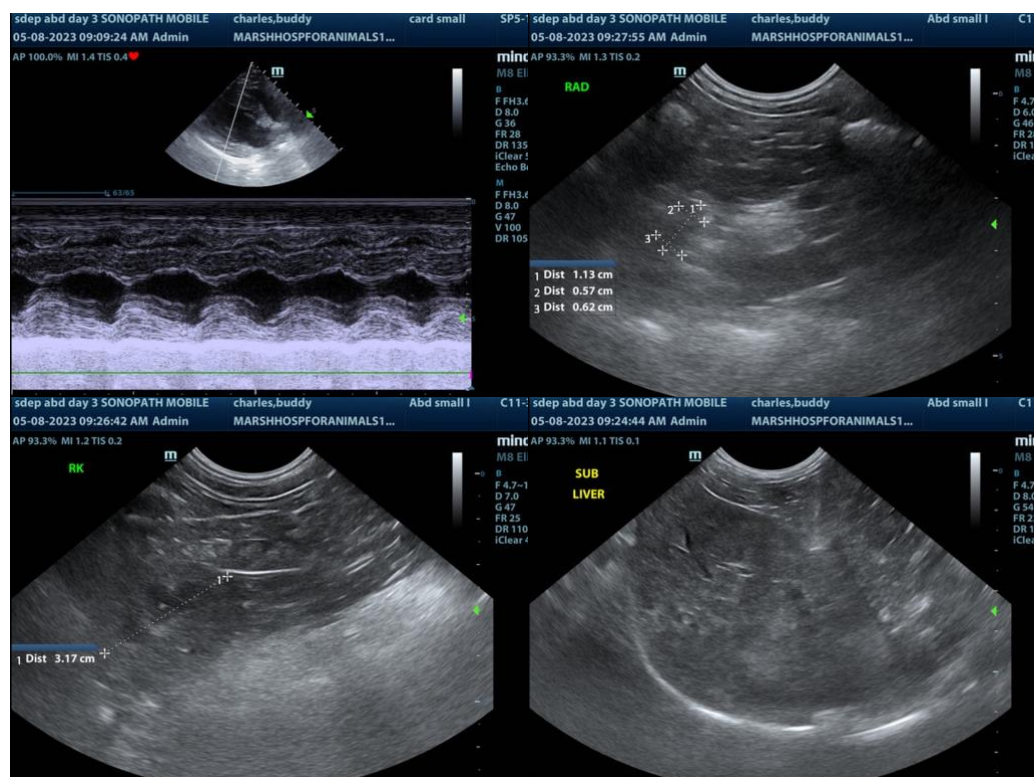
Dr. Milwicki

INVOICE

22381

DATE

5/8/23





PATIENT

Buddy Charles

SPECIES

Canine

BREED

Bichon

SEX

Neutered Male

AGE

13 Years

WEIGHT

13 Pounds

INTERPRETED BY

Eric Lindquist, DMV
DABVP, Cert. IVUSS

IMAGING PERFORMED BY

Kelly Vazquez

HOSPITAL NAME

Marsh AH

REFERRING VET

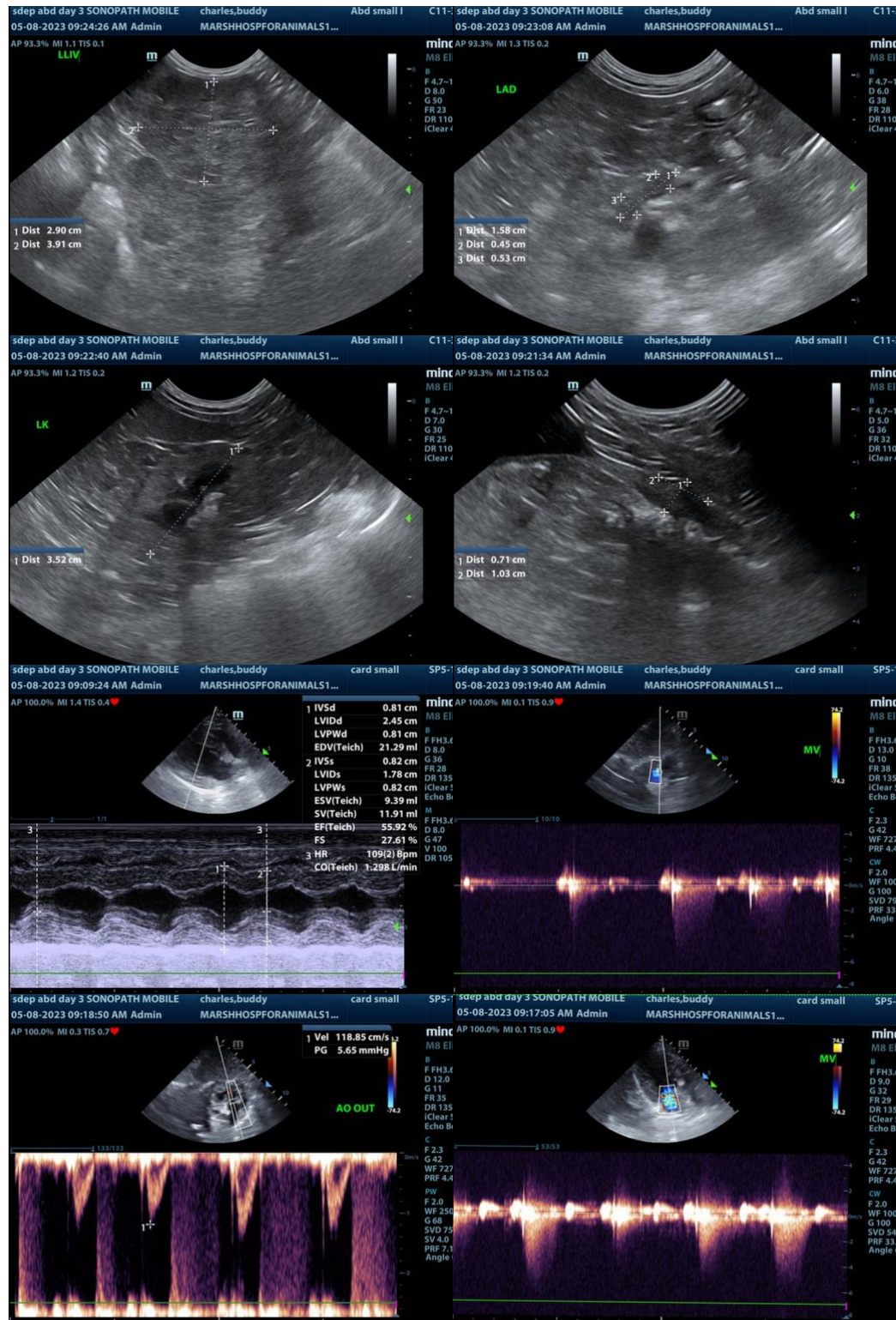
Dr. Milwicki

INVOICE

22381

DATE

5/8/23





PATIENT

Buddy Charles

SPECIES

Canine

BREED

Bichon

SEX

Neutered Male

AGE

13 Years

WEIGHT

13 Pounds

INTERPRETED BY

Eric Lindquist, DMV
DABVP, Cert. IVUSS

IMAGING PERFORMED BY

Kelly Vazquez

HOSPITAL NAME

Marsh AH

REFERRING VET

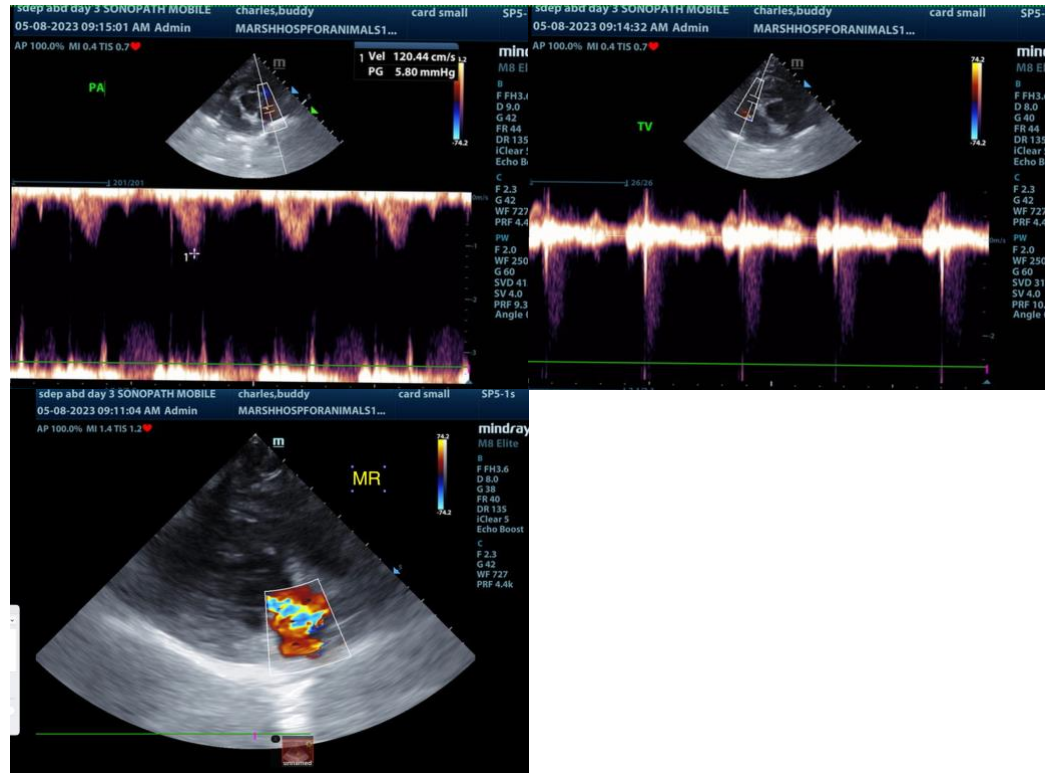
Dr. Milwicki

INVOICE

22381

DATE

5/8/23



The information and recommendations provided are based on the images presented by the referring veterinarian. No evaluation can be communicated regarding pathology that was not visible in the image/video clips provided.

Thank you for this referral. If the clinical or image interpretation does not parallel your findings or if I can be of any further assistance please contact me.

Eric Lindquist, DMV, DABVP, Cert. IVUSS, CEO of SonoPath.com
info@SonoPath.com