



PATIENT

Ziggy Dog Marran

SPECIES

Canine

BREED

Mix

SEX

Neutered Male

AGE

12 Years 11 Months

WEIGHT

32.6 Pounds

INTERPRETED BY

Eric Lindquist, DMV

DABVP, Cert. IVUSS

IMAGING PERFORMED BY

Dr. Kitz

HOSPITAL NAME

Woodlands AH

REFERRING VET

Dr. Kitz

INVOICE

37521

DATE

5/8/22

PRESENTING CLINICAL SIGNS

Patient developed a large left inguinal mass per owner within the past few months. On presentation, the mass is soft to firm and non-painful on palpation, in left flank region. Cytology is consistent with a probable lipoma, but some concern over whether there could be a hernia because the mass developed so acutely. On ultrasound, it looks like fat echogenicity, and appears to be encapsulated with no connection to the body wall. However, was concerned about some areas within the mass that did not look homogenous, and had some distal acoustic shadowing almost reminiscent of bowel. Just wanted a second look before we schedule for surgical removal, to try to plan for the procedure and minimize surprises while the pet is under anesthesia.

LIMITED ULTRASONOGRAPHIC EXAMINATION

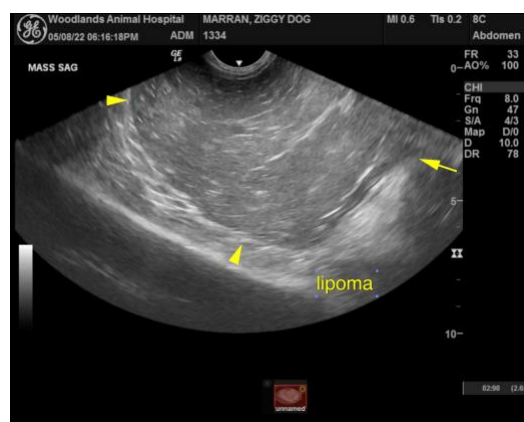
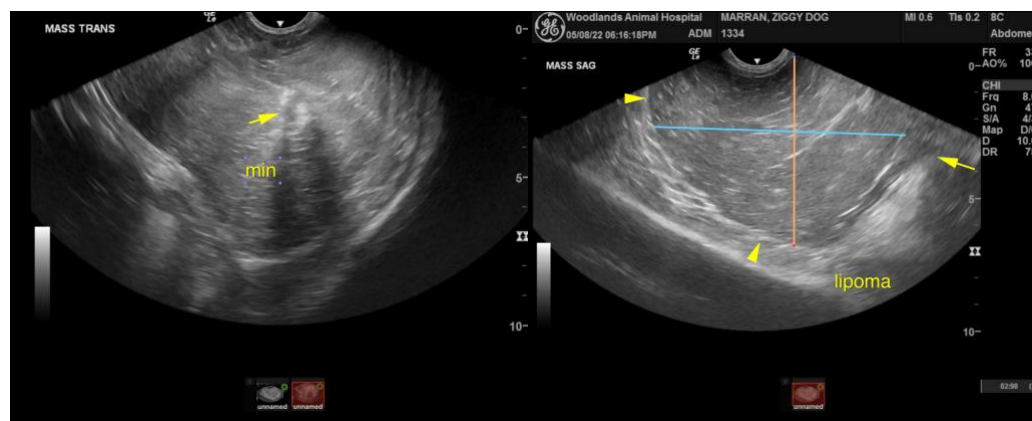
A large inguinal lipoma was noted in this patient measuring 9.5 cm wide x 7.0 cm deep. The mass was uniform with a focal area of ossification or mineralization in the center of the mass. The mass appears resectable, yet likely benign. No evidence of herniation.

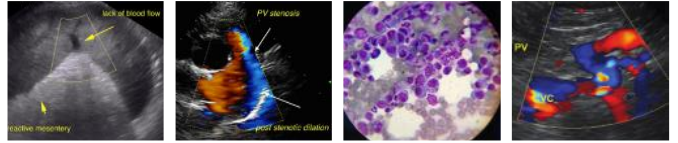
ULTRASONOGRAPHIC FINDINGS

- Inguinal lipoma, encapsulated with focal area of fibrosis at the center – separate from the body wall by approximately 5.0 mm.

INTERPRETATION OF THE FINDINGS & FURTHER RECOMMENDATIONS

Appears resectable. No evidence of herniation.





PATIENT

Ziggy Dog Marran

The information and recommendations provided are based on the images presented by the referring veterinarian/sonographer. No evaluation can be communicated regarding pathology that was not visible in the image/video clips provided.

SPECIES

Canine

Thank you for this referral. If the clinical or image interpretation does not parallel your findings or if I can be of any further assistance please contact me.

Eric Lindquist, DMV, DABVP, Cert. IVUSS, CEO of SonoPath.com

info@SonoPath.com

BREED

Mix

SEX

Neutered Male

AGE

12 Years 11 Months

WEIGHT

32.6 Pounds

INTERPRETED BY

Eric Lindquist, DMV

DABVP, Cert. IVUSS

IMAGING PERFORMED BY

Dr. Kitz

HOSPITAL NAME

Woodlands AH

REFERRING VET

Dr. Kitz

INVOICE

37521

DATE

5/8/22