



PATIENT

Truman Impellitteri

SPECIES

Canine

BREED

Rhodesian Ridgeback

SEX

Neutered Male

AGE

8

WEIGHT

116.9

INTERPRETED BY

Eric Lindquist, DMV,
DABVP(CFM), Cert.
IVUSS

IMAGING PERFORMED BY

Dr. Susan Lincoski

HOSPITAL NAME

University Drive
Veterinary Hospital

REFERRING VET

Dr. Susan Lincoski

INVOICE

15907

DATE

05/07/26

PRESENTING CLINICAL SIGNS

On again/off again GI issues. Loose stool, gurgly stomach, decreased appetite at various times. Has been treated with fiber and tyran, as tested positive for CPA genes at high level last year. This did help the diarrhea but not the other GI issues. Drew GI panel for Texas A&M today since fasted.

Abnormal PE/Chem/CBC/UA Results: Normal exam Bloodwork pending for GI panel Unremarkable CBC/CS but last done fall 2025.

ULTRASONOGRAPHIC EXAMINATION OF THE ABDOMEN

Urinary System

The **urinary bladder**, trigone, and pelvic urethra to a depth of 2.0 cm presented normal thicknesses and normal tone. The ureters were not visible which is normal. No uroliths or sediment were visualized, and anechoic urine was present. No evidence of inflammatory or neoplastic changes were noted. Ureteral papillae were normal.

The **kidneys** revealed largely normal size and structure, corticomedullary definition and ratio (cortex 1/3 of medulla) were essentially maintained with some mild age-related loss of curvilinear patterns regarding the capsule and C/M junction. The cortices presented largely uniform texture with some increased echogenicity expected for his age patient. Medullary structure differed distinctly from that of the cortex and no evidence of pelvic dilation was present. The left kidney measured 6.77 cm in length. The right kidney measured 5.0 cm in length.

Adrenal Glands

Both **adrenal glands** were visualized and recognized as having normal shape, size, position and echogenicity for this breed. The phrenic vasculature, glandular echogenicity and detail were unremarkable. Capsule, cortex, and medullary definition were normal for this age patient. The left adrenal gland measured 1.64 cm x 0.55 cm width. The right adrenal gland measured 2.0 cm x 1.0 cm width.

Spleen

The **spleen** presented a smooth homogeneous parenchyma hyperechoic to liver and renal cortical parenchyma. The capsule was smooth without noticeable expansion or deviation from within the spleen or adjacent pathology. The splenic vasculature demonstrated normal volume without signs of congestion or thrombosis. No sonographic evidence of acute or chronic inflammatory, neoplastic, or infarctual changes were noted.

Liver

The **liver** images from right and left intercostal as well as subcostal views revealed subjectively normal liver size, contour, and structure. Some mild age-related parenchymal remodeling was noted but likely not clinically significant at this time. Vascular and biliary tracts were of normal volume and no evidence of congestion was noted. No overt evidence of active inflammatory, infiltrative or regenerative pathology was noted but should be paired with current or past LE elevations regarding any clinical significance to this presentation. The hepatic lymph nodes were unremarkable.



PATIENT

Truman Impellitteri

SPECIES

Canine

BREED

Rhodesian Ridgeback

SEX

Neutered Male

AGE

8

WEIGHT

116.9

INTERPRETED BY

Eric Lindquist, DMV,
DABVP(CFM), Cert.
IVUSS

IMAGING PERFORMED BY

Dr. Susan Lincoski

HOSPITAL NAME

University Drive
Veterinary Hospital

REFERRING VET

Dr. Susan Lincoski

INVOICE

15907

DATE

05/07/26

The gallbladder was mildly over distended with suspended and dependent debris, yet not to the level of emerging mucocele, yet sludge appears to be mildly excessive. No adjunctive inflammation was noted.

Gastrointestinal

The **gastrointestinal** presentation revealed minor uniform prominence of the gastric mucosa as well as areas of "ropey" small intestinal wall with slight disruption of the normal 1:3 muscularis/mucosal ratio. The intestinal submucosa was slightly irregular, thickened and hyperechoic suggestive of low grade, chronic disease. No concerning lymphadenopathy was visible. No evidence of obstruction was present. Chronic inflammatory bowel disease is likely with a low possibility of an early neoplastic event such as lymphoma. Full thickness tissue biopsies via open laparotomy, ideally guided by intraoperative ultrasound in order to obtain the most representative mural sample, would be necessary to rule out this possibility.

Pancreas

The base and limbs of the **pancreas** were observed to be largely isoechoic to surrounding omental fat. Pancreatic duct and capsular contour were acceptably normal and parenchyma respected normal curvilinear patterns. No overt evidence of active inflammatory or neoplastic disease was noted.

Free Abdomen

The mesenteric **lymph node** presented normal length to width ratio with slight, swollen contour. There was no loss of parenchymal detail. This is most consistent with reactive lymphadenitis or lymphatic hyperplasia. The lymph node measured 1.0 cm x 0.50 cm.

ULTRASONOGRAPHIC FINDINGS

- IBD GI pattern.
- Minor excessive gallbladder debris.
- Age-related abdominal changes otherwise.

INTERPRETATION OF THE FINDINGS & FURTHER RECOMMENDATIONS

Parasite management and diet change to hydrolyzed diet may prove effective. Ursodiol therapy is warranted. No evidence of gross pathology.



PATIENT

Truman Impellitteri

SPECIES

Canine

BREED

Rhodesian Ridgeback

SEX

Neutered Male

AGE

8

WEIGHT

116.9

INTERPRETED BY

Eric Lindquist, DMV,
DABVP(CFM), Cert.
IVUSS

IMAGING PERFORMED BY

Dr. Susan Lincoski

HOSPITAL NAME

University Drive
Veterinary Hospital

REFERRING VET

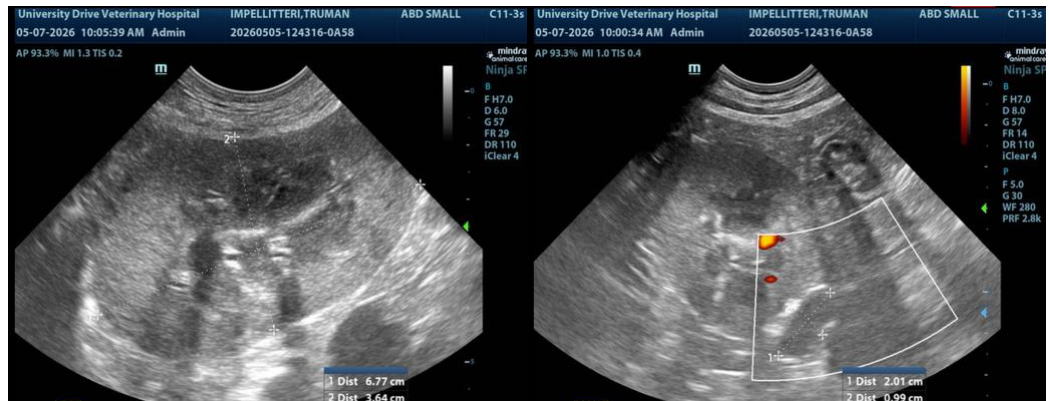
Dr. Susan Lincoski

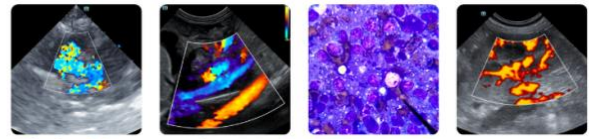
INVOICE

15907

DATE

05/07/26





PATIENT

Truman Impellitteri

SPECIES

Canine

BREED

Rhodesian Ridgeback

SEX

Neutered Male

AGE

8

WEIGHT

116.9

INTERPRETED BY

Eric Lindquist, DMV,
DABVP(CFM), Cert.
IVUSS

IMAGING PERFORMED BY

Dr. Susan Lincoski

HOSPITAL NAME

University Drive
Veterinary Hospital

REFERRING VET

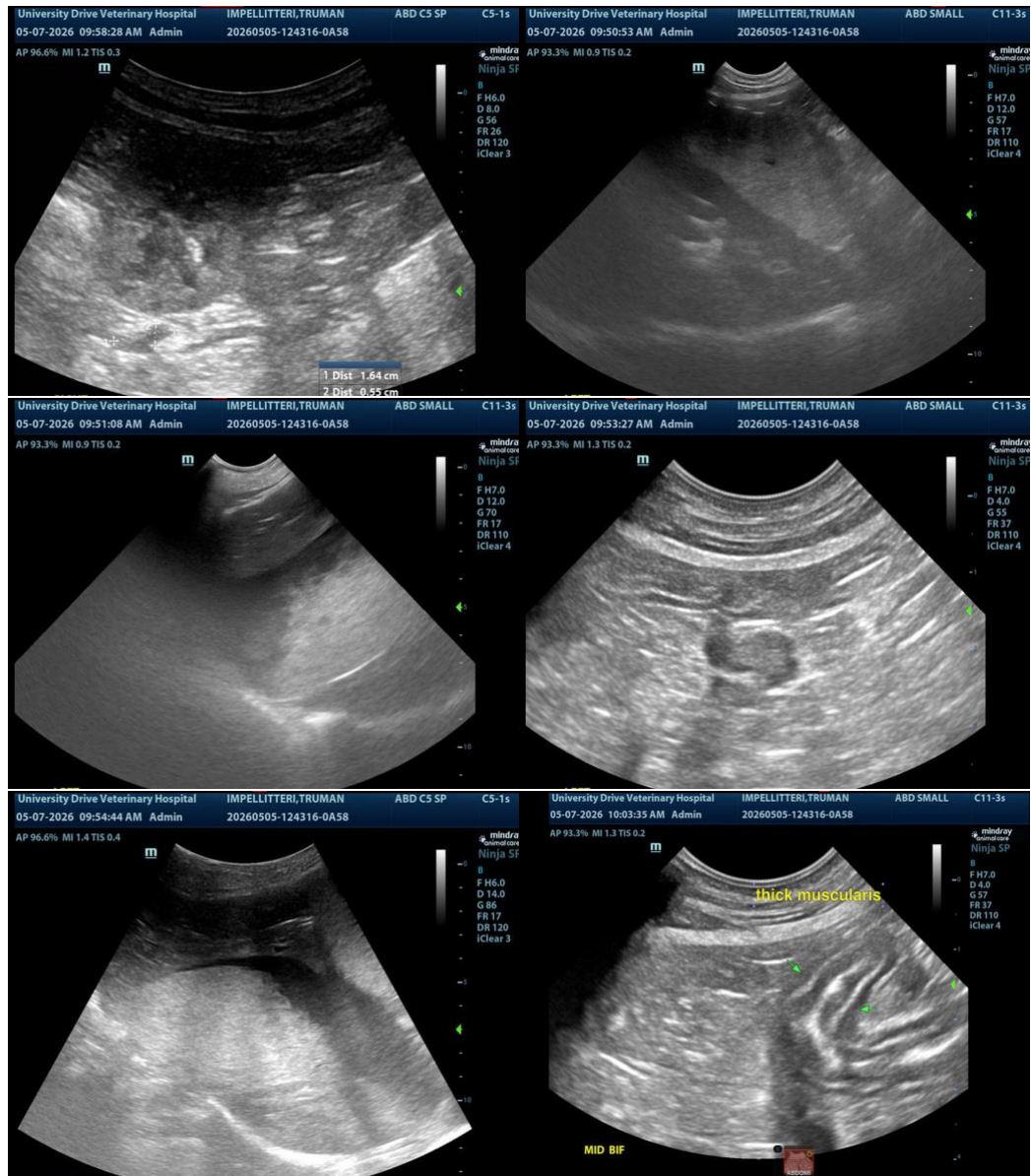
Dr. Susan Lincoski

INVOICE

15907

DATE

05/07/26



The information and recommendations provided are based on the images presented by the referring veterinarian/sonographer. No evaluation can be communicated regarding pathology that was not visible in the image/video clips provided.

Thank you for this referral. If the clinical or image interpretation does not parallel your findings or if I can be of any further assistance, please contact me.

Eric Lindquist, DMV, DABVP(CFM), Cert. IVUSS,

CEO, Owner, Founder -- SonoPath.com

info@SonoPath.com



PATIENT

Truman Impellitteri

SPECIES

Canine

BREED

Rhodesian Ridgeback

SEX

Neutered Male

AGE

8

WEIGHT

116.9

INTERPRETED BY

Eric Lindquist, DMV,
DABVP(CFM), Cert.
IVUSS

IMAGING PERFORMED BY

Dr. Susan Lincoski

HOSPITAL NAME

University Drive
Veterinary Hospital

REFERRING VET

Dr. Susan Lincoski

INVOICE

15907

DATE

05/07/26