



PATIENT

Piggy Banfield

SPECIES

Canine

BREED

Lhasa Apso Mix

SEX

Spayed Female

AGE

13 Years

WEIGHT

22.4

INTERPRETED BY

Eric Lindquist, DMV,
DABVP(CFM), Cert.
IVUSS

IMAGING PERFORMED BY

Heather

HOSPITAL NAME

Animal Care Clinic of
Flanders

REFERRING VET

Dr. Casulli

INVOICE

15882

DATE

05/07/26

PRESENTING CLINICAL SIGNS

r/o Cushing's, tumor hunt

Abnormal PE/Chem/CBC/UA Results: rbc - 5.54, platelets- 468. glu - 139, chol - 445, trig - 3831

ULTRASONOGRAPHIC EXAMINATION OF THE HEART & ABDOMEN

CANINE CARDIAC PARAMETERS	MR VMAX (m/s)	TR VMAX (m/s)	LA/AO (M-Mode)	LA/AO (Heart Base; Swe)	FS (%)	EF (%)	EPSS (cm)
NORMAL PARAMETER	4.5-5.5	<2.7	1.3	Up to 1.6	28-40	40-100	<0.6
PATIENT	--	--	1.0	1.3	50	--	0.1
CANINE CARDIAC PARAMETERS	HR (BPM)	AV VMAX (m/s)	PV MAX (m/s)	BODY WEIGHT	LAD LA MAX 4 Chamber	LVIDd Avg; 2D and m-mode short axis (cm)	LVIDs Avg; 2D and m-mode short axis (cm)
NORMAL PARAMETER	50-100	0.7-1.7	0.7-1.6				
PATIENT	NM	1.3	1.1	22.4	2.9	2.5	--

Cardiac Presentation

The echocardiogram in this patient demonstrated normal **left atrial** size based on 3 separate methods of LA evaluation. The cranial and caudal **mitral** valve leaflets presented normal linear structure, extension in systole, and union in diastole with normal kinesis. The **left ventricle** presented normal thicknesses with linear contour and was not dilated nor restricted. The **myocardium** presented normal echogenicity without subjective evidence of significant fibrotic or ischemic disease. **Contractility** of the ventricular walls was adequate and in normal range for this patient evidenced by the fractional shortening measurement and subjective evaluation of the different regions of the myocardium. The **left ventricular outflow** tract demonstrated normal laminar flow and subjective structural integrity. The **right atrium** and auricle revealed normal size, structure and content. No evidence of masses was noted. **Tricuspid** valvular assessment demonstrated adequate linear morphology and kinesis. The **right ventricle** was of normal size (1/3 diameter of LV), chordae structure, myocardial echogenicity and thickness. **Pulmonary outflow** tract assessment revealed normal valve structure, laminar flow, and diameter (approx.1:1 pa/ao ratio). No visible **pericardial** or free pleura fluid was noted. The cranial **mediastinum** and **pericardial** and **extra-cardiac** regions were free of masses in the visible window.

Urinary System

The **urinary bladder** presented mild to moderate thickening of the cranioventral and craniodorsal mucosae with micropolypoid mucosal changes without involvement of the submucosae. The urine presented some echogenicity consistent with suspended debris. No evidence of urethral pathology was present. This presentation is most consistent with chronic cystitis. Technically transitional cell



PATIENT

Piggy Banfield

SPECIES

Canine

BREED

Lhasa Apso Mix

SEX

Spayed Female

AGE

13 Years

WEIGHT

22.4

INTERPRETED BY

Eric Lindquist, DMV,
DABVP(CFM), Cert.
IVUSS

IMAGING PERFORMED BY

Heather

HOSPITAL NAME

Animal Care Clinic of
Flanders

REFERRING VET

Dr. Casulli

INVOICE

15882

DATE

05/07/26

carcinoma cannot be ruled out without histopathological review but is not overtly suspected based on this pattern. Cystocentesis and urine culture +/- pathological review of urine cytology would be warranted. No overt calculi were present at this time.

The **kidneys** revealed largely normal size and structure, corticomedullary definition and ratio (cortex 1/3 of medulla) were essentially maintained with some mild age-related loss of curvilinear patterns regarding the capsule and C/M junction. The cortices presented largely uniform texture with some increased echogenicity expected for his age patient. Medullary structure differed distinctly from that of the cortex. Slight pyelectasia was present. The left kidney measured 4.6 cm in length. The right kidney measured 4.3 cm in length.

Adrenal Glands

The regions of the **adrenal glands** were imaged with no evident pathology.

Spleen

The **spleen** presented a smooth homogeneous parenchyma hyperechoic to liver and renal cortical parenchyma. The capsule was smooth without noticeable expansion or deviation from within the spleen or adjacent pathology. The splenic vasculature demonstrated normal volume without signs of congestion or thrombosis. No sonographic evidence of acute or chronic inflammatory, neoplastic, or infarctual changes were noted.

Liver

The **liver** presented heterogenous parenchyma with increased portal markings and coarse architecture. Slight undulating capsular contour was noted. The gallbladder and common bile duct were unremarkable. This is consistent with chronic inflammatory hepatopathy.

Gastrointestinal

The **gastrointestinal tract** presented considerable gastric artifact due to the presence of ingesta. This did not permit thorough evaluation of portions of the gastric and upper intestinal structure. No overt abnormality was seen in the visualized tissue, however. This is consistent with a post-prandial presentation within a few hours of mealtime. If the prandial temporal interval does not fit the case history, and the patient presents a history of post-prandial vomiting, this could indicate a delayed upper gastrointestinal outflow due to primary or secondary pyloric hypertrophy, upper GI infiltrative disease, motor deficits, or a non-visualized foreign body. A prudent approach would be to rescan this patient at 24 hour NPO status to further review the non-visible regions if stomach primarily as well as assess any delayed outflow issue.

Pancreas

The base and limbs of the **pancreas** were observed to be largely isoechoic to surrounding omental fat. Pancreatic duct and capsular contour were acceptably normal and parenchyma respected normal curvilinear patterns. No overt evidence of active inflammatory or neoplastic disease was noted.

ULTRASONOGRAPHIC FINDINGS

- Normal echocardiogram- no evidence of pathology.
- Full stomach.
- Age-related renal changes with slight pyelectasia.
- Vacuolar hepatopathy liver pattern with remodeling.



PATIENT

Piggy Banfield

SPECIES

Canine

BREED

Lhasa Apso Mix

SEX

Spayed Female

AGE

13 Years

WEIGHT

22.4

INTERPRETED BY

Eric Lindquist, DMV,
DABVP(CFM), Cert.
IVUSS

IMAGING PERFORMED BY

Heather

HOSPITAL NAME

Animal Care Clinic of
Flanders

REFERRING VET

Dr. Casulli

INVOICE

15882

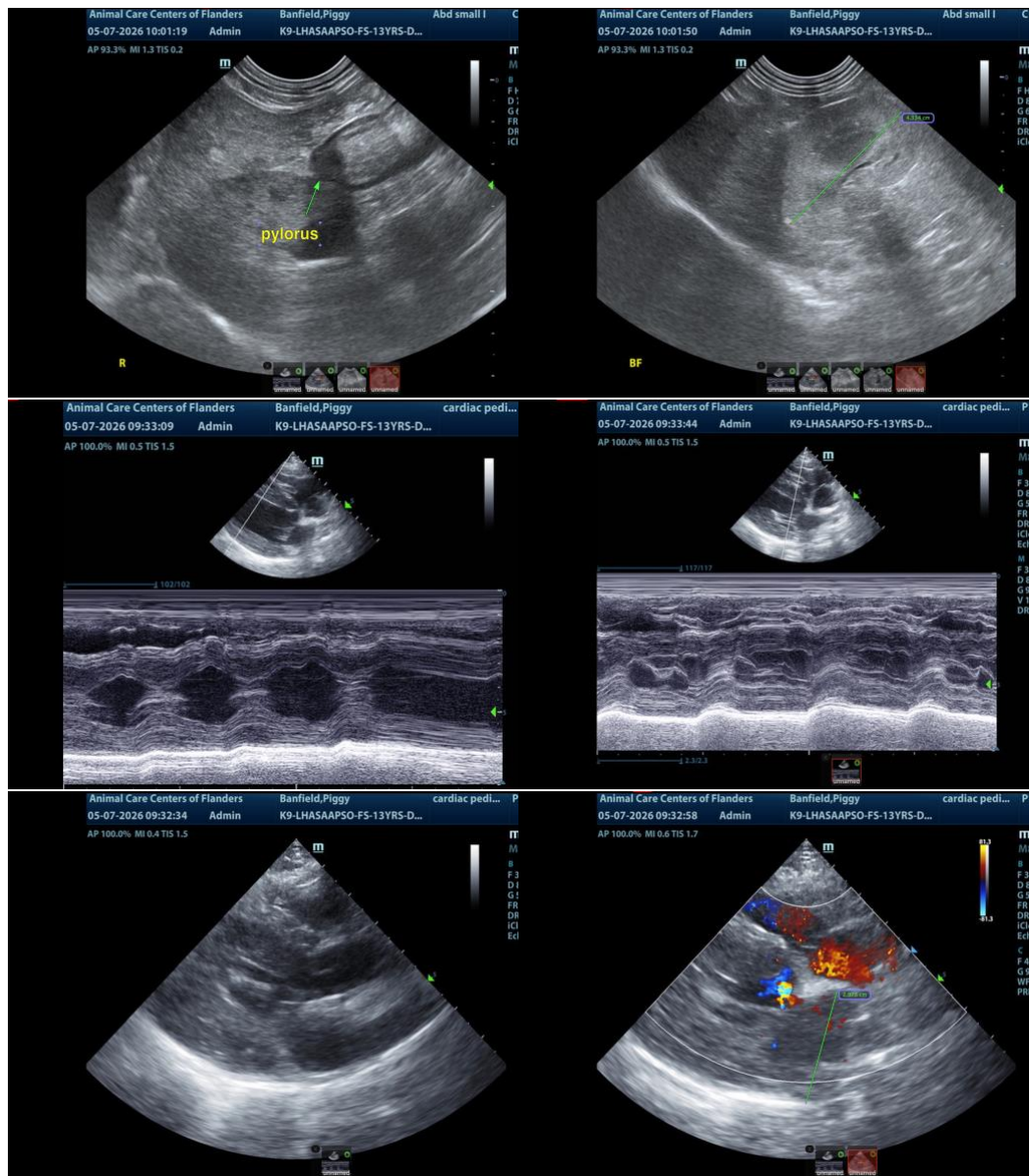
DATE

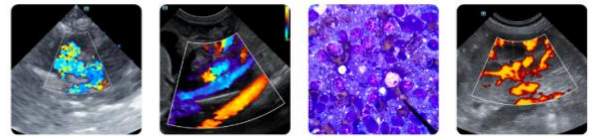
05/07/26

- Chronic cystitis bladder pattern.

INTERPRETATION OF THE FINDINGS & FURTHER RECOMMENDATIONS

No evidence of adrenal pathology. Full urinary work up is warranted.





PATIENT

Piggy Banfield

SPECIES

Canine

BREED

Lhasa Apso Mix

SEX

Spayed Female

AGE

13 Years

WEIGHT

22.4

INTERPRETED BY

Eric Lindquist, DMV,
DABVP(CFM), Cert.
IVUSS

IMAGING PERFORMED BY

Heather

HOSPITAL NAME

Animal Care Clinic of
Flanders

REFERRING VET

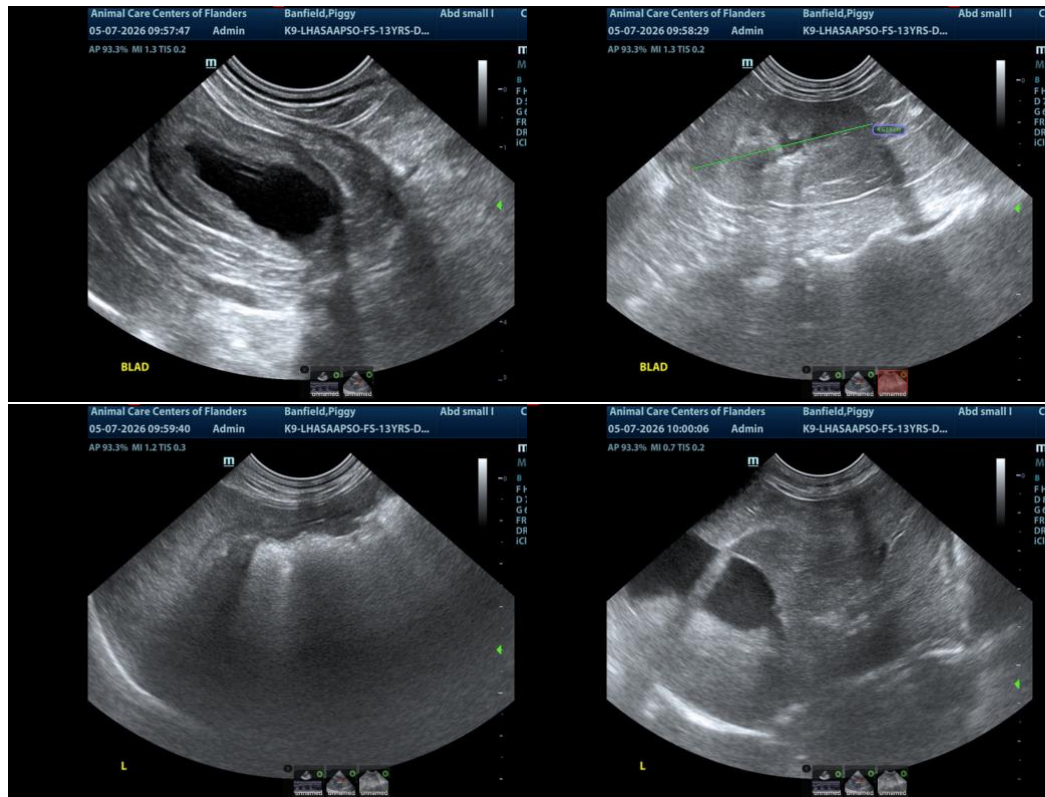
Dr. Casulli

INVOICE

15882

DATE

05/07/26



The information and recommendations provided are based on the images presented by the referring veterinarian/sonographer. No evaluation can be communicated regarding pathology that was not visible in the image/video clips provided.

Thank you for this referral. If the clinical or image interpretation does not parallel your findings or if I can be of any further assistance, please contact me.

Eric Lindquist, DMV, DABVP(CFM), Cert. IVUSS,

CEO, Owner, Founder -- SonoPath.com

info@SonoPath.com