



PATIENT

Jamison Pontrelli

SPECIES

Canine

BREED

Mix

SEX

Neutered Male

AGE

9 Years 9 Months

WEIGHT

18 lbs

INTERPRETED BY

Eric Lindquist, DMV,
 DABVP(CFM), Cert.
 IVUSS

IMAGING PERFORMED BY

Chloe Lowe CVT

HOSPITAL NAME

William Penn
 Veterinary Hospital

REFERRING VET

Dr. Bouzaout

INVOICE

15919

DATE

05/07/26

PRESENTING CLINICAL SIGNS

Recheck per previous echo recommendation. Early stage B2 valvular disease. Murmur 5/6. BP average MAP 115-120. Sys 142 Dia 102. Pimobendan 2.5 mg BID

Abnormal PE/Chem/CBC/UA Results: WNL

ULTRASONOGRAPHIC EXAMINATION OF THE HEART

CANINE CARDIAC PARAMETERS	MR VMAX (m/s)	TR VMAX (m/s)	LA/AO (M-Mode)	LA/AO (Heart Base; Swe)	FS (%)	EF (%)	EPSS (cm)
NORMAL PARAMETER	4.5-5.5	<2.7	1.3	Up to 1.6	28-40	40-100	<0.6
PATIENT	6.0	2.8	NM	1.8	34	64	0.3
CANINE CARDIAC PARAMETERS	HR (BPM)	AV VMAX (m/s)	PV MAX (m/s)	BODY WEIGHT (lbs)	LAD LA MAX 4 Chamber	LVIDd Avg; 2D and m-mode short axis (cm)	LVIDs Avg; 2D and m-mode short axis (cm)
NORMAL PARAMETER	50-100	0.7-1.7	0.7-1.6				
PATIENT	156	1.3	--	18	4.13	3.17	--

E-wave Velocity: 1.4

Cardiac Presentation

The cardiac presentation in this patient presented with progressive volume overload of the left atrium and left ventricle with complete filling of the left atrium on color flow assessment of the mitral valve, indicative of severe mitral insufficiency. Tricuspid insufficiency was present yet fairly well contained. The hepatic veins were not dilated. No pericardial or pleural effusion was present. The right heart was unremarkable other than the tricuspid insufficiency. Myocardial contractility was adequate. No evidence of masses.

ULTRASONOGRAPHIC FINDINGS

- Mild decompensation of B2 valvular disease compared to the prior echocardiogram.

INTERPRETATION OF THE FINDINGS & FURTHER RECOMMENDATIONS

I recommend adding an ACE inhibitor to the current Pimobendan protocol at 0.50 mg/kg SID, progressing to BID and spironolactone at 1-2 mg/kg SID. Recheck echo in six months if the patient is stable.



PATIENT

Jamison Pontrelli

SPECIES

Canine

BREED

Mix

SEX

Neutered Male

AGE

9 Years 9 Months

WEIGHT

18 lbs

INTERPRETED BY

Eric Lindquist, DMV,
 DABVP(CFM), Cert.
 IUUSS

IMAGING PERFORMED BY

Chloe Lowe CVT

HOSPITAL NAME

William Penn
 Veterinary Hospital

REFERRING VET

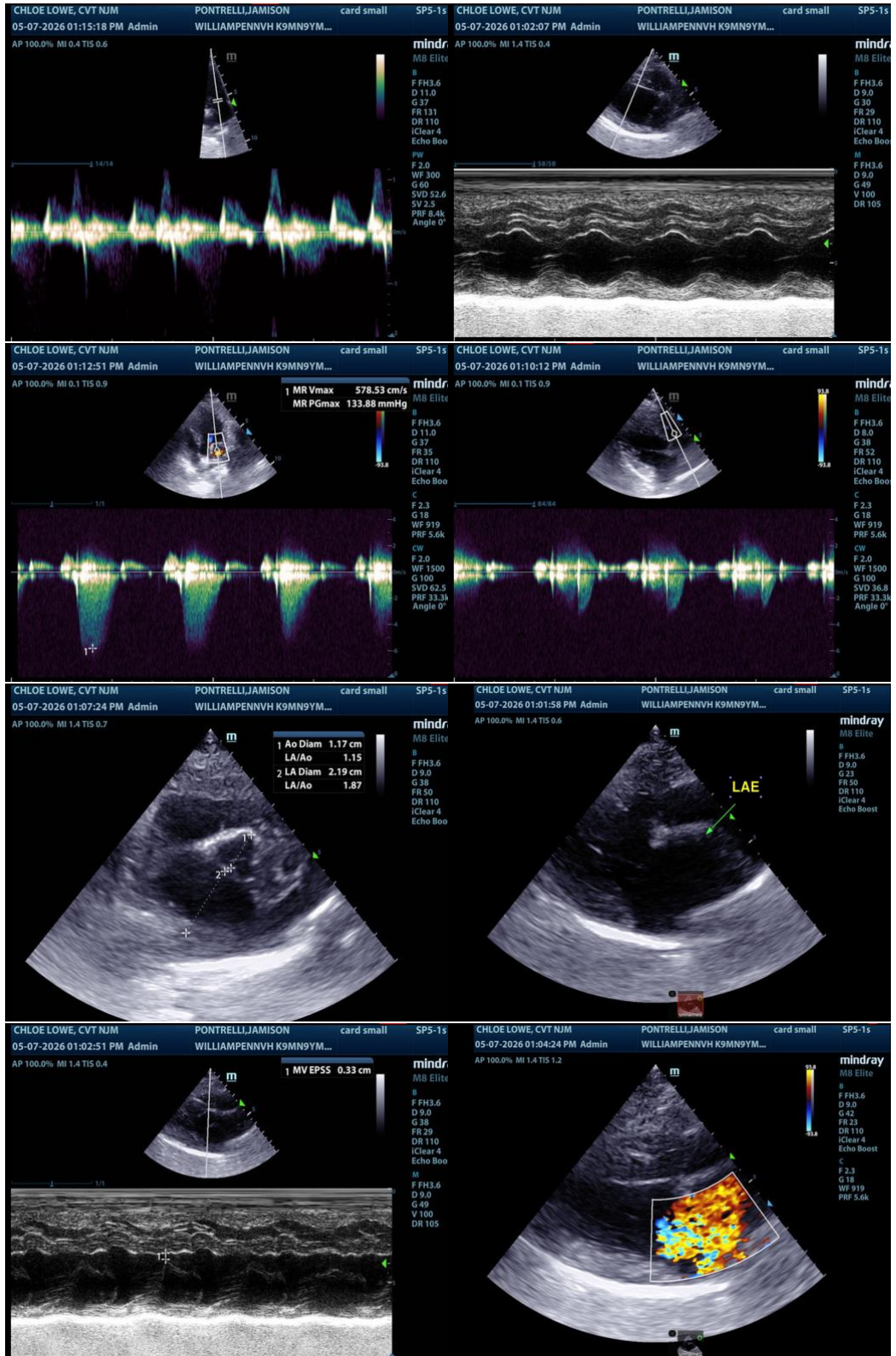
Dr. Bouzaout

INVOICE

15919

DATE

05/07/26





PATIENT

Jamison Pontrelli

SPECIES

Canine

BREED

Mix

SEX

Neutered Male

AGE

9 Years 9 Months

WEIGHT

18 lbs

INTERPRETED BY

Eric Lindquist, DMV,
 DABVP(CFM), Cert.
 IVUSS

IMAGING PERFORMED BY

Chloe Lowe CVT

HOSPITAL NAME

William Penn
 Veterinary Hospital

REFERRING VET

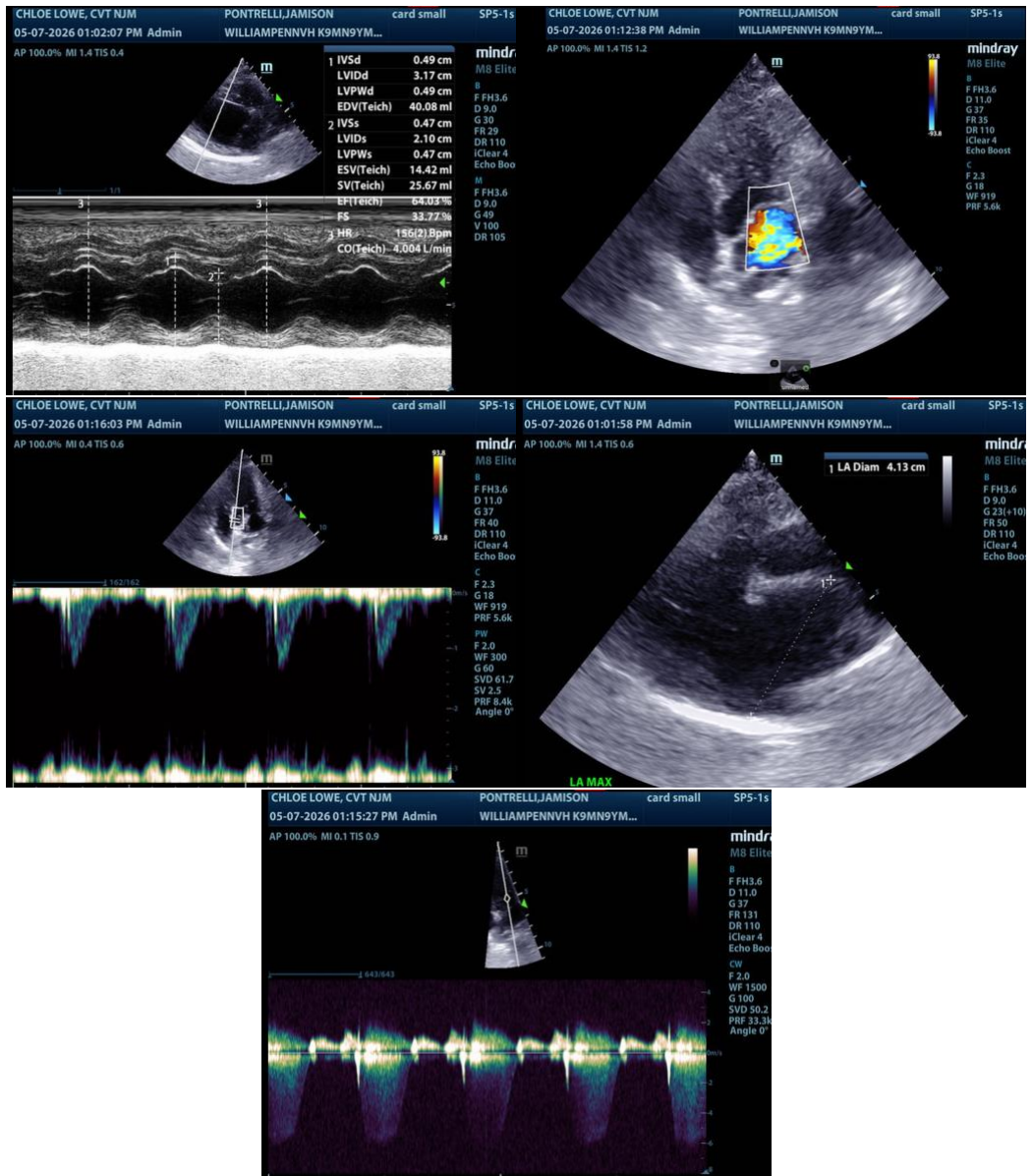
Dr. Bouzaout

INVOICE

15919

DATE

05/07/26



The information and recommendations provided are based on the images presented by the referring veterinarian/sonographer. No evaluation can be communicated regarding pathology that was not visible in the image/video clips provided.

Thank you for this referral. If the clinical or image interpretation does not parallel your findings or if I can be of any further assistance, please contact me.

Eric Lindquist, DMV, DABVP(CFM), Cert. IVUSS,

CEO, Owner, Founder -- SonoPath.com

info@SonoPath.com



PATIENT

Jamison Pontrelli

SPECIES

Canine

BREED

Mix

SEX

Neutered Male

AGE

9 Years 9 Months

WEIGHT

18 lbs

INTERPRETED BY

Eric Lindquist, DMV,
DABVP(CFM), Cert.
IVUSS

**IMAGING
PERFORMED BY**

Chloe Lowe CVT

HOSPITAL NAME

William Penn
Veterinary Hospital

REFERRING VET

Dr. Bouzaout

INVOICE

15919

DATE

05/07/26