



PATIENT

Gunny Atkinson

SPECIES

Canine

BREED

Dogo Argentino

SEX

Male

AGE

8 Years

WEIGHT

43.18 kg

INTERPRETED BY

Eric Lindquist, DMV,
DABVP(CFM), Cert.
IVUSS

IMAGING PERFORMED BY

Dr. Trudeau

HOSPITAL NAME

Vetcetera Animal
Hospital

REFERRING VET

Dr. Trudeau

INVOICE

15905

DATE

05/07/26

PRESENTING CLINICAL SIGNS

Owner is concerned for a suspected injury with back end weakness persisting. Mild muscle wasting noted and minimal activity over the last 6 months. Reduced appetite since a course of doxycycline in November. Assessing the abdomen to R/O any cause internally

CBC - NSF Chem: ALP 219 U/L (20.0 150.0) ALT 462 U/L (10.0 118) otherwise NSF X-rays of spine, elbows, hips and knees are pending from a radiologist

ULTRASONOGRAPHIC EXAMINATION OF THE ABDOMEN

Urinary System

The **urinary bladder**, trigone, and pelvic urethra presented normal thicknesses and normal tone. The ureters were not visible which is normal. No uroliths or sediment were visualized, and anechoic urine was present. No evidence of inflammatory or neoplastic changes were noted. Ureteral papillae were normal.

The **prostate** was mildly enlarged with lobar swelling appeared to impinge upon the urethra and mildly deviate the descending colon. The prostatic tissue was hyperechoic containing focal areas of decreased echogenicity. These changes are suggestive of either chronic inflammatory episodes, benign cystic pathology or both. Underlying neoplasia cannot be completely ruled-out but is lower on the differential list. This presentation is most consistent with benign prostatic hyperplasia with possible active prostatitis. Neutering or off-label Finasteride (Propecia) (0.1-0.5 mg/kg Sid) treatment is indicated +/- FNA or prostatic wash cytology and culture. The prostate measured 5.8 cm width.

The **kidneys** revealed normal size and structure, corticomedullary definition and ratio for this age. The cortices presented largely uniform texture with normal echogenic relationship to liver and spleen. Medullary structure differed distinctly from the cortex and no evidence of pelvic dilation was present. The capsules were acceptably uniform without significant irregularities. The left kidney measured 7.8 cm in length. The right kidney measured 7.5 cm in length.

Adrenal Glands

Both **adrenal glands** were visualized and recognized as having normal shape, size, position and echogenicity for this breed. The phrenic vasculature, glandular echogenicity and detail were unremarkable. Capsule, cortex, and medullary definition were normal for this age patient. The right adrenal gland measured 0.57 cm width at the caudal pole and 0.90 cm width at the cranial pole. The left adrenal gland measured 0.72 cm width at the caudal pole and 0.56 cm width at the cranial pole.

Spleen

The **spleen** presented a smooth homogeneous parenchyma hyperechoic to liver and renal cortical parenchyma. The capsule was smooth without noticeable expansion or deviation from within the spleen or adjacent pathology. The splenic vasculature demonstrated normal volume without signs of congestion or thrombosis. No sonographic evidence of acute or chronic inflammatory, neoplastic, or infarctual changes were noted. The spleen was folded upon itself caudally.

Liver

The **liver** images submitted revealed subjectively normal liver size, contour, and structure. Parenchymal echogenicity was naturally coarse and hypoechoic to the spleen. Vascular and biliary



PATIENT

Gunny Atkinson

SPECIES

Canine

BREED

Dogo Argentino

SEX

Male

AGE

8 Years

WEIGHT

43.18 kg

INTERPRETED BY

Eric Lindquist, DMV,
DABVP(CFM), Cert.
IVUSS

IMAGING PERFORMED BY

Dr. Trudeau

HOSPITAL NAME

Vetcetera Animal
Hospital

REFERRING VET

Dr. Trudeau

INVOICE

15905

DATE

05/07/26

tracts were of normal volume with no evidence of congestion. The gallbladder presented acceptably thin walls with primarily anechoic content. The cystic and common bile ducts were normal. No pathological hepatic lymphadenopathy was evident. No overt structural evidence of inflammatory, infiltrative or regenerative pathology was evident.

Gastrointestinal

Examination of the **gastrointestinal tract** revealed a stomach and intestine free of stasis, of normal wall thickness, acceptable curvilinear mural detail, and peristaltic activity. Small and large intestine demonstrated normal luminal chyme and stool consistency respectively. No obstructive or overt infiltrative disease was noted. No associated abnormal lymphatic activity was noted. Deviation of the descending colon was noted by the prostate.

Pancreas

The base and limbs of the **pancreas** were observed to be largely isoechoic to surrounding omental fat. Pancreatic duct and capsular contour were acceptably normal and parenchyma respected normal curvilinear patterns. No overt evidence of active inflammatory or neoplastic disease was noted.

ULTRASONOGRAPHIC FINDINGS

- BPH prostate.
- Folded spleen.
- Deviated colon.

INTERPRETATION OF THE FINDINGS & FURTHER RECOMMENDATIONS

Neutering should be considered in this patient given the size of the prostate. If neutering is not an option, the following protocol may prove effective. Finasteride at 1 mg/kg/day can be utilized as an off-label approach to reducing prostatic size in BPH cases. Coverage for prostatitis would also likely be appropriate with Fluoroquinolone/Baytril or similar. A recheck sonogram is recommended in 3-4 weeks with reassessment of the urinalysis and evaluation of any inflammatory sediment.

FNA of the liver could be considered for further definition to define inflammatory cell type and neoplasia is not suspected and structurally the liver appeared unremarkable.



PATIENT

Gunny Atkinson

SPECIES

Canine

BREED

Dogo Argentino

SEX

Male

AGE

8 Years

WEIGHT

43.18 kg

INTERPRETED BY

Eric Lindquist, DMV,
DABVP(CFM), Cert.
IVUSS

IMAGING PERFORMED BY

Dr. Trudeau

HOSPITAL NAME

Vetcetera Animal
Hospital

REFERRING VET

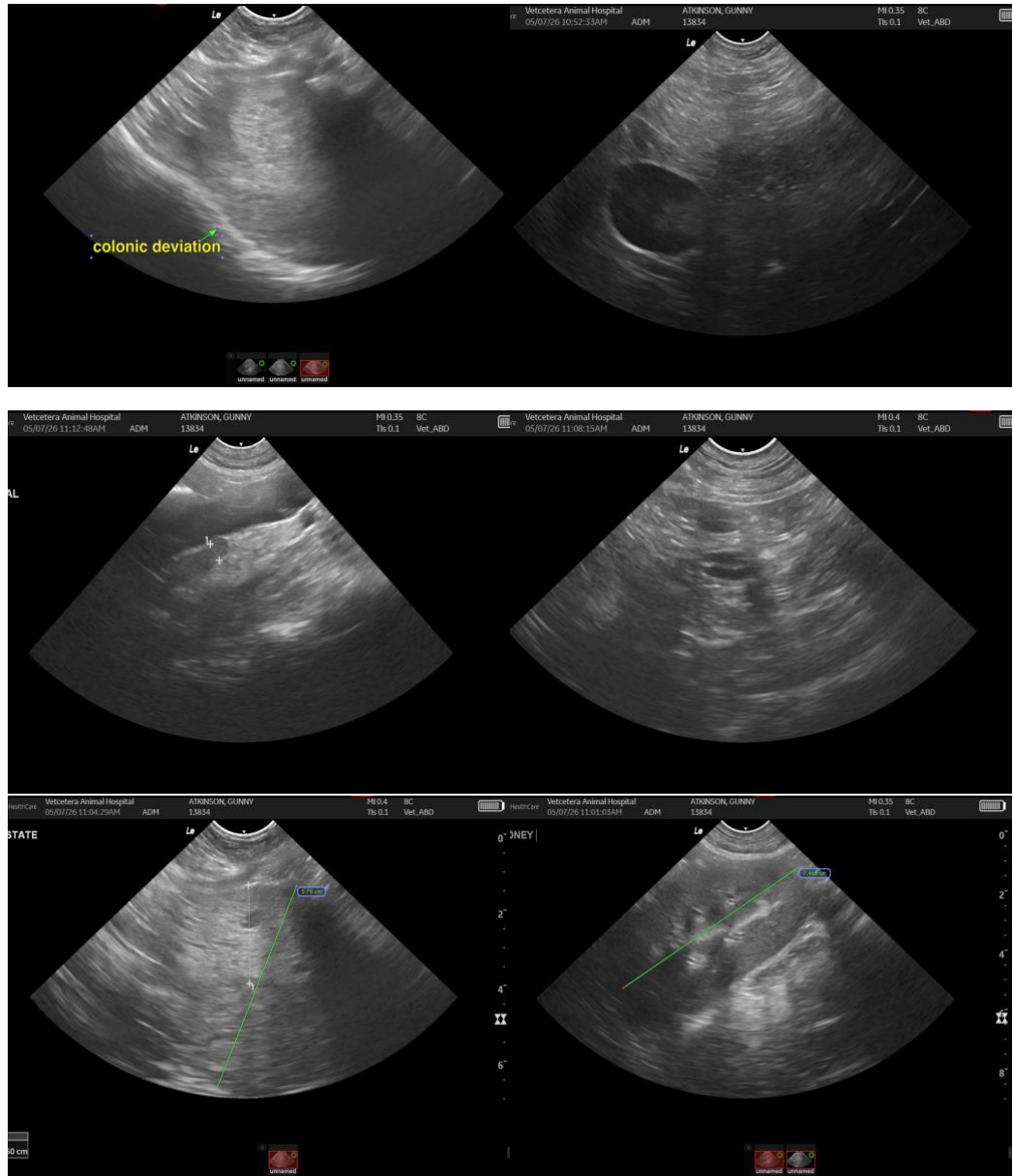
Dr. Trudeau

INVOICE

15905

DATE

05/07/26





PATIENT

Gunny Atkinson

SPECIES

Canine

BREED

Dogo Argentino

SEX

Male

AGE

8 Years

WEIGHT

43.18 kg

INTERPRETED BY

Eric Lindquist, DMV,
DABVP(CFM), Cert.
IVUSS

IMAGING PERFORMED BY

Dr. Trudeau

HOSPITAL NAME

Vetcetera Animal
Hospital

REFERRING VET

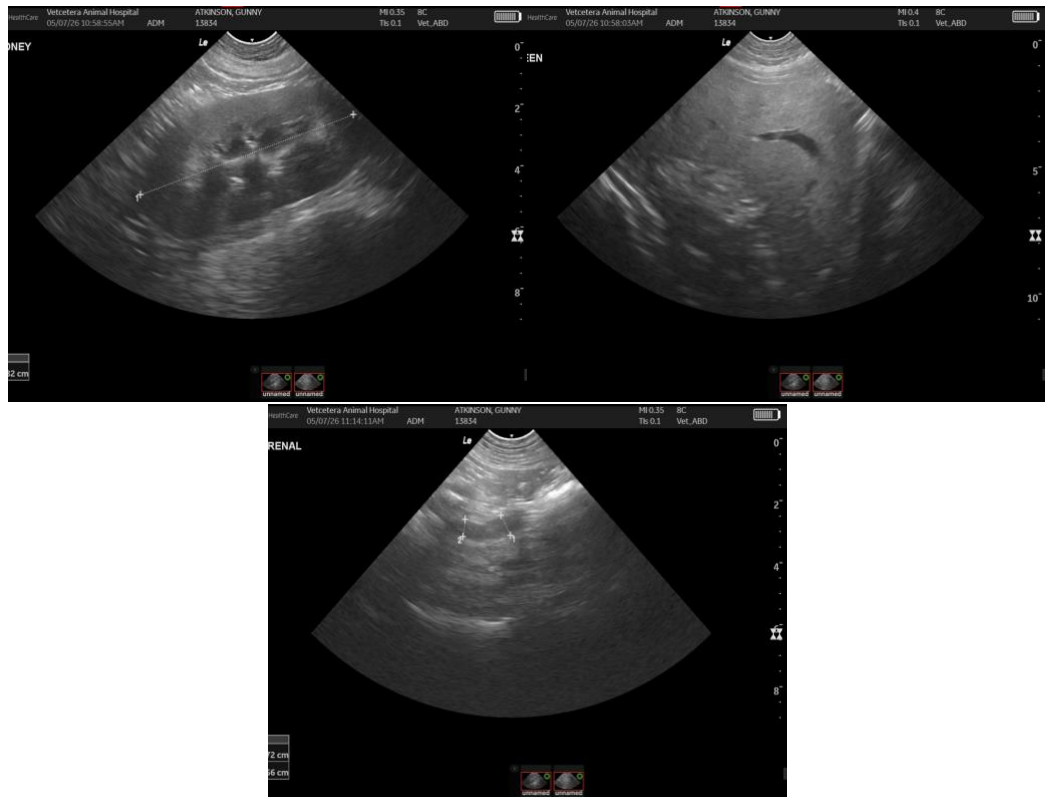
Dr. Trudeau

INVOICE

15905

DATE

05/07/26



The information and recommendations provided are based on the images presented by the referring veterinarian/sonographer. No evaluation can be communicated regarding pathology that was not visible in the image/video clips provided.

Thank you for this referral. If the clinical or image interpretation does not parallel your findings or if I can be of any further assistance, please contact me.

Eric Lindquist, DMV, DABVP(CFM), Cert. IVUSS,

CEO, Owner, Founder -- SonoPath.com

info@SonoPath.com