



PATIENT

Cody Larkowski

SPECIES

Canine

BREED

Beagle Mix

SEX

Neutered Male

AGE

10 Years 11 Months

WEIGHT

25.7 lbs

INTERPRETED BY

Eric Lindquist, DMV,
DABVP(CFM), Cert.
IVUSS

IMAGING PERFORMED BY

Shari Reffi CVT

HOSPITAL NAME

Advanced Veterinary
Care

REFERRING VET

Dr. Voigt

INVOICE

15912

DATE

05/07/26

PRESENTING CLINICAL SIGNS

BCS 5/9. Had grade I/VI murmur a year ago; now grade III/VI and pt is coughing more with exercise. Lungs clear, otherwise appears in good health. Current Medications: Carprovet sid; Nexgard; Proheart

Abnormal PE/Chem/CBC/UA Results: ALT-147; ALP-497 (has been elevated in the past). UA: Pending when O brings in.

ULTRASONOGRAPHIC EXAMINATION OF THE HEART

CANINE CARDIAC PARAMETERS	MR VMAX (m/s)	TR VMAX (m/s)	LA/AO (M-Mode)	LA/AO (Heart Base; Swe)	FS (%)	EF (%)	EPSS (cm)
NORMAL PARAMETER	4.5-5.5	<2.7	1.3	Up to 1.6	28-40	40-100	<0.6
PATIENT	6.41	3.0	1.03	1.3	39	71	NM
CANINE CARDIAC PARAMETERS	HR (BPM)	AV VMAX (m/s)	PV MAX (m/s)	BODY WEIGHT (lbs)	LAD LA MAX 4 Chamber	LVIDd Avg; 2D and m-mode short axis (cm)	LVIDs Avg; 2D and m-mode short axis (cm)
NORMAL PARAMETER	50-100	0.7-1.7	0.7-1.6				
PATIENT	90	1.5	0.84	25.7	3.2	3.16	--

E-wave Velocity: 0.9

Cardiac Presentation

The echocardiogram in this patient demonstrated normal **left atrial** size based on 3 different LA measurement methods. Chamber volumes and echogenicity were normal. Prolapse of the anterior mitral valve leaflet was noted. Doppler indicated measurable insufficiency. The **left ventricle** presented normal thicknesses with linear contour and was not dilated nor restricted. The **myocardium** presented normal echogenicity without subjective evidence of significant fibrotic or ischemic disease. **Contractility** of the ventricular walls was adequate and in normal range for this patient evidenced by the fractional shortening measurement and subjective evaluation of the different regions of the myocardium. The **left ventricular outflow** tract demonstrated normal laminar flow and subjective structural integrity. The **right atrium** and auricle revealed normal size, structure and content. No evidence of masses was noted or chamber overload. **Tricuspid** valvular assessment demonstrated adequate linear morphology. The **right ventricle** was of normal size (1/3 diameter of LV), chordae structure, myocardial echogenicity and thickness. **Pulmonic** tract assessment revealed normal valve structure, laminar flow, and diameter (approx.1:1 pa/ao ratio). No visible **pericardial** or free pleura fluid was noted. No echographically detectable evidence of infiltrative disease was visible. The cranial **mediastinum and pericardial regions** were free of masses in the visible window. The hepatic veins were not dilated.

ULTRASONOGRAPHIC FINDINGS



PATIENT

Cody Larkowski

- Compensated mitral valve insufficiency without volume overload.
- Stage B1 valvular disease.
- Tricuspid insufficiency.

SPECIES

Canine

BREED

Beagle Mix

SEX

Neutered Male

AGE

10 Years 11 Months

WEIGHT

25.7 lbs

INTERPRETED BY

Eric Lindquist, DMV,
 DABVP(CFM), Cert.
 IVUSS

IMAGING PERFORMED BY

Shari Reffi CVT

HOSPITAL NAME

Advanced Veterinary
 Care

REFERRING VET

Dr. Voigt

INVOICE

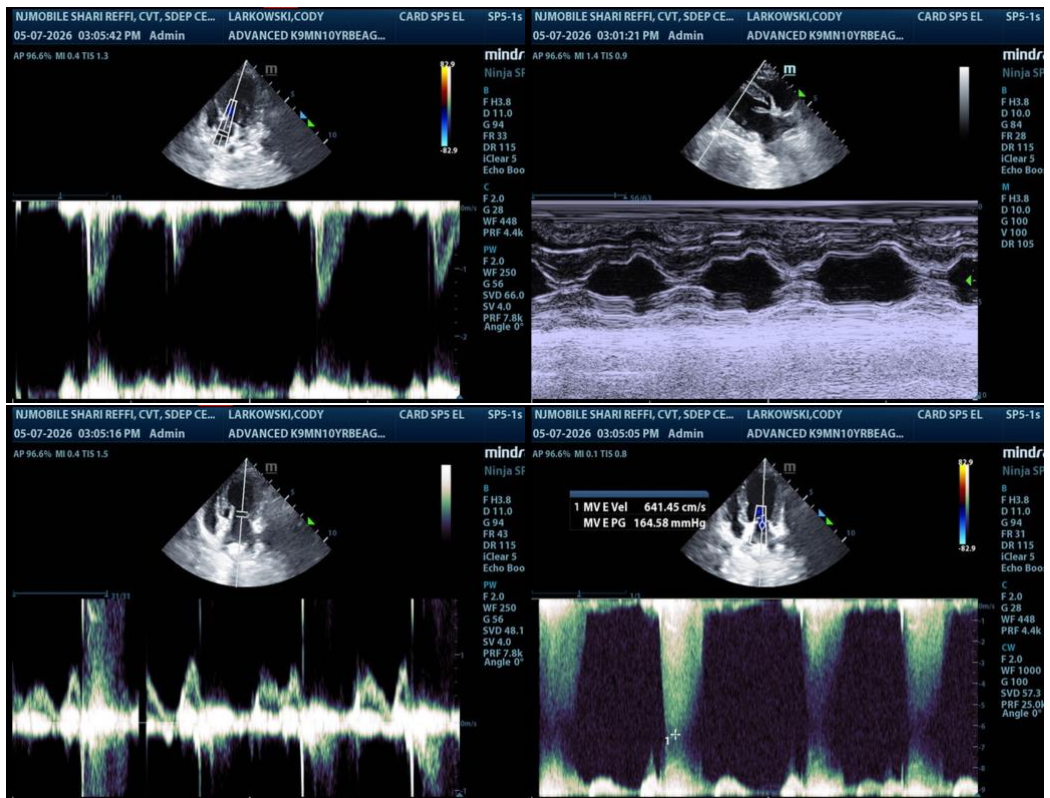
15912

DATE

05/07/26

INTERPRETATION OF THE FINDINGS & FURTHER RECOMMENDATIONS

The heart is stable without clinical disease. No overt contraindication for anesthesia of brief to moderate duration. I suggest Torbutrol premed, Propofol induction, Isoflor maintenance or similar protocol if anesthesia is desired. Blood pressure, EKG and chest radiographs are recommended if not already performed. Target white coat negative systolic pressure of < 160 mmHg. If higher than this ACE-inhibitor is suggested to reach this level. Recheck echocardiogram is recommended in 6-12 months, earlier if murmur grade increases or clinical signs initiate.





PATIENT

Cody Larkowski

SPECIES

Canine

BREED

Beagle Mix

SEX

Neutered Male

AGE

10 Years 11 Months

WEIGHT

25.7 lbs

INTERPRETED BY

Eric Lindquist, DMV,
 DABVP(CFM), Cert.
 IVUSS

IMAGING PERFORMED BY

Shari Reffi CVT

HOSPITAL NAME

Advanced Veterinary
 Care

REFERRING VET

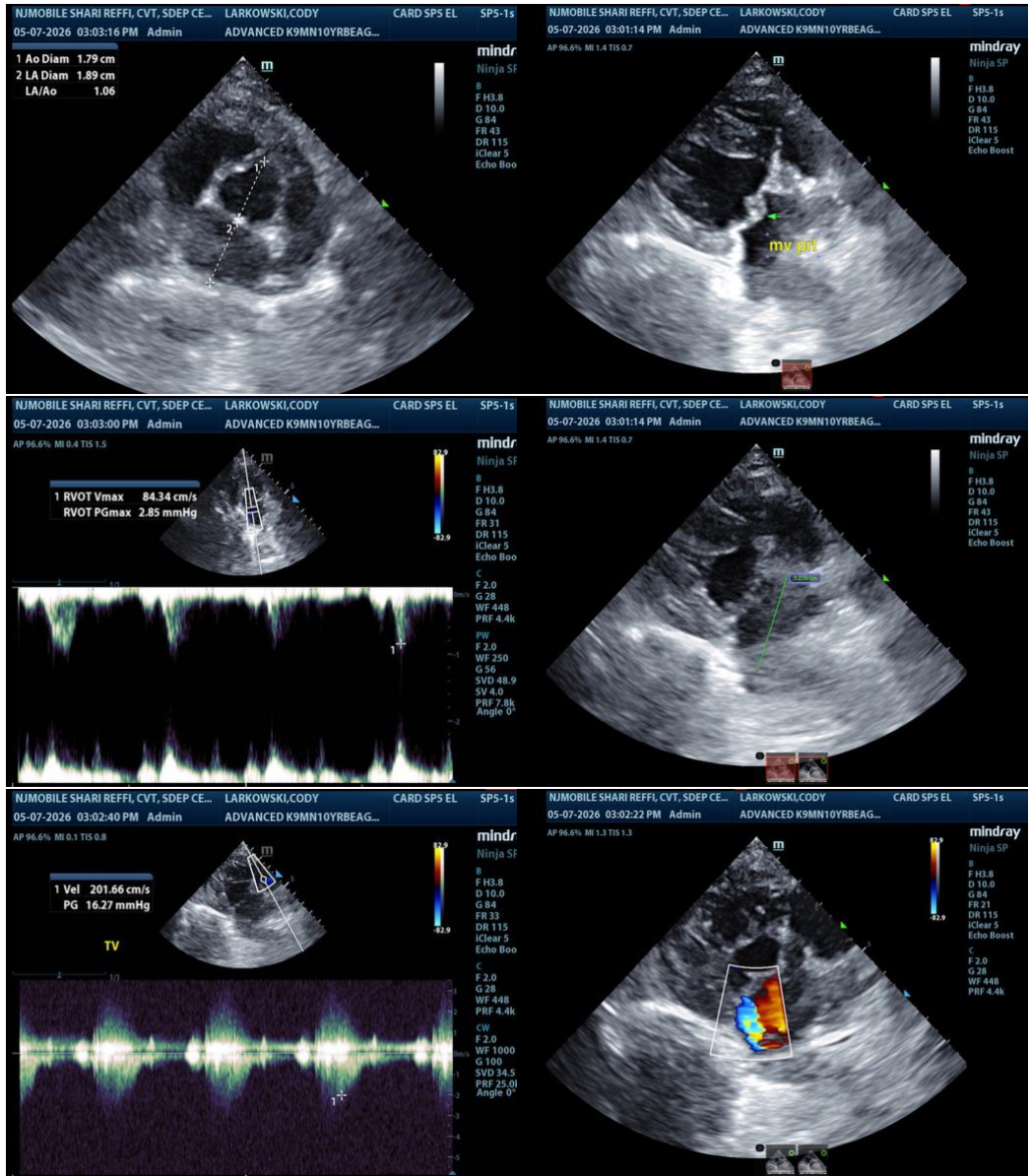
Dr. Voigt

INVOICE

15912

DATE

05/07/26





PATIENT

Cody Larkowski

SPECIES

Canine

BREED

Beagle Mix

SEX

Neutered Male

AGE

10 Years 11 Months

WEIGHT

25.7 lbs

INTERPRETED BY

Eric Lindquist, DMV,
DABVP(CFM), Cert.
IVUSS

IMAGING PERFORMED BY

Shari Reffi CVT

HOSPITAL NAME

Advanced Veterinary
Care

REFERRING VET

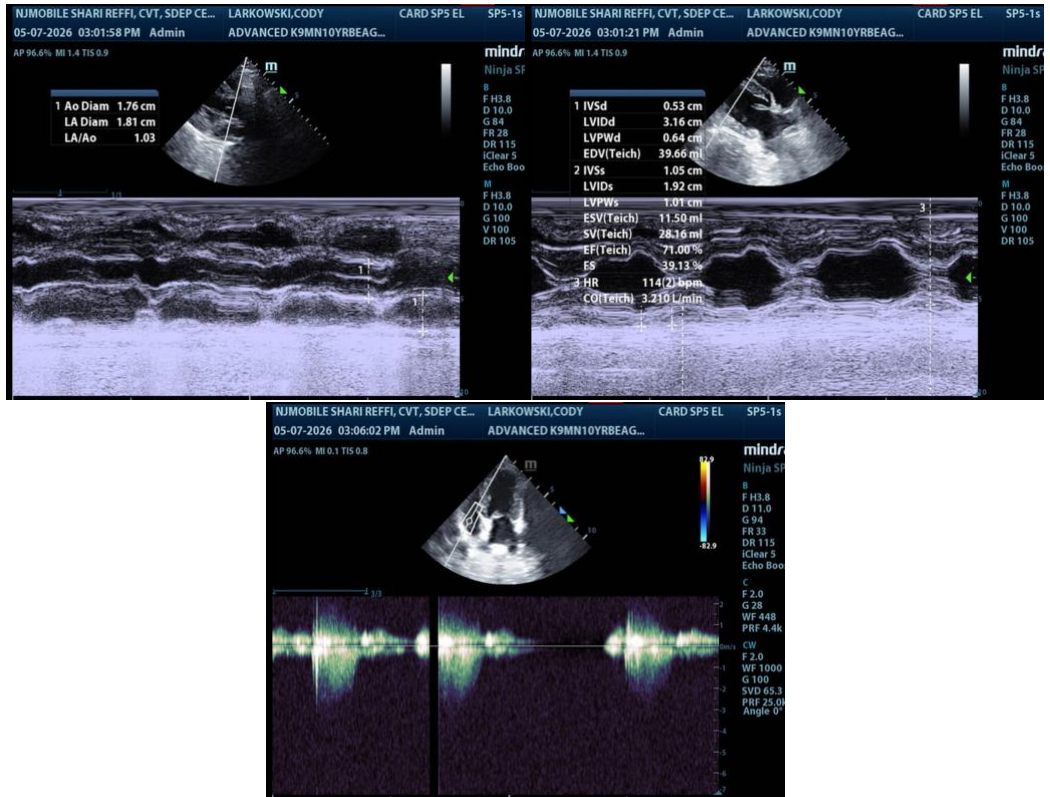
Dr. Voigt

INVOICE

15912

DATE

05/07/26



The information and recommendations provided are based on the images presented by the referring veterinarian/sonographer. No evaluation can be communicated regarding pathology that was not visible in the image/video clips provided.

Thank you for this referral. If the clinical or image interpretation does not parallel your findings or if I can be of any further assistance, please contact me.

Eric Lindquist, DMV, DABVP(CFM), Cert. IVUSS,

CEO, Owner, Founder -- SonoPath.com

info@SonoPath.com