



## PATIENT

Bella Schaberg

## SPECIES

Canine

## BREED

Bichon Frise Mix

## SEX

Spayed Female

## AGE

13 Years

## WEIGHT

20 Pounds

## INTERPRETED BY

Eric Lindquist, DMV,  
DABVP (CFM), Cert.  
IVUSS

## IMAGING PERFORMED BY

Dr. Julia Wiederholt

## HOSPITAL NAME

Dreaming Summit AH

## REFERRING VET

Dr. Julia Wiederholt

## INVOICE

35994

## DATE

5/7/26

## PRESENTING CLINICAL SIGNS

History: 3+ month history of progressive hematuria and stranguria. Labwork and urine culture run in February at start of symptoms unremarkable for her age, culture negative. Now lethargic.

Abnormal PE/Chem/CBC/UA Results: 2/2026: cbc unremarkable, chem mild ALP elevation, UA marked hematuria and proteinuria, culture negative 2/2026: abdominal radiographs showed mild hepatomegaly, no radiopaque urinary bladder stones or nephroliths.

## LIMITED ULTRASONOGRAPHIC EXAMINATION

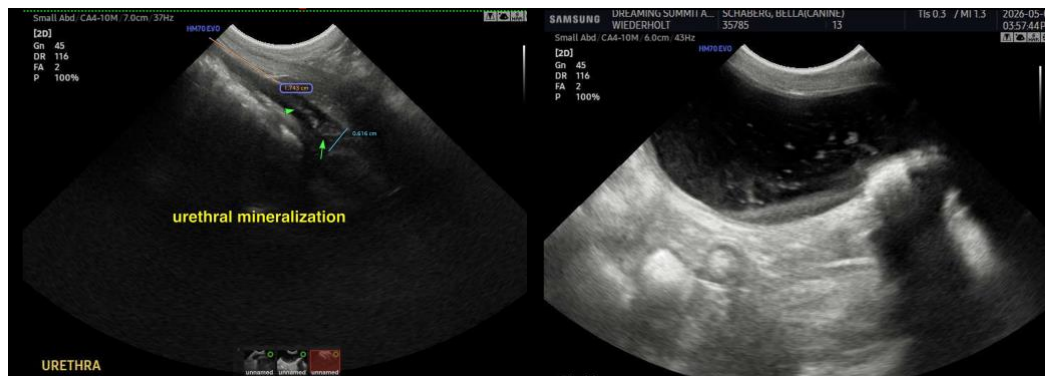A minor amount of sand/mucus accumulation was noted in the urinary bladder, measuring approximately 1.0 cm at the apex with suspended and dependent debris. The urethra revealed mineralization in the deep pelvic urethra, strong concern for carcinoma. The mineralization was irregular, suggestive for dystrophic mineralization. Maximum width of the tissue density was 0.6 cm and initiated approximately 2.0 cm from the cystourethral junction. The bladder wall itself was unremarkable. A trace amount of free fluid was noted around the bladder; this may be owing to overdistention.

## ULTRASONOGRAPHIC FINDINGS

- Urethral mineralization- strong concern for carcinoma
- Dependent bladder debris and coalesced sand

## INTERPRETATION OF THE FINDINGS & FURTHER RECOMMENDATIONS

Cystoscopy would be ideal in this patient. BRAF testing is indicated. Cytospin of a free catch urine sample is warranted. Prognosis is guarded. Strong concern for urethral tumor/carcinoma. Oncological referral or stent placement, chemotherapeutic intervention, and ultrasound guided laser ablation are all options.





## PATIENT

Bella Schaberg

## SPECIES

Canine

## BREED

Bichon Frise Mix

## SEX

Spayed Female

## AGE

13 Years

## WEIGHT

20 Pounds

## INTERPRETED BY

Eric Lindquist, DMV,  
DABVP (CFM), Cert.  
IVUSS

## IMAGING PERFORMED BY

Dr. Julia Wiederholt

## HOSPITAL NAME

Dreaming Summit AH

## REFERRING VET

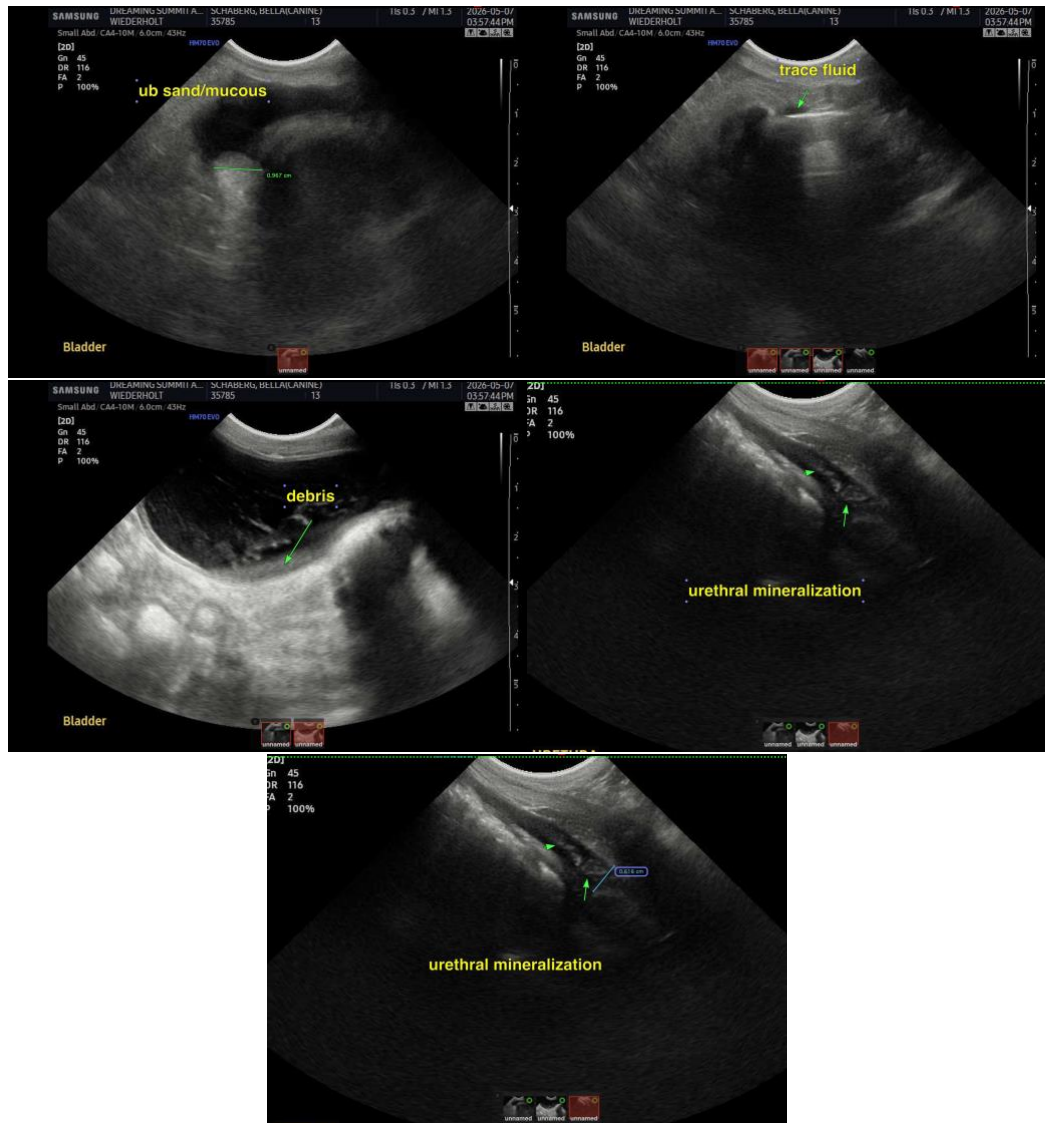
Dr. Julia Wiederholt

## INVOICE

35994

## DATE

5/7/26



The information and recommendations provided are based on the images presented by the referring veterinarian/sonographer. No evaluation can be communicated regarding pathology that was not visible in the image/video clips provided.

Thank you for this referral. If the clinical or image interpretation does not parallel your findings or if I can be of any further assistance please contact me.

Eric Lindquist, DMV, DABVP(CFM), Cert. IVUSS,  
CEO, Owner, Founder -- SonoPath.com  
[info@SonoPath.com](mailto:info@SonoPath.com)