



PATIENT

Bear Bruha

SPECIES

Canine

BREED

German Shepherd

SEX

Neutered Male

AGE

11 Years

WEIGHT

95.6 lbs

INTERPRETED BY

Eric Lindquist, DMV,
DABVP(CFM), Cert.
IVUSS

IMAGING PERFORMED BY

Dr. Raul Casas

HOSPITAL NAME

State Avenue Vet
Clinic

REFERRING VET

Dr. Raul Casas

INVOICE

15889

DATE

05/07/26

PRESENTING CLINICAL SIGNS

Presents for bladder ultrasound due to hematuria noted for 2.5 weeks: initial urine with clots, bright red; progressed to brown/cranberry, now dark orange. No pollakiuria, stranguria, or dysuria reported. Normal appetite, water intake, urination, and defecation. No vomiting or diarrhea. No known toxin exposure; no recent duck medication; history of eating duck feces. Not on medications; receiving joint supplement

OU: lenticular sclerosis, OD: few gray opacities on cornea, worn teeth, abdomen: tense during palpation; no pain Urinalysis: dark red, opaque urine, Blood / Hemoglobin 250 Ery/ μ L, Leukocyte Esterase 100 Leu/ μ L, Creatinine 1.5 CBC wnl, pending abdominal rads

LIMITED ULTRASONOGRAPHIC EXAMINATION

Urinary System

The **urinary bladder** presented with a moderate amount of debris. Catheter placement was evident.

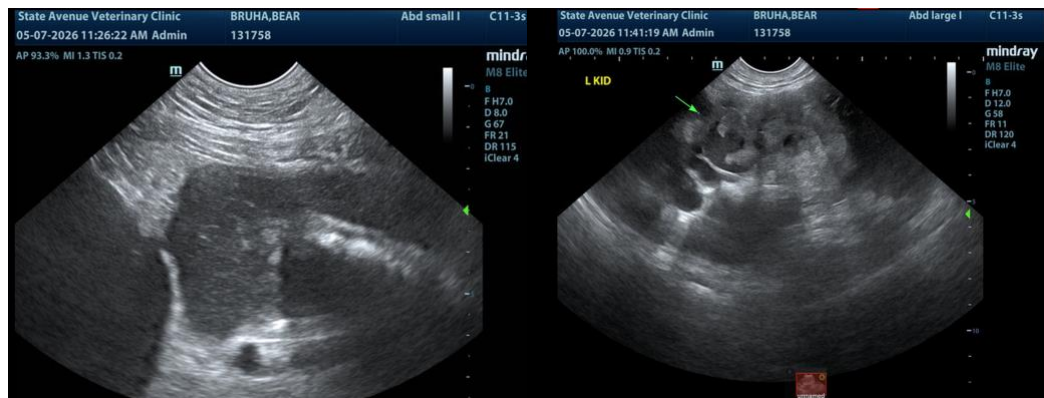
The **kidneys** presented with moderate/severe polycystic changes and severe renomegaly measuring 10.0+ cm in length bilaterally. Disruption of architecture was evident. The cysts were echogenic, irregular and variably sized. This presentation is most consistent with polycystic kidney disease with potential concurrent UTI, however, hemangiosarcoma is a strong potential. The right kidney presented with moderate changes while the left kidney presented with severe changes.

ULTRASONOGRAPHIC FINDINGS

- Urinary bladder debris.
- Severe renomegaly- strong potential for renal hemangiosarcoma.

INTERPRETATION OF THE FINDINGS & FURTHER RECOMMENDATIONS

Ultrasound guided FNA of the parenchymal portions of the left kidney is recommended for further definition. Prognosis is guarded. Full abdominal sonogram is recommended.





PATIENT

Bear Bruha

SPECIES

Canine

BREED

German Shepherd

SEX

Neutered Male

AGE

11 Years

WEIGHT

95.6 lbs

INTERPRETED BY

Eric Lindquist, DMV,
DABVP(CFM), Cert.
IVUSS

IMAGING PERFORMED BY

Dr. Raul Casas

HOSPITAL NAME

State Avenue Vet
Clinic

REFERRING VET

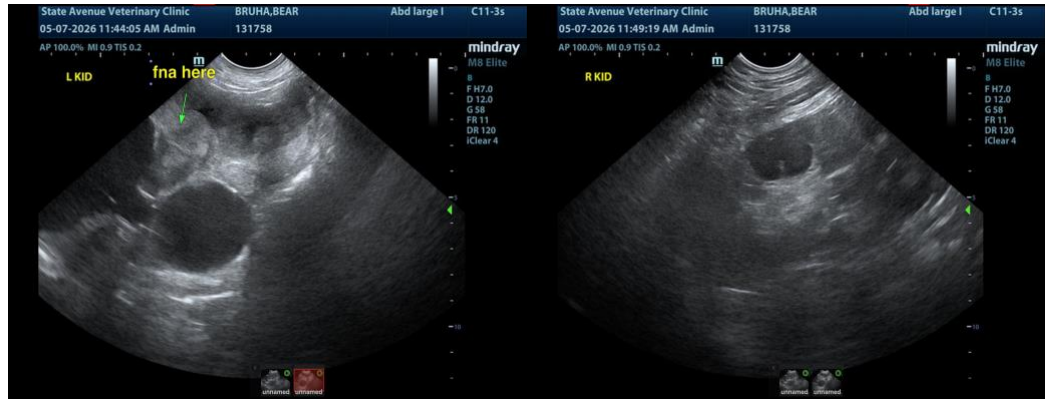
Dr. Raul Casas

INVOICE

15889

DATE

05/07/26



The information and recommendations provided are based on the images presented by the referring veterinarian/sonographer. No evaluation can be communicated regarding pathology that was not visible in the image/video clips provided.

Thank you for this referral. If the clinical or image interpretation does not parallel your findings or if I can be of any further assistance, please contact me.

Eric Lindquist, DMV, DABVP(CFM), Cert. IVUSS,

CEO, Owner, Founder -- SonoPath.com

info@SonoPath.com