



PATIENT

Alistair AID

SPECIES

Feline

BREED

DSH

SEX

Neutered Male

AGE

12.11

WEIGHT

22.06

INTERPRETED BY

Eric Lindquist, DMV,
DABVP (Canine &
Feline), Cert. IVUSS

IMAGING PERFORMED BY

Dr. Renee Ziegler Post

HOSPITAL NAME

For Cats Only VC

REFERRING VET

Dr. Renee Ziegler Post

INVOICE

35989

DATE

5/7/26

PRESENTING CLINICAL SIGNS

History of Hypertrophic cardiomyopathy and newly on Felicyn. Thorax radiographs also were sent for review.

ULTRASONOGRAPHIC EXAMINATION OF THE HEART

FELINE CARDIAC PARAMETERS	BODY WEIGHT (lbs)	HR (BPM)	IVSd (cm)	LVIDd (cm)	LVWd (cm)	FS (%)	EF (%)
NORMAL PARAMETER	-----	150-240	0.3-0.6	1.0-2.1	0.25-0.6	35-67	80-100
PATIENT	12.11	180	0.73	1.26	0.64	55	89
FELINE CARDIAC PARAMETERS	LA/AO (M-mode)	LA/AO HEART BASE (Sisson)	LAD LA MAX 4 Chamber		LVOT VEL. (m/s)	RVOT VEL. (m/s)	IVRT (m/)
NORMAL PARAMETER	<1.5	1.6	0.7-1.7		<1.6	<1.3	40-60
PATIENT	--	1.2	1.3		--	--	NM
Adapted from June Boon, Veterinary Echocardiography, 1998 Sisson D et al. JVIM 1991; 5: 232, Jacobs et al. Am J Vet Res 1985; 46:1705							

EPSS: 0.1

Cardiac Presentation

The echocardiogram in this patient demonstrated normal **left atrial** size based on 3 separate LA measurements. The cranial and caudal **mitral** valve leaflets presented normal linear structure and kinetics. The **left ventricle** presented minor septal and free wall hypertrophy, normal internal volumes and adequate contractility. The **left ventricular outflow** tract demonstrated normal laminar flow and subjective structural integrity. The **right atrium** and auricle revealed normal size, structure and content. No evidence of masses was noted or chamber overload. **Tricuspid** valvular assessment demonstrated adequate linear morphology and kinetics. The **right ventricle** was of normal size (1/3 diameter of LV), chordae structure, myocardial echogenicity and thickness. **Pulmonic** tract assessment revealed normal valve structure, laminar flow, and diameter (approx.1:1 pa/ao ratio). No visible **pericardial** or free pleura fluid was noted or extra cardiac pathology in the visible planes. The cranial **mediastinum and pericardial regions** were free of masses in the visible window.

ULTRASONOGRAPHIC FINDINGS

- Minor left ventricular hypertrophy/hypertrophic cardiomyopathy phenotype. This is well compensated.

INTERPRETATION OF THE FINDINGS & FURTHER RECOMMENDATIONS



PATIENT

No specific therapy is warranted at this time.

Alistair AID

SPECIES

Feline

BREED

DSH

SEX

Neutered Male

AGE

12.11

WEIGHT

22.06

INTERPRETED BY

Eric Lindquist, DMV,
DABVP (Canine &
Feline), Cert. IVUSS

**IMAGING
PERFORMED BY**

Dr. Renee Ziegler Post

HOSPITAL NAME

For Cats Only VC

REFERRING VET

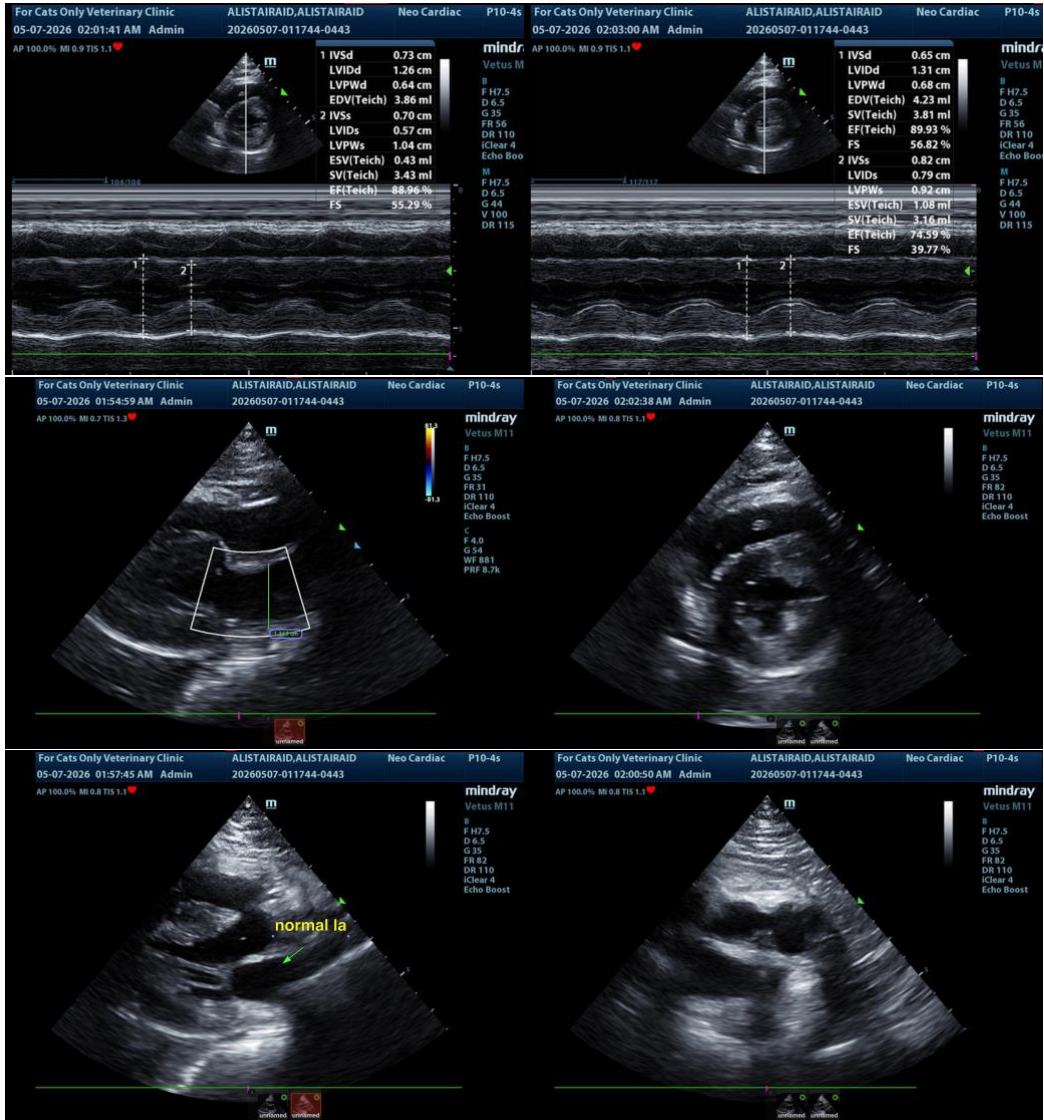
Dr. Renee Ziegler Post

INVOICE

35989

DATE

5/7/26



The information and recommendations provided are based on the images presented by the referring veterinarian/sonographer. No evaluation can be communicated regarding pathology that was not visible in the image/video clips provided.

Thank you for this referral. If the clinical or image interpretation does not parallel your findings or if I can be of any further assistance please contact me.

Eric Lindquist, DMV, DABVP(CFM), Cert. IVUSS,
CEO, Owner, Founder -- SonoPath.com
info@SonoPath.com



PATIENT

Alistair AID

SPECIES

Feline

BREED

DSH

SEX

Neutered Male

AGE

12.11

WEIGHT

22.06

INTERPRETED BY

Eric Lindquist, DMV,
DABVP (Canine &
Feline), Cert. IVUSS

IMAGING PERFORMED BY

Dr. Renee Ziegler Post

HOSPITAL NAME

For Cats Only VC

REFERRING VET

Dr. Renee Ziegler Post

INVOICE

35989

DATE

5/7/26